

# ***HINDGUT ACIDOSIS IN HORSE AT CHITTAGONG ZOO - A CASE REPORT***



.....  
Signature of Author

**Raj Shakhar Datta.**

Roll No.: 16/09

Intern id: 09

Registration No.: 01615

Session: 2015-2016

***Faculty of Veterinary Medicine  
Chattogram Veterinary and Animal Sciences University  
Khulshi, Chittagong-4225, Bangladesh***

# ***HINDGUT ACIDOSIS IN HORSE AT CHITTAGONG ZOO - A CASE REPORT***



.....  
Signature of Supervisor

**Dr. Bhajan Chandra Das**

**Professor**

Department of Medicine and Surgery

Faculty of Veterinary Medicine

**Director**

Directorate of Veterinary Clinics

***Faculty of Veterinary Medicine  
Chattogram Veterinary and Animal Sciences University  
Khulshi, Chittagong-4225, Bangladesh***

# Table of Contents

List of figure: .....	4
List of table: .....	4
ABSTRACT.....	5
1.INTRODUCTION .....	6
2.MATERIALS AND METHODS.....	8
2.1 Study area and duration of time: .....	8
2.2 Animal used for study: .....	8
2.3 Clinical history: .....	8
2.4 Clinical findings: .....	8
2.5 Diagnosis:.....	9
2.6 Treatment: .....	9
2.7 Advice: .....	9
3.RESULT .....	11
4.DISCUSSION .....	12
5.CONCLUSION:.....	13
REFERENCES .....	13
ACKNOWLEDGEMENT .....	16

### List of figure:

Figure	Title	Page
Figure: 1	Left lateral recumbency of horse	8
Figure: 2	Swelling of the right pastern joint	8
Figure: 3	Covering the head of horse	10
Figure: 4	Slinging by rope and jute bag	10
Figure: 5	Offering gourd	10
Figure :6	After treatment animal start grazing	10

### List of table:

Table	Title	Page
Table:1	Drug used in this study	9

## **ABSTRACT**

Hindgut acidosis is a condition that occurs when animal ingest more carbohydrate. This study deals with a hindgut acidosis case of horse which is found in Chittagong Zoo, Foyslake. The patient of hindgut acidosis diagnosed though history of ingestion more concentrate feed and various signs like: lateral recumbency, laminitis, colic, loss of appetite, lameness, dull, depressed. The case was corrected with some drugs. Sodium bi-carbonate (0.1gm/kg) was given for 5 days for nutriling the pH. Flunixinmeglumine (1ml/45 kg) suggested I/M for 3 days. Prebiotic and probiotic for increasing microbial population in cecum. Concentration feed stopped until cure. For supporting the animal, sling was provided. After 5 days the animal was fully recovered.

---

Keywords: Hindgut acidosis, carbohydrate, laminitis, sodium bi-carbonate, flunixinmeglumine, prebiotic, probiotic, sling

# CHAPTER: 1

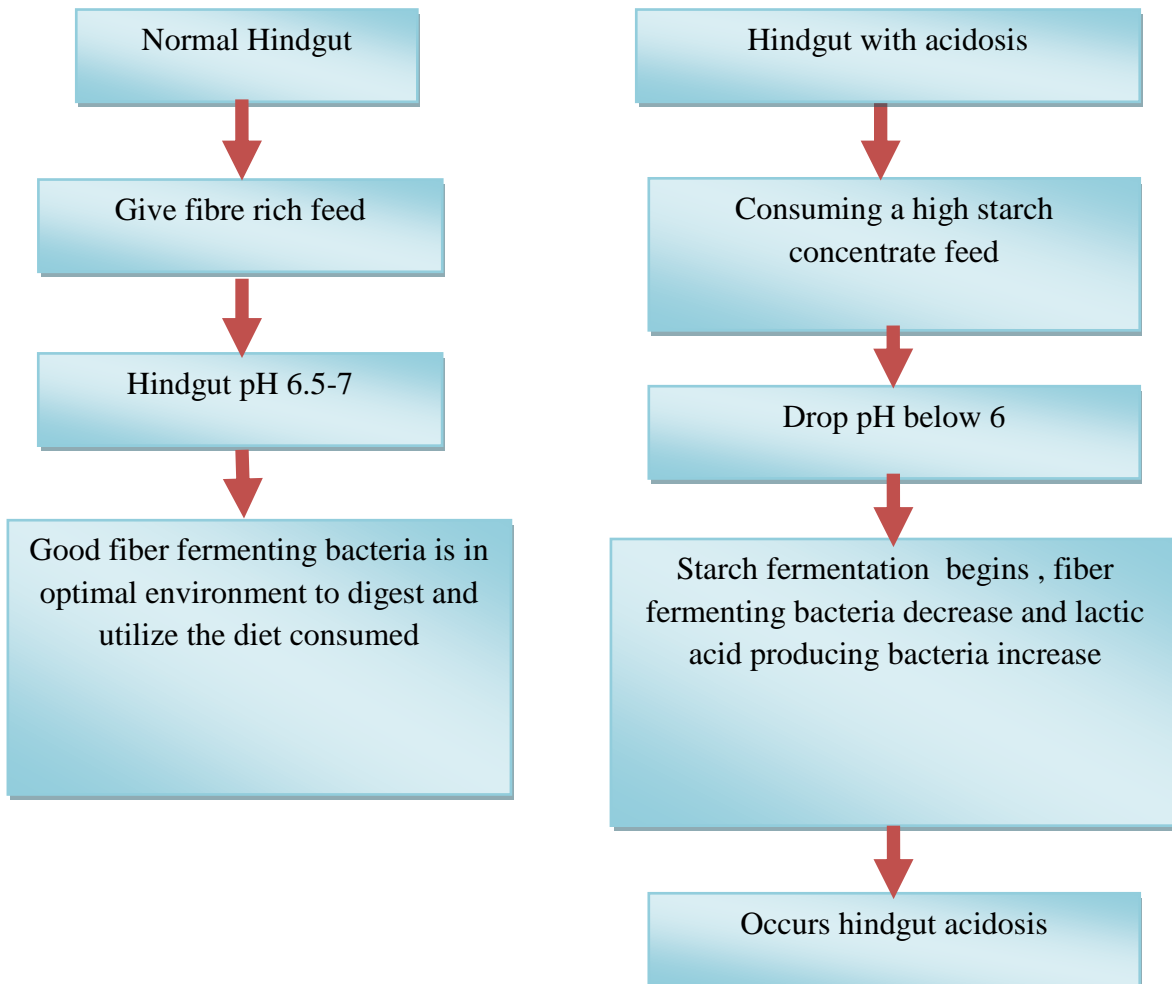
## INTRODUCTION

Hindgut acidosis is an excessive acidity in the horse's hindgut, a drastic drop of the pH value, most commonly caused by a high grain and low forage diet. Horse gastrointestinal tract can be broken down into two main sections: the foregut and the hindgut (Dicks *et al.*, 2014). The foregut is composed of the mouth, esophagus, stomach, and small intestine. It makes up 30% of the overall digestive tract. The small intestine absorbs simple sugars, starches, and amino acids. However, it does not have the ability to break down fibre which makes up a large portion of a horse's diet (David, 2010).

Fibre fermentation occurs in the hindgut. The hindgut consists of the cecum and colon and makes up approximately 60% of the digestive tract. Healthy hindgut function is critical for a horse to absorb and utilize the nutrients found in the diet to meet daily requirements (Rowe *et al.*, 1995). The hindgut contains a complex ecosystem of bacteria, yeast, and other microorganisms that break down fibre in the diet through fermentation. The hindgut needs to maintain a relatively stable pH balance to support optimal digestion and nutrient absorption. If the hindgut environment becomes too acidic or too basic, it can interfere with the proper functioning of the beneficial bacterial species that populate the gut. The ideal pH level in the hindgut for proper digestion is between 6.5–7.0 (Destrez *et al.*, 2015). Low pH is associated with excessive sugar or starch in the equine diets. This causes fibre digesting bacteria to die off and release toxins that can damage the cells of the hindgut and cause inflammatory responses, ulcers, and laminitis (Davies *et al.*, 2021).

Horse shows several signs including: lateral recumbency, laminitis, mild signs of colic (abdominal discomfort, laying down, restlessness), lameness, new stereotypic behavior (such as cribbing, pacing, pawing), loss of appetite, weight loss, reduced growth rate, reduced reproductive function, joint inflammation

In hindgut acidosis the animal is diagnosed by clinical history, clinical sign, clinical findings. After diagnosis the patient is treated by sodium bi-carbonate (Hodgson *et al.*, 1994.), flunixinmeoglumine (Goetz, 1989), probiotic, prebiotic (Kritas and S.K, 2017) and electrolyte.



### **Mechanism of hindgut acidosis**

## CHAPTER: 2

### MATERIALS AND METHODS

**2.1 Study area and duration of time:** The study was conducted over 5 days of time starting from 20 September, 2021 to 27 September 2021 at Chottogram Zoo, Fayslake, Chottogram.

**2.2 Animal used for study:** A Bangladeshi native horse (age: 2.5 year, sex: male, body weight: 150 kg) affected with hindgut acidosis.

**2.3 Clinical history:** 2 horses reared in one cage. The caretaker offered concentrate both horse. One horse ingest low amount concentrate and another ingest more amount of concentrate.

**2.4 Clinical findings:**

Through inspection: Animal was in left lateral recumbency ( figure: 1). Animal did not take food. The horse showed stereotypic behavior (such as cribbing, pacing, pawing)

Though palpation: Abnormalities present in right hind limb. Here, obseved right pastern joint was swollen then normal (figure:2). The animal was also dehydrated. The stomach was larger then normal.

Temperature: 99°F



**Figure 1: Left lateral recumbency**

**Figure 2: Swelling of the right pastern joint**



**2.5 Diagnosis:** On the basis of clinical findings and clinical sign we diagnosed the horse was suffered from hindgut acidosis. The following treatment was undertaken for hindgut acidosis.

**2.6 Treatment:**


**Table 1 : Drug used in this study**

SL no	Generic name	Trade name	Dose	Route
1	Sodium bi-carbonate	Baking Soda	0.1gm/kg	15 gm orally for 3 days
2	Probiotics And Prebiotics	Pulv. Biogut vet	1 sachet/ animal/ day	1 sachet BID orally for 5 days
3	Flunixin meglumine	Inj. Flumixine	1ml/45 kg	3.5 ml, I/M, SID, for 5 days
4	Electrolyte	Pulv. Electromin	2gm/2 liter water	2gm/ 2 liter water, orally for 5 days


**2.6.1 Slings the animal:** It is important to maintain the standing position of horse. Because if animal lying down for long time, it may die. At first cover the head with a bag for preventing horse bite (figure: 3). Here, the animal mechanically standing up by slinging (figure:4).

**2.7 Advice:**

The concentrate feed stopped for few days. Then offers the animal fiber rich feed. Here, gourd offered to the animal (figure:5).



**Figure 3 :Covering the head of horse**



**Figure 4 :Covering the head of horse**



**Figure 5: Offering gourd**

## CHAPTER: 3

### RESULT

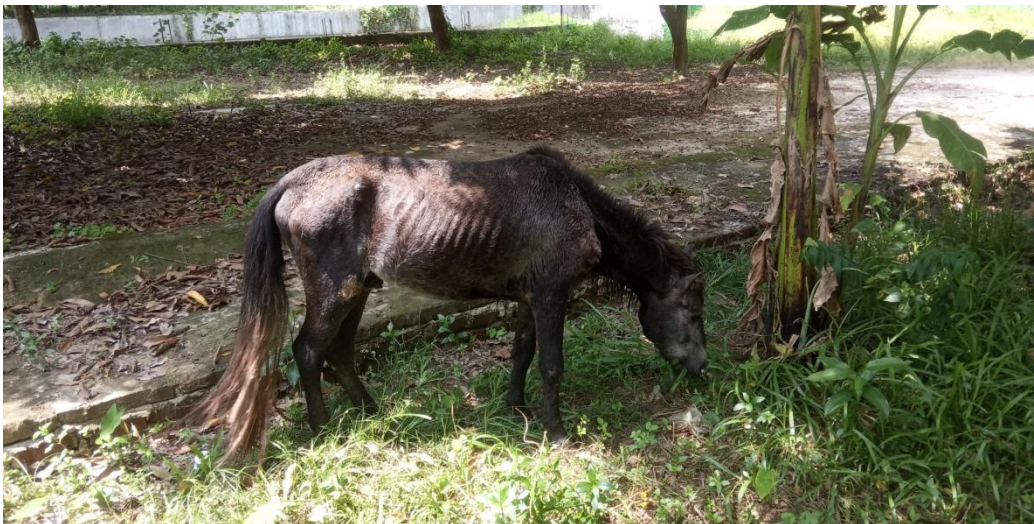After one day animal started to show normal behavior. It started defecation.

After 2<sup>nd</sup> day the horse started to take food.

After 3<sup>rd</sup> day gait and posture was normal

After 4<sup>th</sup> day animal started to balance itself.

Within 5 days animal started to graze (figure:6) and fully cured by this treatment.



**Figure 6 : After treatment animal start grazing**

## CHAPTER: 4

### DISCUSSION

Sodium bicarbonate decreases volatile fatty acid and lactic acid production. Pre- and probiotics are considered “functional ingredients” that are added to horse feed to provide benefits to horse. The environment of the intestine contains naturally occurring beneficial microorganisms commonly called ‘bugs’. Gut bugs are found in all species, including humans, and are essential to the digestion process. For the horse, gut bugs work to break down components of forage and feed as they pass through the digestive tract. The bugs deconstruct complex molecules within feedstuffs, which releases nutrients and allows the synthesis of energy substrates and important vitamins. Those nutrients are then absorbed through the intestines into the bloodstream, where they become available to cells in the body to support basic maintenance, growth and activity.

Because laminitis usually develops as a sequela to a disease process in a part of the body other than the foot, the treatment of horses 'prone to laminitis' . In recent years, flunixin meglumine , acepromazine and cold water hydrotherapy were added in most cases to the treatment of the primary disease in these horses. After the publications by Pollitt (Pollitt and Davies, 1998) the author feel hesitate about using acepromazine . Many of the horses 'prone to laminitis' fortunately do not get the disease, and the ones showing the acute phase have a large variety of primary diseases. So that in this case, applied flunixinmeglumine.

In Hindgut acidosis cases need to change management of the horse shed. That’s why we stopped the concentrate until the horse cured. It helps to stop producing more acid in hindgut. The patient was provided fiber rich feed until fully cured. After changing food habit animal started to response with the treatment.

Lateral recumbency is harmful and life threatening. Complications often arise following a period of extended recumbency; of particular concern are the musculoskeletal, pulmonary, urinary, and GI systems . So the horse needed to give support by slinging. In this case, used a plastic bag on the head for preventing horse bite (figure:3). After slinging (figure:4) animal became normal and could balance itself within 4 days.

Virginiamycin is a feed additive help to control hindgut acidosis. Virginiamycin is effective in controlling the pattern of acid build up and accumulation of lactic acid even in horses given high levels of grain. The control of acidic conditions in the hindgut reduces the risk of laminitis associated with grain-based diets and prevents some of the behavioural changes associated with feeding grain supplements to horses (Rowe *et al.*,1995). This feed additive is not available in our country.

## **CHAPTER: 5**

### **CONCLUSION**

Hindgut acidosis is common problem in horse. The patient in this study, treated with sodium bicarbonate (0.1gm/kg), flunixin meglumine (1ml/45 kg), prebiotic, probiotic, and electrolyte. Within 5 days the outcome of the treatment was good . In field condition for hindgut acidosis can use this treatment.

## REFERENCES

- David Frape. (2010). *Equine Nutrition and Feeding*, Wiley-Blackwell. , pp.514
- Davies, J., Thomas, C., Rizwan, M. and Gwenin, C. (2021). Development of Electrochemical DNA Biosensor for Equine Hindgut Acidosis Detection. *Sensors*, 21(7), p.2319..
- Destrez, A., Grimm, P., Cézilly, F. and Julliand, V. (2015). Changes of the hindgut microbiota due to high-starch diet can be associated with behavioral stress response in horses. *Physiology & behavior*, 149, pp.159-164.
- Dicks, L.M.T., Botha, M., Dicks, E. and Botes, M. (2014). The equine gastro-intestinal tract: an overview of the microbiota, disease and treatment. *Livestock science*, 160, pp.69-81.
- Dr. Patricia Evans, Scott McKendrick. (March 2010). *Equine Nutrition: Concentrates*.
- Hodgson, DR, Rose RJ. (1914). *The athletic horse*. Philadelphia: Saunders.
- <https://madbarn.com/hindgut-acidosis-in-horses/>
- Kathy P, Anderson V. ( November 2007). *Basics of feeding horses: feeding management*.
- Kritas, S.K. (2018). Probiotics and prebiotics for the health of pigs and horses. In *Probiotics and prebiotics in animal health and food safety* (pp. 109-126). Springer, Cham.
- Lecchi, C.; Costa, E.D.; Lebelt, D.; Ferrante, V.; Canali, E.; Ceciliani, F.; Stucke, D.; Minero, M. (2018). Circulating miR-23b-3p, miR-145-5p and miR-200b-3p are potential biomarkers to monitor acute pain associated with laminitis in horses. *Animal* , 12, 366–375.
- Milinovich, G.J.; Trott, D.J.; Burrell, P.C.; Croser, E.L.; al Jassim, R.A.M.; Morton, J.M.; van Eps, A.W.; Pollitt, C.C. (2007). Fluorescence in situ hybridization analysis of hindgut bacteria associated with the development of equine laminitis. *Environ. Microbiol*,9, 2090–2100.
- Milinovich, G.J.; Trott, D.J.; Burrell, P.C.; van Eps, A.W.; Thoefner, M.B.;Blackall, L.L., Jassim, R.A.M.; Morton, J.M.; Pollitt, C.C. (2006). Changes in equine hindgut bacterial populations during oligofructose-induced laminitis. *Environ. Microbiol*, 8, 885–898.

- Nocek, J.E. (1997). Bovine acidosis: Implications on laminitis. *Journal of dairy science*, 80(5), pp.1005-1028.
- Pagan, J.D., Lawrence, T.J. and Lawrence, L.A. (2010). Feeding protected sodium bicarbonate attenuates hindgut acidosis in horses fed a high-grain ration. *The impact of nutrition on the health and welfare of horses*, (128), pp.19-22.
- Pollitt CC, and Daradka M. (1998). Equine laminitis basement membrane pathology: loss of type IV collagen, type VII collagen and laminin immunostaining. *Equine Vet J* suppl, 27: 139-44.
- Pollitt CC, and Davies CL. (1998). Equine laminitis: its development post alimentary carbohydrate overload coincides with increased sublamellar blood flow. *Equine Vet J Suppl* , 27: 125-32. 42.
- Richards, N., Hinch, G.N. and Rowe, J.B. (2006). The effect of current grain feeding practices on hindgut starch fermentation and acidosis in the Australian racing Thoroughbred. *Australian veterinary journal*, 84(11), pp.402-407.
- Rowe, J.B., Pethick, D.W. and Johnson, K.G. (1995). Controlling acidosis in the equine hindgut. *Recent advances in animal nutrition in Australia*, 10, pp.136-143.
- Rush, B.R., Davis, E.G. and McCue, M. (2004). Equine recumbency: complications and slinging. *Compendium on Continuing Education for the Practicing Veterinarian*, 26(4), pp.256-266.
- Sloet van Oldruitenborgh- Oosterbaan, M.M. (1999). Laminitis in the horse: a review. *Veterinary quarterly*, 21(4), pp.121-127.
- Thirumalaisamy, G., Parkunan, T., Senthilkumar, S. and Kumar, D., Hindgut Fermentation In Horses. *Indigenous Goat Breeds*, p.77.

## **ACKNOWLEDGEMENT**

I would like to express the deepest sense of gratitude with all sorts of praises to the Almighty God, whose blessings enabled me to complete these clinical reports successfully.

I am humbly thankful to my honorable supervisor teacher Dr. Bhajan Chandra Das (Professor of Department of Medicine and Surgery Faculty of Veterinary Medicine, Director of Veterinary Clinics). For his valuable advice, technical support, leadership direction, and dedication to provide me the study initiatives, I am really thankful to him. I could not have imagined having a better advisor and mentor for my report.

I am also thankful to Dr. Md Sahadat Hossain Suvo (Curator of Chittagong Zoo) for helping me in this study.

I would respectfully acknowledge to my report committee: Dean Prof. Dr. Mohammad Alamgir Hossain and Prof. Dr. A K M Saifuddin, for their insightful comments and encouragement, but also for the hard question which incited me to widen my research from various perspectives.

Last but not the least; I would ever be thankful to all my well-wishers, family members for their inspiration.

The Author