

Correction of femoral fracture in a cat using retrograde intramedullary pinning: A case report



Submitted By:

Sheikh Asif Rayhan

Roll No: 15/66; Reg No: 01494

Intern ID: 61

Session: 2014-2015

A clinical report submitted in partial satisfaction of the requirements for the degree of Doctor of Veterinary Medicine (DVM)

Faculty of Veterinary Medicine
Chattogram Veterinary and Animal Sciences University
Khulshi, Chattogram-4225, Bangladesh

October 2021

Correction of femoral fracture in a cat using retrograde intramedullary pinning: A case report



Approved By:

Dr. Himel Barua

Professor

Department of Microbiology and Veterinary Public Health

Faculty of Veterinary Medicine

Chattogram Veterinary and Animal Sciences University

Khulshi, Chattogram-4225, Bangladesh

October 2021

Table of Contents

Contents	Page
List of figures	i
Abstract	i
Introduction	1
Case history	1
Restraining and anesthesia	2
Surgical technique	2
Postoperative care	6
Results	6
Discussion	6
Conclusion	7
References	7
Acknowledgement	8
Biography	8

List of Figures

Figure No.	Contents	Page
01	The cat with lameness and signs of pains	3
02	Pre-operative radiographs of the left hind limb showing the femoral fracture	3
03	Preparation of the patient; the site of surgery was covered by draper	3
04	Incision of the skin and fascia	3
05	Incision of the muscle	3
06	Detection of complete fracture	3
07	Intramedullary pinning	4
08	Close view of intra medullary pinning	4
09	Live in C-ARM machine view	4
10	After drilling the pin	4
11	After wiring the cracked bone	4
12	Wire cutting	4
13	Muscle suturing	5
14	Closing of the site of surgery	5
15	Pin cutting	5
16	Application of povidone iodine	5
17	Post-operative X-ray	5
18	Fixation after surgery	5
19	Bone remodeling after 3 months	5

Correction of femoral fracture in a cat using retrograde intramedullary pinning: A case report

Abstract

The purpose of the present case report was to describe a surgical approach for correction of femoral fracture in a cat. The case was recorded in the Teaching and Training Pet Hospital and Research Centre (TTPHRC), Purbachal, Dhaka during an internship placement. A nine-month-old mixed breed cat weighing 2.6 kg was presented to TTPHRC with a history of leg carrying lameness following an accident due to fall down from roof. On physical examination the cat was found active and alert. Palpation of the left femur revealed pain and crepitation while radiography confirmed a complete femoral fracture. The fracture was treated by retrograde intramedullary pinning along with wiring following standard surgical approach. General anaesthesia was given and maintained throughout the surgery. As a part of post-operative care systemic antibiotic, pain killer and nerve tonic were administered with protective bandages. Mild weight bearing was remarked on the 7th postoperative day and sutures were removed on 10th day after surgery. Bone healing occurred without complications and the cat was recovered three months after surgery bearing weight on the limb. The present case study suggests that intramedullary pinning with wires is very effective for treatment of femur fracture in cat.

Key words: C-arm, Femur fracture, Retrograde intramedullary pinning (IMP)

Introduction

Femoral fracture is one of the frequently encountered orthopedic problems in cats (Beale, 2004), and commonly occurs following different kinds of trauma (Braden et al., 1995). The shaft of the femur is the most common site of fracture. The main principle of fracture management is to return the anatomical position of two fracture fragments either by using closed or open fixation through surgery. Appropriate surgical approach, preservation of regional soft tissues, adequate stabilization and proper post-operative care are some of the important factors to be considered during the repair of femur fracture (Stiffler, 2004). The femur fractures in cat are readily diagnosed by palpation and radiography. Surgical intervention is indicated to reduce the fracture properly and to provide stability. Many fixation techniques have been developed in internal fracture fixation of pet animals. Internal fixation device mainly used in fracture treatment are intramedullary pin, plate, screw and wire (Mafi et al., 2014; Mwangi and Mande, 2012). A number of fixation methods are available for long bone fracture repair, each of which has advantages and disadvantages. Intramedullary pinning (IMP) is a popular method of long bone fracture repair in cat, often used to stabilize fracture of humerus, femur and tibia (Simon, 2016). This case report describes the clinical and radiographic examination of femoral fracture in a cat as well as successful reduction of the fracture using intramedullary pinning.

Case history

A nine-month-old mixed breed cat weighing 2.6 kg was admitted to the Teaching and Training Pet Hospital and Research Centre (TTPHRC), Purbachal, Dhaka with a history of injury in the left hind limb. The owner complained that the cat had leg carrying lameness after falling down from a roof two days ago. On presentation, the cat could not bear weight on the left hind limb. Signs of pain and crepitation were also noticed in the affected limb during palpation (Fig 01). Preoperative radiograph was taken to determine the location of the fracture. A proximal segmental fracture of the left femur was identified on radiographs (Fig 02). Based on the result of radiographic examination, it was decided to perform C-arm guided intramedullary pinning. Verbal consent from the owner was taken to perform the surgery. General condition of the patient was also noted before surgery.

Restraining and anesthesia

Both physical and chemical methods were used to restrain the cat. The cat was sedated with xylazine (1 mg/kg body weight) administered intramuscularly. For general anesthesia (GA), a mixture of diazepam-ketamine was given (0.3 mg/kg and 5.5mg/kg body weight, respectively) intravenously.

Surgical technique

The cat was placed in the right lateral recumbent position, and the surgical site was prepared aseptically by clipping, shaving, applying povidone iodine and finally washing with 70% alcohol. Then the site of surgery was covered by a draper (Fig 03). Along the skin of the affected area an incision was made, and skin was separated from subcutaneous layer (Fig 04). An incision was then made in the muscle, taking care to avoid larger blood vessels. After separation of the muscle by blunt dissection, the muscle layer was incised and then a cut was guided by a finger (Fig 05). Then the partial of the broken bone was removed and lifted with a bone curette by the help of Hohman retractor (Fig 06), and the bone was brought back to its normal position. Then drilling was done through the injured bone with bone drilling machine (Fig 07 and Fig 08). The surgery was performed by using 2.5 mm (Steinmann) pin by using C-ARM machine (Fig 09). After drilling the pin (Fig 10), 22 gauze stainless steel wire was used for cracking bone (Fig 11). After wiring the additional wire was cut (Fig 12). Then simple continuous suture by catgut was given in muscle. Subcutaneous tissue apposition was done by using catgut in a simple continuous pattern (Fig 13). The skin was apposed using silk by cross mattress suture (Fig 14). Then the pin was cut with pin cutter (Fig 15). Povidone iodine was given in the suture line (Fig 16). Post-operative radiograph was taken to confirm the position of the implant (Steinmann pin) (Fig 17). During surgery 5% dextrose in normal saline (200 ml) was administered intravenously. Then a bandage was applied in the affected leg to immobilize it (Fig 18).

Figures



Fig 01: The cat with lameness and signs of pains.

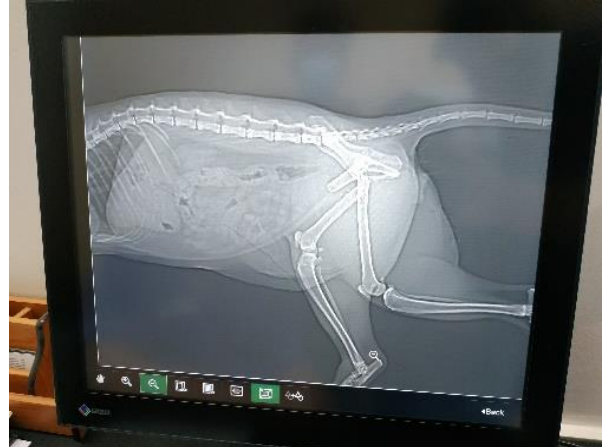

Fig 02: Pre-operative radiographs of the left hind limb showing the femoral fracture.

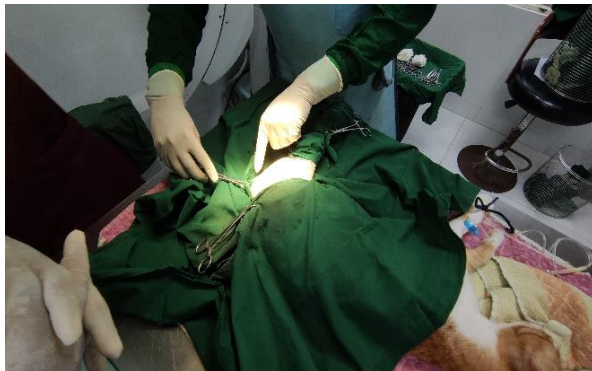

Fig 03: Preparation of the patient; the site of surgery was covered by draper.

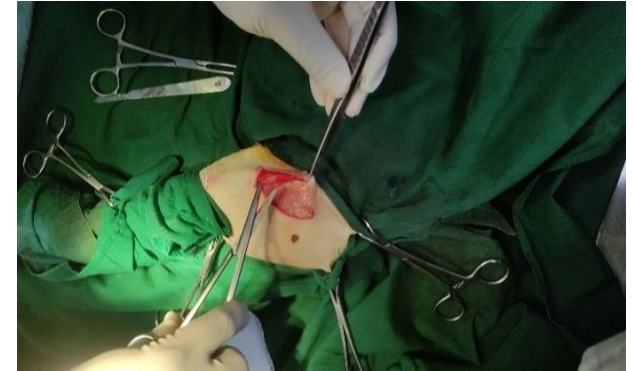

Fig 04: Incision of the skin and fascia.

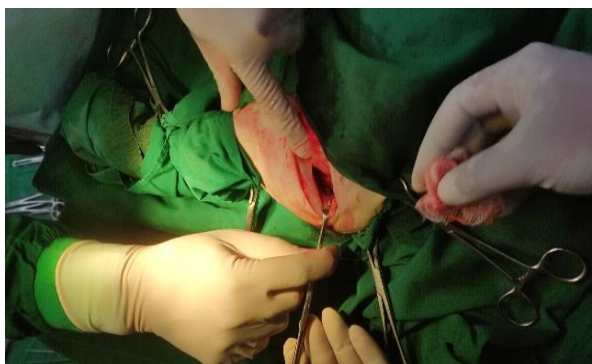

Fig 05: Incision of the muscle.

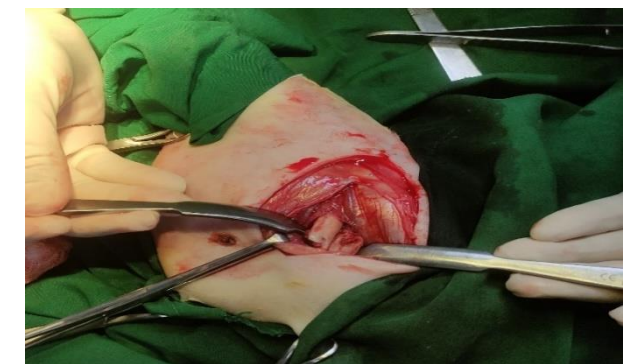

Fig 06: Detection of complete fracture.

Figures

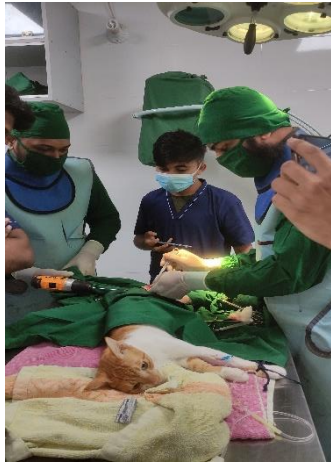

Fig 07: Intramedullary pinning

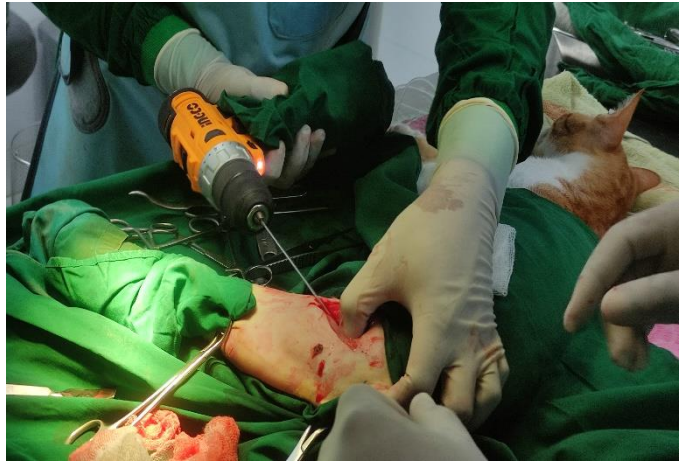

Fig 08: Close view of intra medullary pinning.




Fig 09: Live in C-ARM machine view.

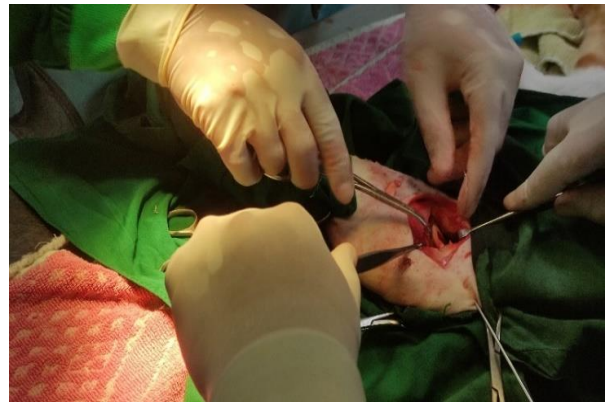

Fig 10: After drilling the pin

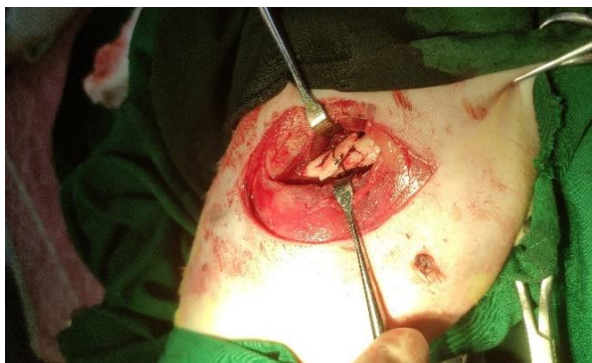

Fig 11: After wiring the cracked bone

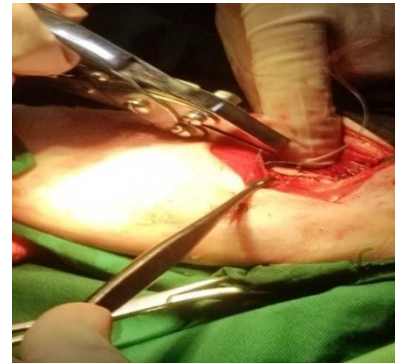

Fig 12: Wire cutting

Figures

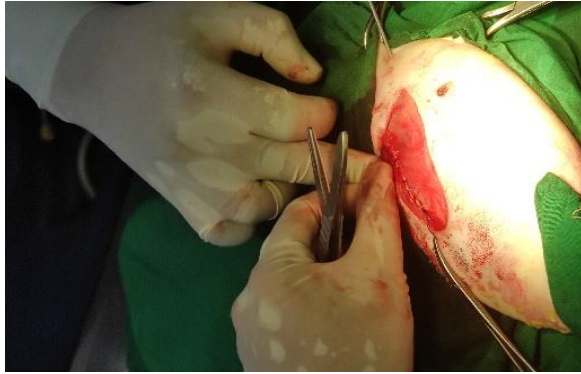


Fig 13: Muscle suturing

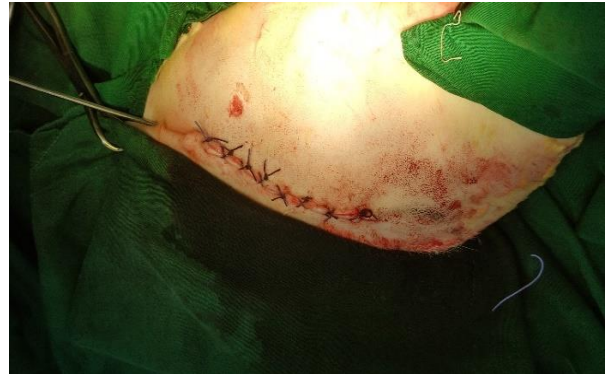

Fig 14: Closing of the site of surgery



Fig 15: Pin cutting

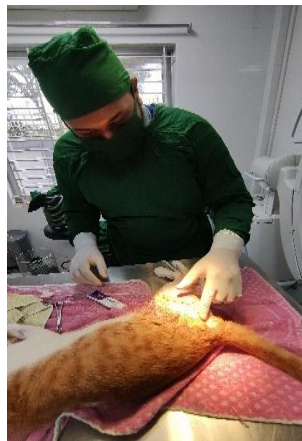

Fig 16: Application of povidone iodine

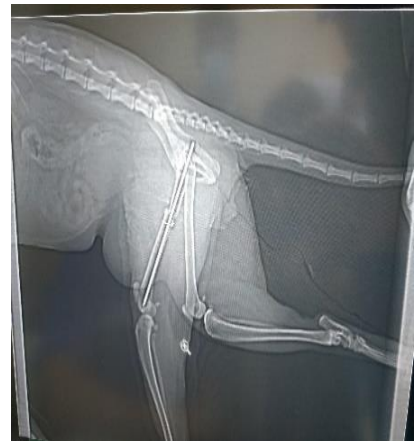

Fig 17: Post-operative X-ray




Fig 18: Fixation after surgery

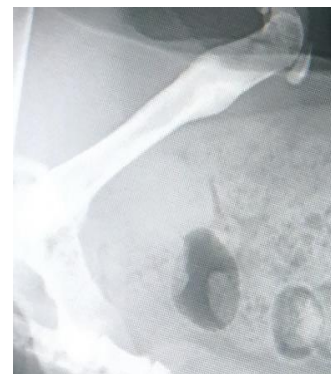

Fig 19: Bone remodeling after 3 months

Postoperative care

Postoperatively the cat was treated with systemic antibiotic, antihistaminic and pain killer, calcium supplement and nerve tonic with protective bandage and restricted movement for one week. Ceftriaxone 250 mg (50 mg/kg body weight) was administered intramuscularly for 7 days to prevent infection and 0.2 ml Meloxicam (0.04 mg/kg body weight) was given subcutaneously for 3 days to minimize inflammation. Calcium supplement (50 mg/kg body weight) and nerve tonic (1 ml/10 kg body weight) were also administered.

Results

Weight bearing was noticed on postoperative day 7. Surgical wound was also healed after 10 days of surgery and stitches were removed from the same day with no wound complication. After one month, the bone healing was noticed the bone was completely healed the pin was removed after three months (Fig19).

Discussion

Bone recovery can happen rapidly if there is no gap between two broken fragments. Standard method of fracture treatment via internal fixation by using intramedullary pins, wires, screws, and plates can attach two fracture fragments (Mafi et al., 2014; Stiffler, 2004). Intramedullary pin is an easily found internal fixation material and often used in fracture treatment, but when necessary it combined with wire in its use (Saglam and Kaya, 2004; Tercanlioglu and Sarierler, 2009). Pin loosening, pin migration and seroma formation are very usual complications in this IMP technique. Patient able to walk by foot on the ground since day 3-5 post surgery, while on day 15-29 post surgery patient was able to move most of its foot. Femur fracture recovery is preceded by fibroblast proliferation of periosteum and endosteum cell. Then osteoblast cells gradually turn into mature cell. Generally, an intramedullary pin should occupy 70-80 percent of the diameter of the medullary cavity (Peirone, 2002) Right pin selection is very important because of pin loosening and pin migration. Selection of appropriate pin depends on the size of the IMP cavity, the bone to be repaired. Pin diameters of 1.6 mm to 4.8 mm are suitable for use for most cat. Wire was also used to prevent movement force and bone weight (Simon, 2016; Harasen, 2004)

Conclusion

Intramedullary pin and combination of intramedullary pin and wire can be used as femoral fracture's internal fixation in cat by stabilizing the two fractures satisfactorily.

References

- Beale B. 2004. Orthopedic clinical techniques femur fracture repair. *Clinical Techniques in Small Animal Practice*, 19(3):134-150.
- Braden TD, Eicker SW, Abdinoor D, Prieur WD. 1995. Characteristics of 1000 femur fractures in the dog and cat. *Veterinary and Comparative Orthopedics and Traumatology*, 8(4):203-209.
- Harasen G. 2004. Atraumatic proximal femoral physeal fractures in cats. *The Canadian Veterinary Journal*, 45(4):359.
- Mafi R, Khan W, Mafi P, Hindocha S. 2014. Orthopedic approaches to proximal humeral fractures following trauma. *The Open Orthopedics Journal*. 8:437-441.
- Mwangi WE, Mande JD. 2012. Internal fixation of an oblique femoral fracture using cerclage wires and bone Plate. Case report of Magister. University of Nairobi, Kenya.
- Peirone B, Camuzzini D, Filippi D, Valazza A. 2002. Femoral and humeral fracture treatment with an intramedullary pin/external fixator tie-in configuration in growing dogs and cats. *Veterinary and Comparative Orthopaedics and Traumatology Archive*, 15(2):85-91.
- Saglam M, Kaya U. 2004. Treatment of proximal tibial fractures by cross pin fixation in dogs. *Turkish Journal of Veterinary and Animal Sciences*, 28:799-805.
- Simon MS, Gupta C, Sankar P, Ramprabhu R, Pazhanivel N. 2016. Repair of diaphyseal femoral fracture using intramedullary pin and cerclage wire in a cat. *Indian Veterinary Journal*, 93(2): 67-68.
- Stiffler KS. 2004. Internal fracture fixation. *Clinical Techniques in Small Animal Practice*, 19(3):105-113.
- Tercanlioglu H, Sarierler M. 2009. Femur fractures and treatment options in dogs which brought our clinics. *Lucrări Stiinifice Medicină Veterinară*, 13(2):98

Acknowledgement

The author is eternally grateful and indebted to the Almighty, without whose grace he would never have been able to successfully complete this production report.

This author also grateful to Dr. Himel Barua, Professor, Department of Microbiology and Veterinary Public Health FVM, CVASU, and expresses gratitude for his expert supervision, in the preparation of this report, as well as her expertise, perceptiveness, inspiring scholastic guidance and encouragement.

Professor Dr. Mohammad Alamgir Hossain, Dean of FVM, and Prof. Dr. AKM Saifuddin, Director of External Affairs, also deserve special thanks for their exceptional provision of this internship program.

Finally, the author extends his gratitude to his entire family, friends, and well-wishers for their kind assistance.

Biography

Sheikh Asif Rayhan was born on July 5, 1995. Son of Mst. Rebeka Khatun and S.M Abul Bashar. He was from Keshabpur, Jashore. He passed Secondary School Certificate (SSC) examination in 2011 from Keshabpur Govt. Pilot School and College followed by Higher Secondary Certificate (HSC) examination in 2013 from Govt. Keshabpur College. Now he is an intern veterinarian under the Faculty of Veterinary Medicine in Chittagong Veterinary and Animal Sciences University (CVASU). In future, he would like to work as a veterinary practitioner and do research on infectious diseases of large animals in Bangladesh.