

**A case report on successful surgical  
management of a large subcutaneous abscess  
in a bull in Ishurdi upazila, pabna,  
Bangladesh.**



A Clinical report presented in partial Fulfillment of the  
requirement for the degree of  
**Doctor of Veterinary Medicine**

**A Report  
submitted**

**By:**

**Md. Shaifur Rahman**

Roll No: 15/ 51;

Reg No: 01469; Intern ID: 47

Session: 2014 – 2015

**Faculty of Veterinary Medicine**

Chattogram Veterinary and Animal Sciences University

Khulshi, Chittagong-4225, Bangladesh

June, 2020

**A case report on successful surgical management  
of a large subcutaneous abscess in a bull in  
Ishurdi upazila, pabna, Bangladesh.**



A clinical report submitted as per approved style and content

.....  
**Signature of the Author**

**Md. Shaifur Rahman**

Intern Id: 47

Roll No: 15/51

Reg No: 01469

Session: 2014-2015

.....  
**Signature of the Supervisor**

**Dr. Shahneaz Ali Khan**

Associate Professor

Department of Physiology, Biochemistry  
and Pharmacology

Faculty of Veterinary Medicine

**Faculty of Veterinary Medicine  
Chittagong Veterinary and Animal Sciences University,  
Khulshi, Chittagong-4225**

**June 2020**

## Table of Contents

List of figures .....	3
List of abbreviations .....	4
Abstract .....	5
Chapter 1: Introduction .....	6-7
Chapter 2: Materials and Methods .....	8-10
Chapter 3: Result .....	11-13
Chapter 4: Discussion .....	14-15
Conclusion .....	15
References .....	16-17
Acknowledgements .....	18
Biography .....	19

## List of Figures

Figure 1: Study area .....	8
Figure 2: Abscess in Neck region .....	11
Figure 3: Sedation using Xylazine hydrochloride .....	11
Figure 4: Shaving the abscess area .....	12
Figure 5: Making the incision .....	12
Figure 6: Removal of the pus .....	12
Figure 7: Cleaning the content & passing the Seton .....	12
Figure 8: 9 <sup>th</sup> day after dressing .....	13
Figure 9: 15 <sup>th</sup> day after dressing .....	13
Figure 10: 18 <sup>th</sup> day after dressing .....	13
Figure 11: Healing at 19 <sup>th</sup> day after surgery .....	13

## List of abbreviations

Abbreviation	Elaboration
BW	Body Weight
Gm	Gram
Inj	Injection
IM	Intramuscular
L	Litter
Liq	Liquid
PO	Per Oss
SID	Single In Die
Tab	Tablet

## **Abstract**

This case report describes successful surgical management of the abscess in neck region of a 4-years-old bull. Clinical examination revealed swelling & pain through palpation in the affected region. The pus was filled with hot mass but semi-hard in consistency, though inflammatory sings was diagnosed. The bull was successfully treated by antiseptic dressing through utilizing povidone iodine. The drainage of pus was performed with a Seton protruding out of the incision to allow pus drainage. Finally, the combined antibiotics preparation administered parentally with a dose of Amoxicillin 1.325gm & Cloxacillin 1.325gm, for 7 days. The bull was successfully recovered after 18th days of post-intervention without any complications.

**Keywords:** Abscess, Surgical management, Proper dressing & Seton, Antibiotics.

## Chapter 1: Introduction

An abscess is a circumscribed inflammatory lesion consist of a purulent exudate 'the pus' surrounded by a ' limiting membrane ' the pyogenic membrane (Tyagi et al., 2012). According to the Sahooet al., 2015, abscess may develop anywhere in the body. A skin abscess, also called a boil, is a bump that appears within or below the skin's surface & it is one of the common types of abscess that appears externally as a swollen, pus filled lump under the surface of the skin. Internal abscess that develop inside the body or in an organ or the space between organs (Alharbi KB et al., 2012 & Fontaine et al., 2008). The most common sites of a skin abscess are head, neck /dewlap, back, chest & limbs in animals or ruminants.

The symptoms of an abscess depend on where it developed in the body. The internal abscess is more difficult to identify because it is inside the body. However, the symptoms of an abscess include redness, tenderness, pain in the affected area, raise of temperature & swelling (if the abscess are near the skin layer or constitutional symptoms (if the abscess are deep).Sometimes loss of function may see in the affected part. When press the swelling it may feel fluid-filled. Moreover the area of redness often extends beyond the swelling (Misk et al., 2008).

An abscess should be differentiated from bursitis, cysts, hematoma, hernia & other swelling by an exploratory puncture. If it is cysts, it reveals serous fluid; if it is hematoma, it reveals blood; if it is bursitis, it reveals synovial fluid; in case of hernia nothing or intestinal content may reveals by an exploratory puncture(Abdel-Hadyet al., 2015). It is recommended to double check in most cases that the swelling is fluid-filled, and not an indurated fibrous lump, hematoma or hernia before incising. In most of the cases skin abscess are harmless & may subside without treatment. However, in some cases, an abscess can lead to serious, potentially life- threatening complications if it remain untreated. Sometimes, skin abscess are troublesome to treat & may require laceration or drainage (Kofler et al., 2004).

Most subcutaneous abscess caused by a breach of surface of the skin or mucous membrane & the entrance through the breach by pyogenic organisms. Such as subcutaneous neck abscess due to the unconscious hitting in neck region with blunt stick in a cattle. The most common bacterial species that causes skin abscess are Staphylococcus species. These bacteria may enter the body through hair follicle by injury or wound that has punctured or broken the skin. In rare cases, virus, fungi or parasite may causes abscess (Hassan et al., 2019 &Radostits et al., 2006).

The body's defense mechanism especially the white blood cells attack the bacteria when bacteria enter the body & some nearby tissue dies, producing a hole that then fills with pus to form an abscess. The pus may consist of bacteria, dead & living neutrophil, cellular debris, serum & lymph. The color of pus may vary from opaque, yellowish or greenish. The consistency of the pus may be creamy, curdy or cheesy. When the infection continues & more pus are formed then the abscess may get larger & more painful. A toxin named Panton Valentine leucocidine that kill the white blood cell are produced by some types of Staphylococcus species. As a result the body produce more cell to keep fighting against the infection which may lead to repeated skin infection (Kobayashi et al., 2015).

There are several different ways for treating an abscess which may depend upon the types of abscess, its location & how large it is. The main treatment option include a drainage procedure, surgery& antibiotic therapy. Before starting manipulation proper physical or chemical restraining of the animal may be important. Aseptic procedure that reduce further infection & increase the prognosis of the condition should followed during the procedure. A small skin abscess which may drain naturally, dry up & disappear without any treatment but in case of large subcutaneous abscess it may need to be clear the infection by using antibiotic & pus may be drain out by incision which create a ventral drainage hole & thoroughly flush with clean water under moderate pressure from a hose or syringe using gloved finger for the removal of the pus (Kofler et al., 2004 & Hassan et al., 2019). Thus, assuring a clean, healthy& largely free of microorganisms can help to reduce the risk of skin abscess (Alharbi KB et al., 2012 & Tiwari et al., 2011). The present case report describes a case of subcutaneous neck abscess of a bull &its successful surgical management.

## Chapter 2: Materials and Methods

### Case history

A 4-years-old bull of 400kg body weight in Ishurdi upazila, pabna, with a complaint of large growth in neck region was presented for the treatment. The bull was so aggressive. In few days ago, the owner unconsciously hit the bull in neck region with a blunt stick for restraining purposes. After few days of hitting, a large mass was produced in neck region which was semi- hard in consistency but painful to touch that is presented for correction purpose.

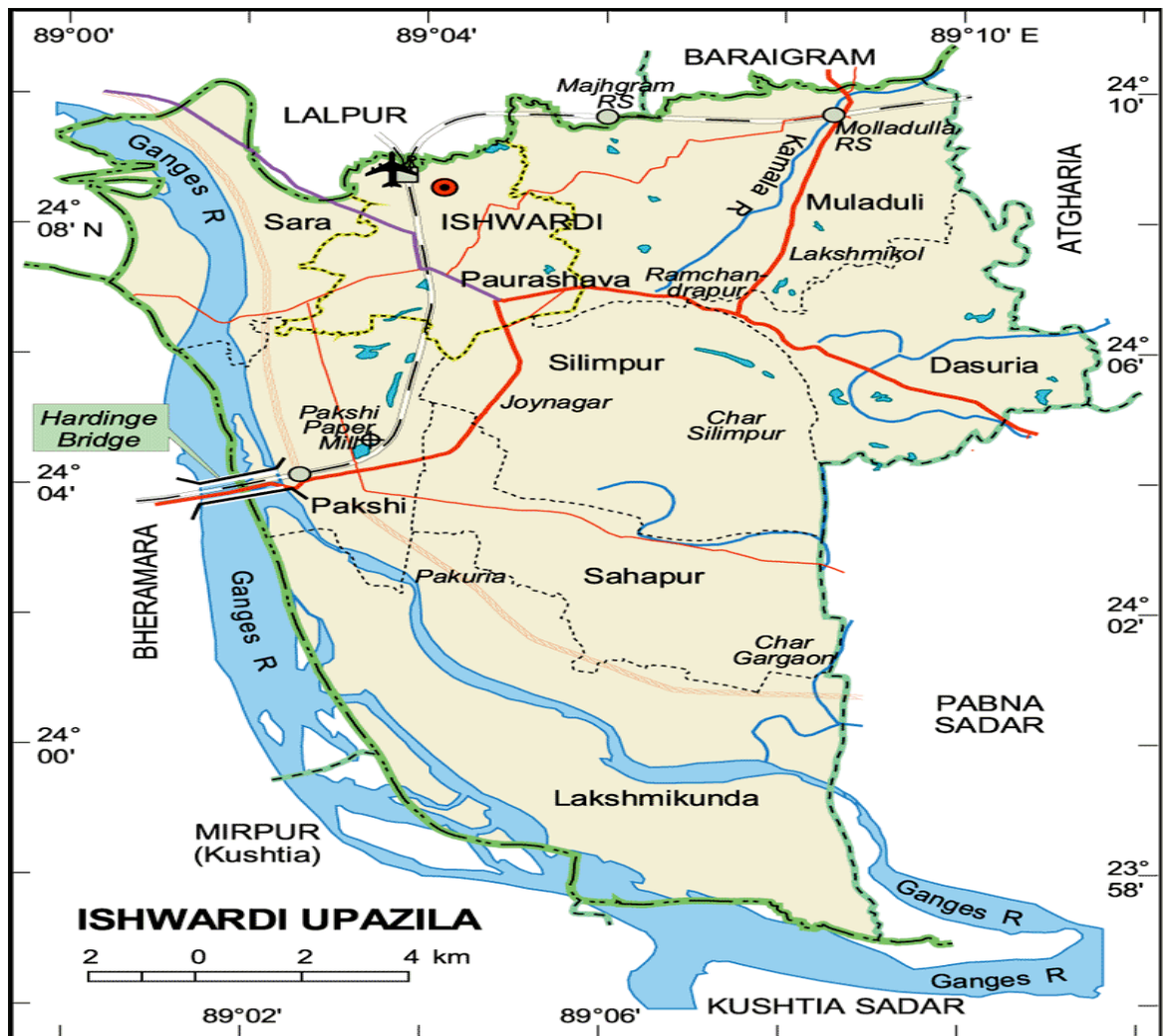

Figure 1: Study area



## **Diagnosis**

On clinical examination, the mass were warm, painful to touch but semi-hard in consistency. Owner's complain revealed the gradual reduction of feed intake and water consumption which due to the enlarged mass. All physiological parameters were normal (Rectal Temperature - 101°F, Respiration Rate - 24/minutes, Heart Rate - 60/minutes, Pulse – 58/minutes). To differentiate it from other types of lesions causing swelling like hematoma, tumor, hernia etc. aspiration of the content form the swollen mass was performed using 16-gauge sterile needle that revealed creamy discharge. The case was diagnosed as an abscess. The maturation of the abscess was done by the application of magnesium sulphate ointment which completed in 3rd day. On fourth day, exploratory puncture was again done by 16-gauge needle on the swollen mass which revealed thick, yellowish, creamy pus came out through the punctured site. On the basis of clinical history, clinical findings & exploratory puncture the case was diagnosed as a subcutaneous skin abscess. Finally it was decided to perform surgery for complete evacuation of the pus to relieve the patient from this condition.

## **Preoperative Animal Preparations**

For physical restraining, the bull was handled with rope-assisted by personnel to adequate restrain it in the sternal recumbency. The hair surroundings the swelling was aseptically prepared by clipping, shaving, scrubbing, washing with water & savlon.

Anesthesia: Chemically the animal was sedated by Xylazine hydrochloride (Xylazine®) at a dose rate of 0.1 mg/ kg body weight through intramuscular route. Later, the operation site was achieved by local infiltration of 15ml 2% Lidocine hydrochloride (Jasocaine®, Jayson Pharmaceutical Limited, Dhaka, Bangladesh).

## **Operative Procedure**

The dependent area of abscess swelling in the neck region was prepared. The animal was cast & restrained in sternal recumbency. After preparing the proposed site of incision, an incision with a disposable sterile scalpel was made around the tip of the abscess. Large quantity of pus was drained & cavity filled with dilute (10 %) povidone iodine. The

cavity was then every time packed with a gauze soaked in povidone iodine (10%) with a Seton protruding out of the incision to allow pus drainage. Finally the bull was admitted at home.

## **Post-Operative Management**

Small skin bleeding was noticed in post-surgery but it is normal & help to heal the wound unless continued for a long period. Abscess was drained & dressed successive nine days (after surgery - 1st, 2nd, 3rd, 5th, 7th, 9th, 12th, 15th, 18th day) of post-operation. Besides, the bull was kept on combined antibiotic therapy [amoxicillin 1.325gm & Cloxacillin 1.325gm (Inj. Amcox - 2.5gm, 1ml/ 20kg BW, SID, IM, for 7 days)] and Analgesic [Meloxicam 0.5 mg/kg, BW (Inj. Melocam - 10 ml, 1 ml/10 kg, BW, SID, IM for 3 days)]. Moreover, a vitamin preparation ( Tab. Vita oral vet, 3 tab daily, PO, for 10 days) and a Zinc preparation ( Liq. Xinc care - 1L, 40ml daily, PO for 10 days) was given. The owner was also advised to clean the wound daily by using normal saline solution, use povidone iodine ointment at surgical site & subjectively assess for discomfort, pain, unpleasant discharge & inflammation at the wound site.

## Chapter 3: Result

The post-operative evaluations showed good healing progress of the surgical site. All wound successfully recovered in 19th days of surgery without any complications & no signs of recurrency were seen during this period.

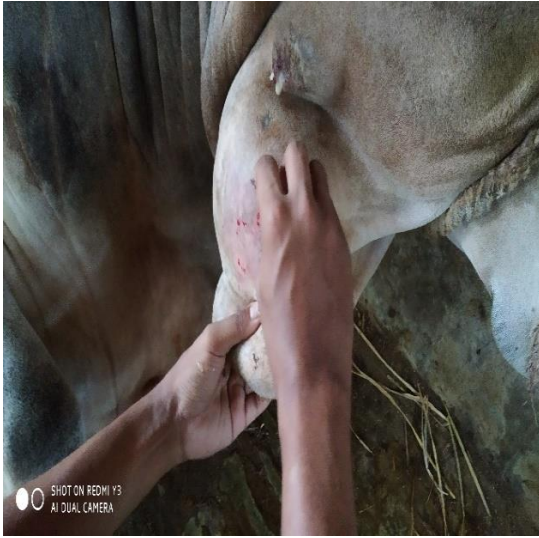
The following figures portrays the sequential steps followed in the surgery (a) Neck abscess (b) Sedation using Xylazine hydrochloride (c) Shaving the abscess area (d) Making the incision (e) Removal of the pus (f) Cleaning the content & passing the seton (g) 9th day after dressing (h) 15th day after dressing (i) 18th day after dressing (j) healing at 19th day after surgery.



2. Abscess in Neck region



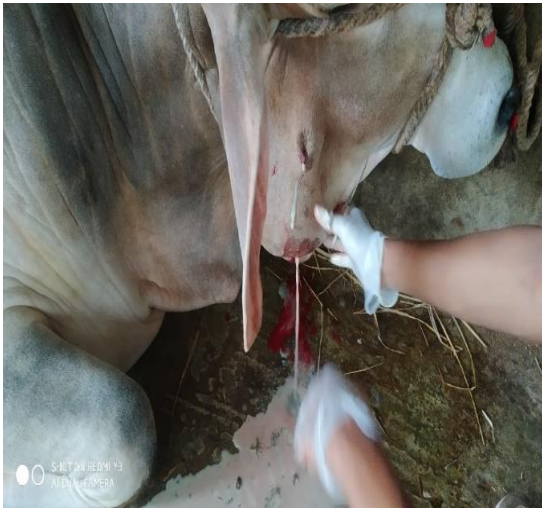3. Sedation using Xylazine hydrochloride



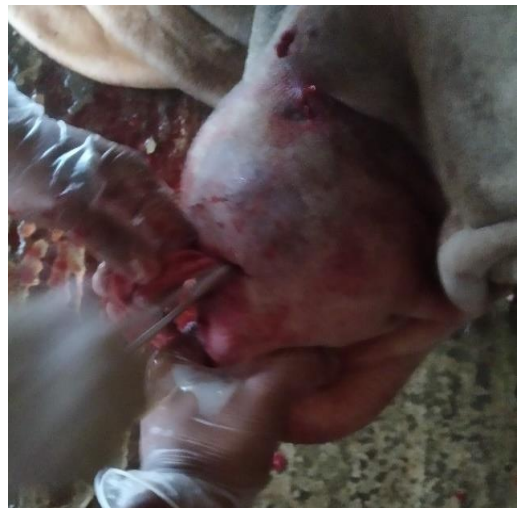4. Shaving the abscess area



5. Making the incision



6. Removal of the pus



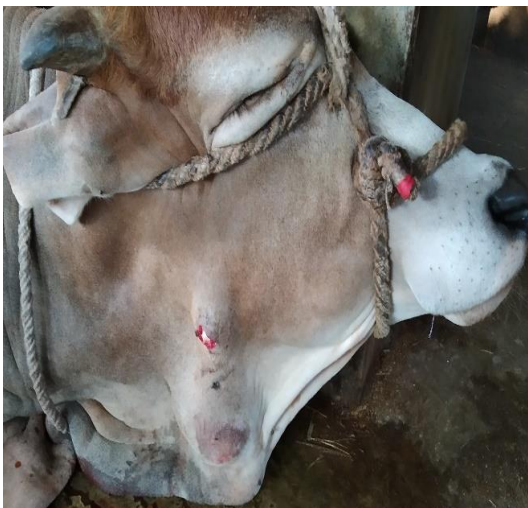7. Cleaning the content & passing the Seton



8. 9<sup>th</sup> day after dressing



9. 15<sup>th</sup> day after dressing



10. 18<sup>th</sup> day after dressing



11. Healing at 19<sup>th</sup> day after surgery

## Chapter 4: Discussion

Abscess is the collection of pus in confined tissue spaces, usually caused by bacterial infection & Staphylococcus species are the most common one (Blood et al., 2000). In this case the abscess was caused by owner's unconscious hitting by a blunt stick in neck region. Organisms may enter the tissue by direct penetrating trauma with a contaminated object, spreading via hematogenous or lymphatic routes from a distinct place. Abscess may begin in an area of injury or in compromised tissue where leukocytes accumulate. Progressive dissection by pus or necrosis of surrounding cells expand the abscess (Blood et al., 2000). In present case, trauma was also visible over the abscess and it could be speculated that the causative organisms have gained access either through hematogenous or lymphatic route. Various factors which predispose for abscess formation may be impaired host defence mechanism, tissue ischemia or necrosis, hematoma, presence of foreign bodies, obstruction to normal drainage ( in the urinary, biliary or respiratory tracts etc.)(Kofler et al., 2004). The signs & symptoms of cutaneous & subcutaneous abscess are redness, swelling, heat, pain, tenderness & these findings are reported (Stephen JE et al., 2010). Similarly for deep abscess, local pain, tenderness, systemic symptoms such as fever, anorexia, weight loss are common findings (Thorat et al., 2008). In case of diagnosis, the present case revealed the mass were warm, painful to touch but semi-hard in consistency. To differentiate it from other types of lesions causing swelling like hematoma, tumor, hernia etc. aspiration of the content from the swollen mass was performed using 16-gauge sterile needle that revealed creamy discharge. So, this case was diagnosed as abscess. Superficial abscess may subside with heat & oral antibiotics. However in this case, the animal was first physically restrained in sternal recumbency then sedated by Xylazine hydrochloride, the hair surrounding the swelling was aseptically prepared by clipping, shaving, scrubbing, washing with water and savlon. After preparing the proposed site of incision, an incision with a disposable sterile scalpel was made around the tip of the abscess. Large quantity of pus was drained & cavity filled with dilute (10 %) povidone iodine. In this case, the antiseptic drainage (Gauze wick) helped wound to keep it open and if any more pus is produced it can be drained away easily by wound dressing. Antibiotics given in this case help to kill the infection and prevent it spreading. Similar findings also seen in Radostits et al., 2007 that revealed in case of subcutaneous or deep abscesses, surgical drainage & use of antibiotic therapy is

required for complete resolved & usual healing process of an abscess. For prevention of subcutaneous abscess in ruminants, it is essential to strictly maintain the biosecurity including proper cleanliness of the farm; give adequate space to prevent coalition among bulls; reduce the aggressiveness of bull by proper training, handling by familiar figure or castration the bull before 6 month of age because the bacteria may enter the body through hair follicle by injury or wound that has punctured or broken the skin by any means. The total cost of abscess management in these case was 15,000tk Bdt. including veterinary doctor, anesthesia and medication. So the preventive measures should be strictly maintained.

## **Conclusion**

Based upon this study, it could be concluded that at farm or field level, successful management of a large subcutaneous abscess in cattle can be attained through proper or regular drainage of the pus followed by Seton protruding out of the incision to allow drainage of pus so that the parental administration of antibiotics is effective.

## References

- Abdel-Hady AAA., Sadan MA., Abdel-Kawy HA., 2015. The common surgical affections in sheep and goats at Qena governorate, Egypt. *Research Opinions in Animal and Veterinary Sciences*, 5(2), pp.84-93.
- Alharbi KB., Mahmoud OM., 2012. Abscess disease of sheep and goats: A disease of major concern in Saudi Arabia that urges production of an effective vaccine. *Journal of Agriculture and Veterinary Sciences*, Qassim University, (2), pp.5.
- Blood DC., Radostitis DM., Arundel JH., Gay GC., 2000. Diseases of the alimentary tract, Special examination In *Veterinary Medicine*, 7th edn. Bailliere and Tindal, London, pp.160-167.
- Fontaine MC., Baird GJ., 2008. Caseous lymphadenitis. *Small Ruminant Research*, 76(1-2), pp.42-48.
- Hassan N., Parrah JD., Hamadani H., Ganie AA., Dar RA., Dar KA., 2019. Management of large subcutaneous abscess in a dairy cow. *Journal of Pharmacognosy and Phytochemistry*, 8(1), pp.1652-1653.
- Kofler J., Martinek B., Reinöhl-DeSouza C., 2004. Treatment of infected wounds and abscesses in bovine limbs with Ligasano-polyurethane-soft foam dressing material. *Berliner und Munchener tierarztliche Wochenschrift*, 117(9-10), pp.428-438.
- Kobayashi SD., Malachowa N., DeLeo FR., 2015. Pathogenesis of *Staphylococcus aureus* abscesses. *The American journal of pathology*, 185(6), pp.1518-1527.
- Misk NA., Misk TN., Semieka MA., Ahmed AF., 2008. Body surface cysts in some farm animals. In 25th World Buiatrics Congress. July, pp. 6-11.
- Sahoo S., Ganguly S., 2015. Surgical management of abscess in camel: A Case Report. *World Journal of Biology and Medical Science*, 2(4), pp.32-4.
- Radostits OM., Gay CC., Hinchcliff KW., Constable PD., 2007. A textbook of the diseases of cattle, horses, sheep, pigs and goats. *Veterinary medicine*, 10, pp.2045-2050.
- Radostits OM., Gay CC., Hinchcliff KW., Constable PD., 2006. *Veterinary Medicine E-Book: A textbook of the diseases of cattle, horses, sheep, pigs and goats*. Elsevier Health Sciences.



- Stephen JE., Edward CF., 2010. Textbook of Internal Medicine, 7th edn. Saunders, Elsevier, Canada.
- Tyagi RPS., Singh J., 2012. Ruminant Surgery. 11th edn.
- Tiwari SK., Kashyap DK., 2011. Chemo-Therapeutic management of foot abscess in female Asian Elephant (*Elephas maximus*). Zoo's print, 26(12), pp.24.
- Thorat MG., Bhikane AU., Yadav GU., Ghadage HR., Mahajan MV., 2008. Clinical management of multiple abscesses in bullock. Intas Polivet, 9(1), pp.79-80.

## **Acknowledgement**

All praises are due to “**Almighty Allah**” who enabled the author to complete this report successfully.

The author express his deep sense of gratitude, heartfelt respect and immense indebtedness to his supervisor Associate Prof. **Dr. Shahneaz Ali Khan**, Department of Physiology, Biochemistry and Pharmacology, Chattogram Veterinary and Animal sciences University for his valuable advice, suggestions, inspiration and scholastic guidance.

The author deeply owe and express his deep sense of gratitude and thanks to Professor **Dr. Md. Abdul Ahad**, Dean, Faculty of Veterinary Medicine and Professor **Dr. A.K.M Saifuddin**, Director of External Affairs, Chattogram Veterinary and Animal Sciences University for their valuable suggestion & inspiration during this internship period.

I feel much pleasure to convey special thanks to DR. Shazit Hasan, DR. Sabiha Zarin Tasnim , Aslam Hossain (FVM-21<sup>st</sup> batch), Md. Hasibul Hasan (EWU), my seniors & my friends for their cordial help.

Last but not least I would like to express my gratitude, cordial respect to my beloved parents and my younger sister for their immense sacrifice, blessings and encouragement.

## Biography

Name	Md. Shaifur Rahman
Parents name	Md. Azizur Rahman Mst. Shaifun Naher
Present position and affiliation	Intern student, 20 <sup>th</sup> Batch, FVM, Chittagong Veterinary and Animal Science University.
Educational background and year	Doctor of Veterinary Medicine in2019 (appeared), Chittagong Veterinary and Animal Science University. I completed my S.S.C and H.S.C with GPA5 from Govt. Sara MarwariModel School and College& Ishwardi Govt. College respectively.
Research interest	Pet Animal Sector
Aim	Work as a veterinary practitioner and carrying out the veterinary profession.