

## Table of Contents

Contents	Pages
Abstract	3
Introduction	4-5
Materials and Methods	5-9
Result	9-15
Discussion	15-16
Conclusion	17
Limitations	17
References	18-19
Acknowledgment	20
Biography	21

<b>Table number</b>	<b>Title</b>	<b>Pages</b>
1	Measurment (Length, Width and Thickness) of testes	10
2	Weight of testes	12

<b>Figur number</b>	<b>Title</b>	<b>Pages</b>
1	Shape of the paraffin block	8
2	Graphical Presentation of length of testes	10
3	Graphical Presentation of width of testes	11
4	Graphical Presentation of thickness of testes	11
5	Graphical Presentation of weight of testes	12
6	Color of testes	13
7	Microscopic slide of testes of tom (group-I)	13
8	Microscopic slide of testes of tom (group-II)	14
9	Microscopic slide of testes of tom (group-III)	14

## Abstract

---

The goal of the study was to determine the actual location of testes and morphometric study of turkey tom testes. Fifteen turkey toms were collected from a turkey farm of different age variation then divided into three groups and reared in the poultry research shed under the Dep. of Dairy and Poultry Science. Then sacrificed the toms and determined the location of testes at age variation and collected the samples for morphometric study at the Anatomy and Histology laboratory under the Dep. of Anatomy and Histology in Chattogram Veterinary and Animal Sciences University. Then the length, width, thickness and weight of the testes were measured. For microscopic study permanent slides were prepared. The testes were located in abdominal cavity caudal to the respective lung on the either side of midline. The testes were oval in shape in all ages. The color of testes were varied according to age, during immature stage they were yellowish and became white gradually when became mature. Microscopically the spermatogenic cells were round and nuclei were dark-round in group-I and group-II. The spermatogenic cells were columnar and nuclei were oval in group-III. No spermatozoa were present in group-I and in group-II and group-III spermatozoa were present. Through the knowing, the actual location of testes the turkey farmers can easily collect semen from turkey tom by the palpation or message method. Then the turkey farmers can artificially inseminate (AI) to the turkey hen which increases the fertility and hatchability of egg. The turkey farmers also can caponize the turkey toms through the knowing of testes location.

### **Key words:**

Turkey, Tom (Male turkey), Testes, Spermatogenic cell, Spermatozoa

## **The morphometric study of testes of Turkey Tom.**

---

### **INTRODUCTION**

Bangladesh is a developing country. The area of the country is about 1,47,570 sq. km but large number of population about 160 million.(BBS,2011) In the recent years poultry rearing becomes popular than any other livestock in our country. Among the poultry species turkey farming is profitable because of its size, easy of handling, rapid growth rate, high adaptability, high resistance to diseases, low mortality rate, less feeding cost and high market price. (Asaduzzaman et al.,2017)It is an emerging subsector of livestock which play a vital role in the economic development of Bangladesh. It was observed that turkey thrives better under arid conditions, tolerates heat better, ranges farther and has higher quality meat (Yakubu et al., 2013). In a study it was found that turkey is an excellent insect forager and most crops that are troubled by insect population including vegetables are candidates for insect control by turkeys (Grimes et al., 2007).

Poultry consumption in developing countries is projected to grow at 3.4% per annum to 2030, followed by beef at 2.2% and ovine meat at 2.1%, and in the world as a whole, poultry consumption is projected to grow at 2.5% per annum to 2030, with other meats growing at 1.7% or less (Rischkowsky et al.,2007). According to DLS the meat requirement is 120gm/day/head and the demand was 72.97 lakh ton in 2018-2019. Against a daily demand of 120 grams of meat per person, Bangladesh is currently producing 124.99 grams of meat per person. The meat production was 75.14 lakh ton in 2018-2019(The Daily Star.,8Sep. 2020).

Nowadays it is seen that the improvement of life style and per capita income in our country, some consumers have personal preferences about the variety of color, texture and flavor of poultry meat. There is a great demand of choosing the lean and tasty turkey meat in compared to soft textured broiler meat. It was observed in a study that consumption of turkeys and broilers as white meat rising worldwide and a similar trend also existed in developing countries.(karki et al.,2005)Turkey can meet up the protein

demand and consumers preference. Turkey farming may play a strong role in the economic development of Bangladesh and also can help in removing unemployment.

In case of turkey farming most turkeys are artificially inseminated. Artificial insemination (AI) is very important for turkey farming.(Nestor et al.,1968) Due to the heavy weight of turkey they cannot copulate properly and decrease the fertility rate. It was found that turkey farming heavily depended on AI which increases the production and fertility rate( Ogasawara, F. X et al.,1966).For proper semen collection it is very important to know the actual location of testes.

The male reproductive system of a turkey tom consists of a pair of testes, seminiferous tubules; rete testis; ductuli efferentes; connecting ductules; ductus epididymis; ductus deferens; receptaculum ductus deferentis; papilla ductus deferentis and a single rudimentary phallus as a copulatory organ(R A Hess et al.,1976).The testes are the primary reproductive organ. In a study it was found that the testes of guinea fowl were covered by a layer of peritoneum.( Kannan et al., 2015) Microscopically seminiferous tubules are the unit of testes. The seminiferous tubules begin blindly from the periphery of the testes and directed towards dorsomedial aspect. In a study it was observed that the seminiferous tubules of quail testes were filled by stratified epithelium of spermatogenic cells and sertoli cells.(Al-Tememy et al.,2010)

### **Objectives:**

- To determine the actual location of testes in turkey tom.
- To study the morphometric of testes.
- To study the length, width, thickness, weight of testes in different age.

### **MATERIALS AND METHOD**

The study was carried out to determine the actual location of testes (morphometric and histometrical) of turkey Tom (*Meleagris galopavo*). The study was carried out in the anatomy and histology lab under the Dept. of Anatomy & Histology, Faculty of veterinary medicine, Chhattaogram Veterinary and Animal Sciences University.

**Selection of study population:**

The study was carried out within 15 toms and they were divided among three groups at the age variation. The groups are Group-I(15-20weeks), Group-II(21-35weeks) and Group-III(36-50weeks). The samples were collected from each group consists of 5 toms.

**Source of the samples:**

The samples were collected from Shuvo Turkey Farm, Hathazari, Chattogram. After the physical examination of turkey toms, toms with apparently healthy status and without any detectable signs of abnormalities and disease were selected as sample.

**Experimental design:**

Prior to the starting of the study, an experimental schedule was fixed specifying different aspects of the total work and it was maintained during the whole study. The experiment was carried out on each group for efficiency of work and to minimize the result errors.

**Management:**

After collection, all toms were reared in the poultry research shed under the department of Dairy and Poultry Science, Faculty of Veterinary Medicine, Chattogram Veterinary and Animal Sciences University (CVASU). Optimum temperature, lighting and ventilation were maintained. Water and feed were provided adlibitum. All procedures were maintained by the Animal Care and Welfare Committee of our institute.

**Sacrifice of toms:**

The toms were slaughtered by Halal method.

**Collection of sample:**

After slaughtering of turkey tom and cessation of the heartbeat and after evacuation of entire blood, testes were collected by cutting skin, thoracic bone, lumber bone and abdomen. The collected samples were washed properly using normal saline. The total length, diameter and thickness of the testes were determined. Samples were collected from each group per day.

**Gross Anatomical investigation and measurement:**

The shape, color and consistency of the testes were observed. After that, weight of samples were taken by digital electric machine and recorded. By using digital “slide calipers” the longitudinal diameter, transverse diameter, thickness were measured.

**Preservation of the sample:**

After the gross anatomical examination the samples were cut to an appropriate size and tagged with a piece of paper to identify the sample age, name and number and then fixed by chemical fixation using 10% buffered formalin solution (p<sup>H</sup>7.4) and shaken 24 hours for fixation.

**Preparation of slide:**

Procedure of histological slide preparation

**Dehydration:**

The tissues are washed in water overnight prior to the dehydration process. The tissues are dehydrated in the dehydration process using different concentration of alcohol (ethyl alcohol) and xylene. The tissues were placed in different solutions as following-

50% alcohol- (ethyl alcohol) (starting from water) - 2 hours

70% alcohol- 2 hours.

90% alcohol- 2 hours.

95% alcohol- 2hours.

100% alcohol (first time) - 1 hour

100% alcohol (second time) - 1 hour

**Cleaning:**

Alcohol+ xylene (50%) – 2 hours or overnight.

Toluene or xylene (first time) - 1/2–1 hour

Toluene or xylene (second time) - 1/2–1 hour

**Paraffin infiltration:**

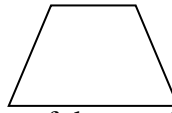
From the second change of xylene the tissues are moved through several changes of xylene + paraffin and kept in oven for maintaining specific temperature (58-60<sup>0</sup> c).

**Embedding of tissue:**

The tissues are then embedded in 100% paraffin and paraffin blocks were mounted using suitable pieces of metal (two L shaped metal join together to make a block).

**Sectioning of tissues:**

Prior to sectioning of the tissues using rotary microtome machine the face of each paraffin blocks were trimmed properly so that it is in the shape of a trapezoid with the top and bottom sides being parallel. The block was then cut at a diameter of 6  $\mu\text{m}$  (1 micro miter =1/1000 mm, 10 mm= 1cm).



**Fig -1:** Shape of the paraffin block

**Placing the tissues in the water bath:**

Bundles of cut sections (paraffin ribbon) were then placed in water bath at a temperature of 58°C in order to melt the paraffin and also to spread the tissues properly. Necessary amount of slides are taken and cleaned properly using blotting paper. Then with a diamond marker one end of the each slide were scratch marked to identify the sample name.

**Hematoxylin staining:**

Washed Then the slides were stained by Hematoxylin for 15 minutes and then in running tap water until clearing for 5 minutes.

**Acid alcohol:**

Then a few dips (2-4) in 1% acid alcohol. To remove the excess stain this step was done. Then washed in running tap water for 5 minutes.

**Eosin staining:**

Eosin (1%) staining for 1 minute.



**Redehydration:**

All slides were rehydrated gradually by increasing concentrations of ethyl alcohol (70%, 95%, and 100%) for 5 minutes each in each concentration.

**Cleaning & staining for 1 minute:**

Finally, the following reagents were used to clean and remove the alcohol

Alcohol (50%) + xylene (50%) - 5 minutes.

Xylene I-5 minutes.

Xylene II-5 minutes.

**Mounting of slide:**

After completing the staining procedure the slides were air dried properly. Then cover slips were mounted in the slides very carefully using a suitable mounting medium (Canada balsam) without producing any bubbles. The excess stain was removed very carefully with tissue paper. Mounted slides were allowed to harden.

**Visualization under microscope:**

After the slides were properly fixed and dried the slides were taken under microscope. Slides are then visualized at 4x, 10x objective and still images were taken by using a computer operated (top view) software.

**RESULT****Gross characteristics:****Location:**

The testes of turkey tom were placed symmetrically within the abdominal cavity caudal to the respective lungs on either sides of the vertebral column. The left testis was anterior than the right testis and the left testis was larger than the right testis in all age among the three group.

**Shape :**

The testes were oval shape in all ages of toms.

**Size:**

Tabel-1: Measurement (Length, Width and Thickness) of testes

Group	Length(cm)	Width(cm)	Thickness(cm)
Group-I(15-20weeks)	2	0.8	1.4
Group-II(21-35weeks)	4.5	2.8	3.2
Group-III(36-45weeks)	6	3.2	4.4

In case of group-I the testes length was 2cm, width 0.8cm and thickness 1.4cm. In group-II the testes length was 4.5cm, width 2.8cm and thickness 3.2cm. In group-III the length, width and thickness of testes were according to 6cm, 3.2cm and 4.4cm.

Graphical presentation of Length

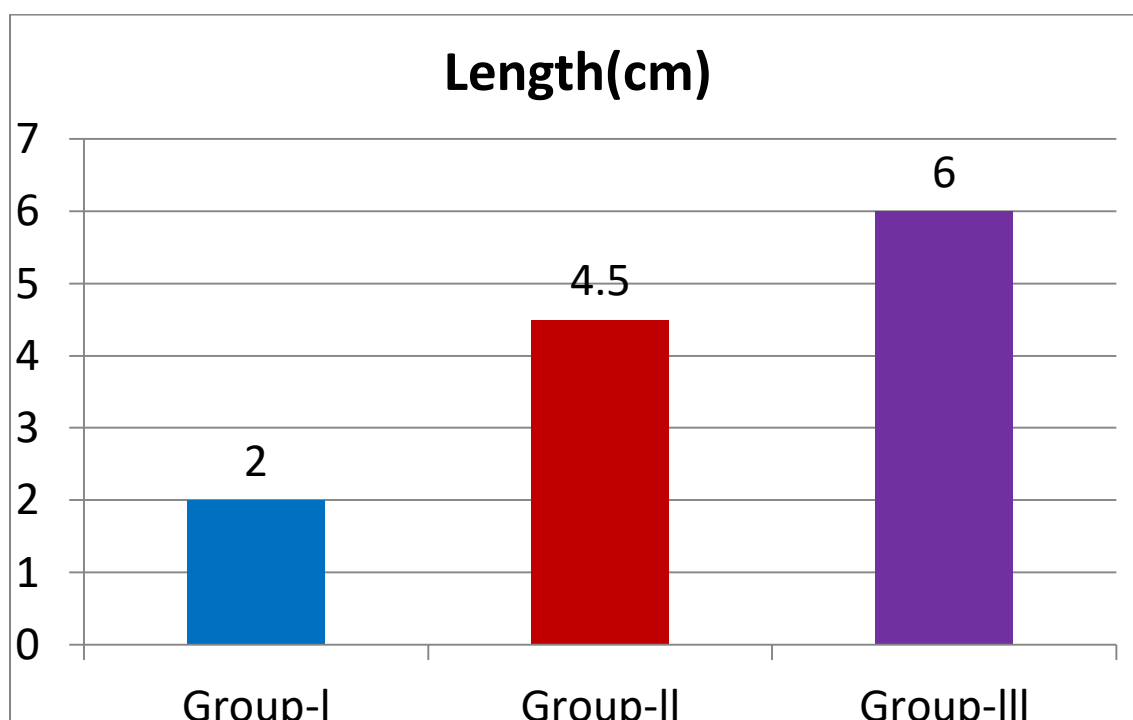


Fig 2 : Graphical Presentation of length of testes

From the graph we can see that the length of testes is increased according to age. The length was 2cm in group-I, 4.5cm in group-II and 6cm in group-III. The highest length was 6cm and lowest was 2cm.

Graphical presentation of width

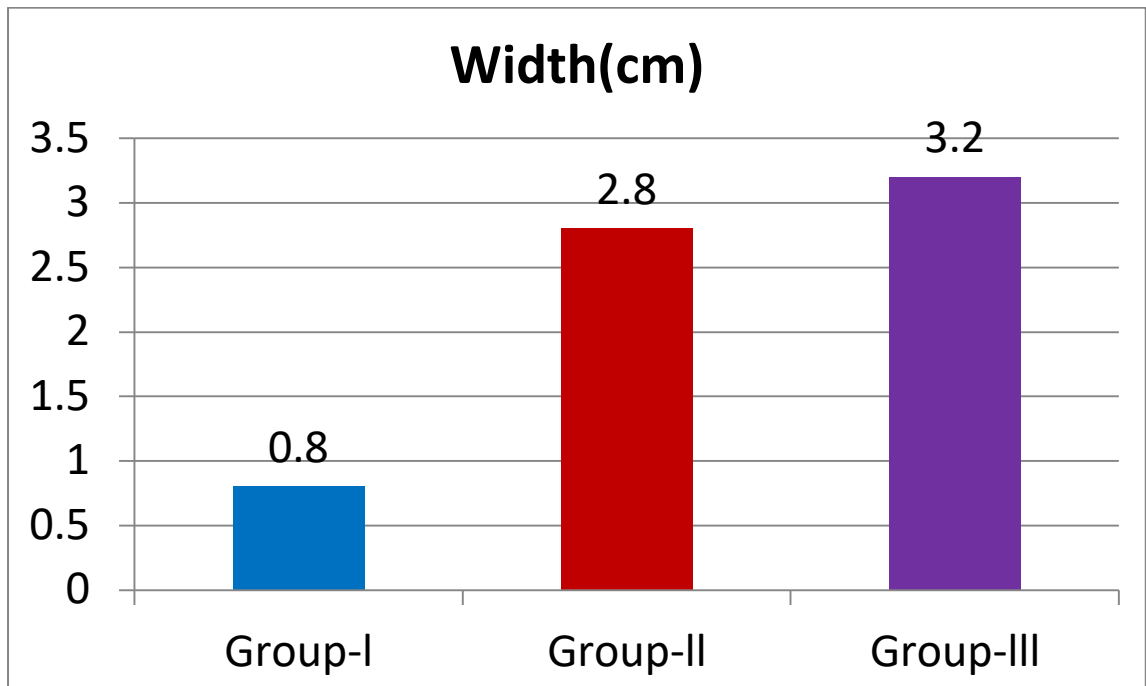


Fig 3: Graphical Presentation of width of testes

From the graph it is seen that the width of testes was 0.8cm in group-I, 2.8cm in group-II and 3.2cm in group-III. Highest width was 3.2cm and lowest width was 0.8cm.

Graphical presentation of thickness

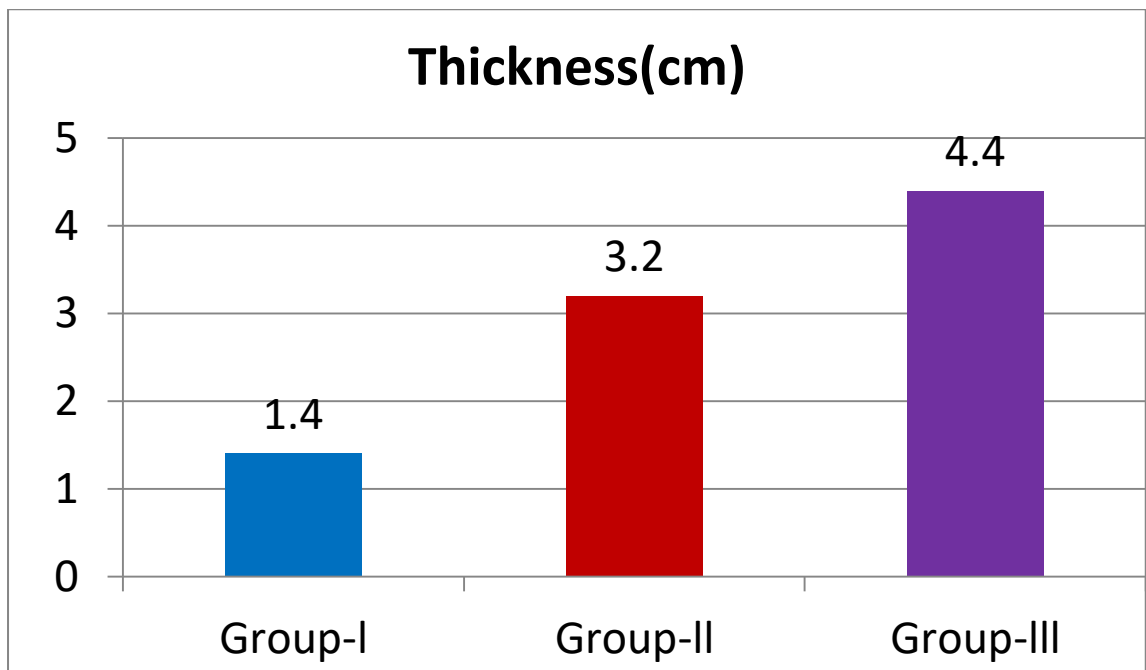


Fig 4: Graphical Presentation of thickness of testes

The thickness of testes was 1.4cm in group-I, 3.2cm in group-II and 4.4cm in group-III. The highest thickness was 4.4cm and lowest was 1.4cm.

**weight:**

Tabel-2: Weight of testes

Group	Group-I	Group-II	Group-III
Weight(gm.)	11	18	25

The weight of testes was 11gm. in group-I, 18gm. in group-II and 25gm. in group-III.

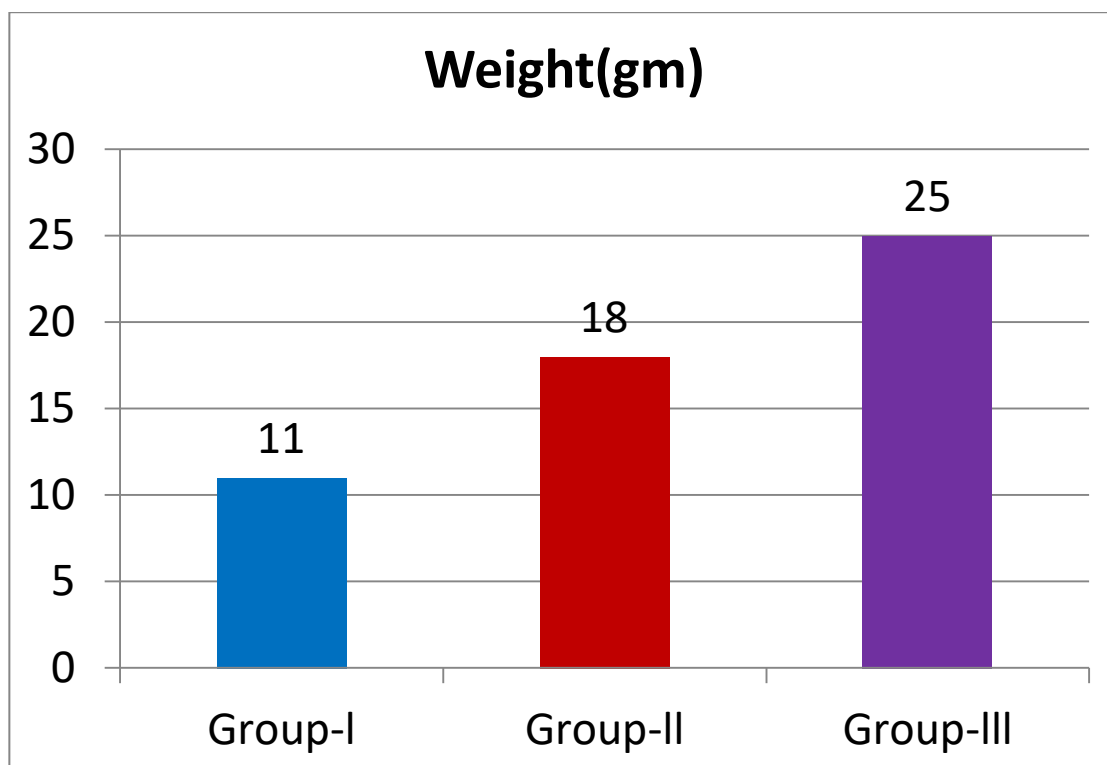
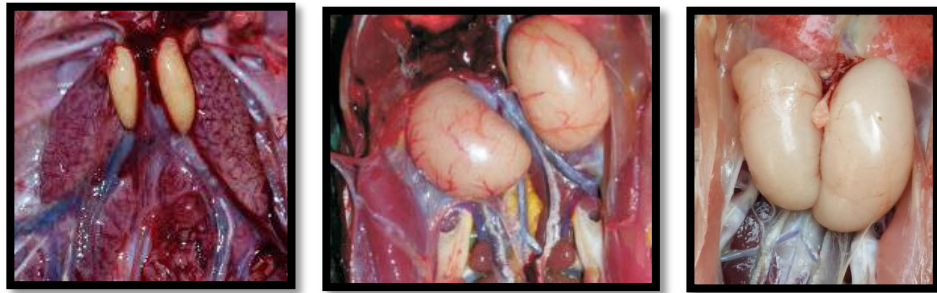


Fig 5: Graphical Presentation of weight of testes

From the graph we can observe that the weight of testes was increased according to age. The weight of testes was 11gm. in group-I, 18gm. in group-II and 25gm. in group-III. The highest weight was 25gm. and lowest was 11gm.

**Color:**



(A)

(B)

(C)

Fig 6: Color of testes

In case of group-I the color of testes was yellowish (Fig6:A), in group-II it was yellowish to white (Fig6:B) and in group-III it was white (Fig6:C) in color.

**Microscopic findings:**

In our study among the three groups the microscopic findings are given below

**Group-I:**

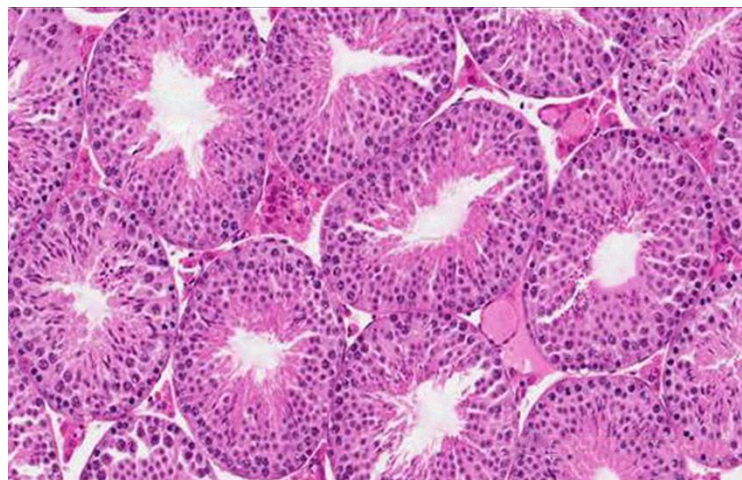
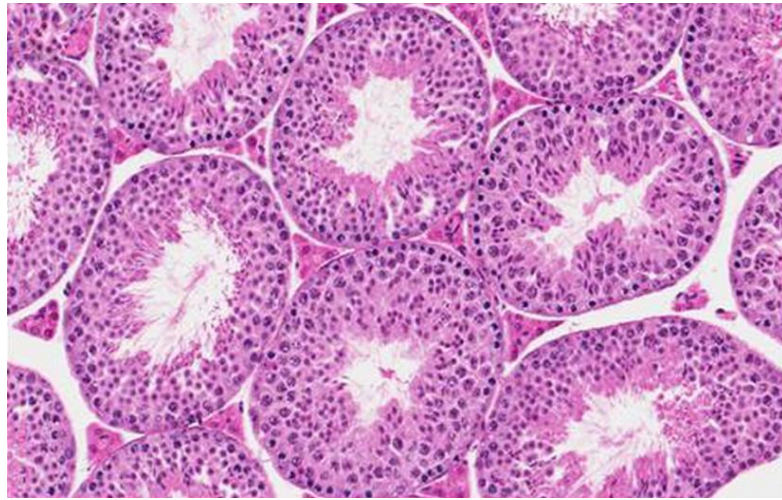


Fig 7: Microscopic slide of testes of tom (group-I)

From fig-7 it was seen that the spermatogenic cells were lied in the basement membrane of seminiferous tubules. The spermatogenic cells were round and nuclei were round and dark.

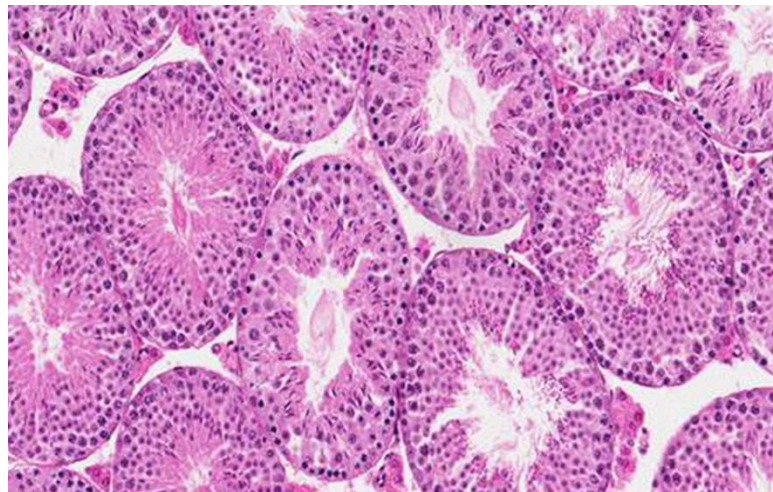
**Group-II:**



**Fig 8: Microscopic slide of testes of tom (group-II)**

In the microscopic slide fig-8 it was seen that the spermatogenic cells were extended from basal lamina of seminiferous tubules. The spermatogenic cells were cuboidal and nuclei were round shape. Few spermatozoa were present at the lumen. Leydig cells were present in the interstitial space of seminiferous tubules.

**Group-III:**



**Fig 9: Microscopic slide of testes of tom (group-III)**

From the microscopic slide fig-9 it was seen that the spermatogenic cells were columnar and elongated nuclei were found. Spermatozoa were present in almost all

lumen of seminiferous tubules. The leydig cells were huge in number and present in interstitial space of seminiferous tubules.

## **Discussion**

In our study we found that the testes were paired organ located in the abdominal cavity on the either side of midline in turkey toms. In a study they found in Japanese quail the testes were paired tubular organs situated within the body cavity, enclosed by peritoneal covering (AI-Tememy et al.,2010 and Kannan et al.,2015).In some other study it was found that the male bird contains pair of testes lying along the dorsal body wall (Kirby et al.,2000).The testis lie ventral to the anterior lobes of the kidney. In our study it was observed that in case of group-I the length of testes was 2cm and 4.5cm in group-II and 6cm in group-III. In the postmortem observation of the toms in all three groups it was found that the left testis was anterior than the right testis. In another study they found that the left testis was usually higher in position and large in size than the right one in pigeon (Kigir et al.,2010). The left testis was anterior in position than the right testis. (Rajendranath et al.,2015). Similar observations were also observed in case of Ostrich and Rhea.(Babic et al.,2004; Elias et al.,2007).

In group-I the color of testes was yellowish (Fig6: A) and in group-II yellowish-white (Fig6:B) and in group-III was white(Fig6:C). In some studies they were observed in immature birds, the testes were yellowish-white in color but it was white in mature guinea fowl (Aire et al., 1979). The color of the testes were black or dark green in emu (Cho et al., 1984 and Rajendranath et al., 2015).In a publication they published they found the color of testes were tan in ostrich and rhea (Hopkins and Constantinescu et al., 1995). It was also observed that the color of testes were white to whitish yellow or creamy in domestic birds (Nickel et al.,1977) .

The weight of testes was 11gm in group-I, 18gm in group-II and 25gm in group-III. In a study it was found in case of duck the mean weight of the left testis was 9.60 and the right testis was 8.88 gm. (Elbajory et al., 2013).

In our study we found in case of group-I (Fig :7) and group-II (Fig:8)the spermatogenic cells were round and nuclei were dark and in group-III (Fig:9) the spermatogenic cells

were columnar and nuclei were elongated. The spermatogenic cells were extended from the basal lamina. In a study they found that the sertoli cells were tall, columnar and extended from the basal lamina to the luminal border of the seminiferous tubules. It was usually irregular and it had a prominent nucleolus, and it was situated close to the basal lamina of fowl(Cooksey and Rothwell et al.,1973). Al-Tememy (2010) and Kannan et al. (2015) stated that the sertoli cells became evident in quails from the age of four weeks and located in between the spermatogenic cells. These were columnar cells with granular cytoplasm and transformed into stellate shaped sertoli cells from 5th weeks onwards. They also pointed that the nucleus was spherical or oval generally located in the broader of the cell and often deeply infolded cells were found with an exceptionally large nucleolus. In a publication they published that the seminiferous tubules are tightly packed in one month old duckling.(Webb et al.,1990). In our study it was observed that in group-II (Fig:8) and in group-III (Fig:9) spermatozoa were present in the lumen of seminiferous tubules. Elbajory et al. (2013) opined that in duck the sertoli cells were slender, elongated with irregular outline and spermatozoa were present in lumen of seminiferous tubules.



## **CONCLUSION**

The testes are located within the abdominal cavity caudal to the respective lungs on either sides of the vertebral column. The color of testes are yellowish in immature stage but gradually turns to white when becomes mature. The shape of testes are oval in all ages. The weight of testes gradually increases. Microscopically in group-I and group-II the spermatogenic cells were cuboidal and nuclei were dark and round. In group-III the spermatogenic cells were columnar and nuclei were oval. Spermatozoa were present in the lumen of group-III and few spermatozoa were present in group-II.

## **Limitations**

- Sample size was small.
- Limitation of time.

## REFERENCES

1. Al-Tememy, H. S. A. (2010). Histological study of testis in quail (*Coturnix coturnix japonica*). *Al-Anbar Journal of Veterinary Sciences*, 3(2), 36-44.
2. Aire, T. A., Ayeni, J. S., & Olowo-Okorun, M. O. (1979). The structure of the excurrent ducts of the testis of the guinea-fowl (*Numida meleagris*). *Journal of anatomy*, 129(Pt 3), 633.
3. Asaduzzaman, M., Salma, U., Ali, H. S., Hamid, M. A., & Miah, A. G. (2017). Problems and prospects of turkey (*Meleagris gallopavo*) production in Bangladesh. *Research in Agriculture Livestock and Fisheries*, 4(2), 77-90.
4. Babić, K., Vukičević, T. T., Mihelić, D., & Kantura, V. G. (2004, January). The anatomy of the female and male ostrich (*Struthio camelus*) reproductive system as a base of reproductive physiology. In *11th Ostrich World Congress*.
5. Cho, P., Brown, R., & Anderson, M. (1984). Comparative gross anatomy of ratites. *Zoo Biology*, 3(2), 133-144.
6. Cooksey, E. J., & Rothwell, B. (1973). The ultrastructure of the Sertoli cell and its differentiation in the domestic fowl (*Gallus domesticus*). *Journal of anatomy*, 114(Pt 3), 329.
7. Elias, M. Z. J., Aire, T. A., & Soley, J. T. (2007). Macroscopic features of the arterial supply to the reproductive system of the male ostrich (*Struthio camelus*). *Anatomia, histologia, embryologia*, 36(4), 255-262.
8. Elbajory, S. I. A., El Tingari, M. D., & Abdalla, P. A. (2013). Morphological study of the testis of adult Sudanese duck (*Anas platyrhynchos*). *International Journal of Animal and Veterinary Advances*, 5(3), 103-107.
9. Nickel, R., Schummer, A., & Seiferle, E. (1977). *Anatomy of the Domestic Birds*. Translated by: Siller WG.
10. Rajendranath, N., Rao, T. S., Kumar, D. P., Raghavendar, K. B. P., & Girishkumar, V. (2015). Gross anatomical studies on the testes of the Emu (*Dromaius novaehollandiae*). *Indian Journal of Poultry Science*, 50(2), 234-236..
11. Rischkowsky, B., & Pilling, D. (2007). *The state of the world's animal genetic resources for food and agriculture*. Food & Agriculture Org..

12. Grimes, J., Beranger, J., Bender, M., & Walters, M. (2007). How to raise heritage turkey on pasture. *American livestock Breeds conservancy Pittsboro, NC27312 USA. Headquarters*, 233.
13. Hopkins, B. A., & Constantinescu, G. M. (1995). Anatomy of ostriches, emus, and rheas. *The Ratite Encyclopedia (Drenowatz, C. ed.), Ratite Records, San Antonio*.
14. Hess, R. A., Thurston, R. J., & Biellier, H. V. (1976). Morphology of the epididymal region and ductus deferens of the turkey (*Meleagris gallopavo*). *Journal of Anatomy*, 122(Pt 2), 241.
15. Kannan, T. A., Ramesh, G., & Sivakumar, M. (2015). Age related changes in the gross and histoarchitecture of testis in Japanese quails (*Coturnix coturnix japonica*). *International Journal of Livestock Research*, 5(6), 26-33.
16. Kigir, E. S., Sivachelvan, M. N., Kwari, H. D., Sonfada, M. L., Yahaya, A., Thilza, I. B., & Wiam, I. M. (2010). Gross and Microscopic changes in the gonads of male and female domestic pigeon (*Columbia Livia*). *New York Science Journal*, 3(10), 108-111.
17. KIRBY, J. D. (2000). Reproduction in male birds. *Sturkie's avian physiology*.
18. Karki, M. (2005). Growth, Efficiency of Feed Utilization and Economics of Different Rearing Periods of Turkeys Mukesh Karki. *Nepal Agriculture Research Journal*, 6, 84-88.
19. Ogasawara, F. X., & Rooney, W. F. (1966). Artificial insemination and fertility in turkeys. *British poultry science*, 7(1), 77-82.
20. The Daily Star, 8 September 2020
21. Bangladesh Bureau statistics
23. Nestor, K. E., & Brown, K. I. (1968). Method and frequency of artificial insemination and turkey fertility. *Poultry science*, 47(3), 717-721
24. Yakubu, A., Musa-Azara, I. S., & Haruna, H. S. (2014). Village guinea fowl (*Numidia meleagris*) production systems in Nasarawa State, north central Nigeria: flock characteristics, husbandry and productivity. *Livestock Research for Rural Development*, 26(3).
25. Webb, D. M., & Van Vleet, J. F. (1990). Cystic testicular degeneration in furazolidone toxicosis of sexually immature ducks. *Avian diseases*, 693-700.

## **Acknowledgement**

The author takes the privilege to acknowledge the almighty “Allah”, who has given the opportunity to accomplish the production report.

The author would like to express his deep sense of gratitude and heartfelt appreciation to Professor **Dr. Abdul Ahad**, Dean, Faculty of Veterinary Medicine, Chattogram Veterinary and Animal Sciences University.

The author express his sincere gratitude, heartfelt respect and immense indebtedness to his supervisor **Dr. kh. Nurul Islam**, Professor, Department of Anatomy and Histology, Chattogram Veterinary and Animal Sciences University.

Finally the author extended his appreciation to his parents, and all well-wishers.

## Biography

Name	Md. Khirujjaman Sumon
Present status	Intern student in Chattogram Veterinary and Animal Sciences University.
Education back ground and year	SSC in 2011 with GPA-5 from Amanullah Adarso Bidha Nicaton.  HSC in 2013 with GPA-5 from Bogra Cantonment Public School and College.
Research interest	Microbiological research