

# **Determination of Anatomical morphology in turkey spp. (*Meleagris gallopavo*) for post mortem diagnosis with histomorphological characteristics of liver**



**A Clinical Report Submitted**

**By-**

**Argha Paul Shuvo**

**Intern ID: 36**

**Roll No: 15/38**

**Registration No: 01453**

The report submitted in the partial fulfillment of the requirements for the

Degree of

**Doctor of Veterinary Medicine (DVM)**

**Chattogram Veterinary and Animal Sciences University**

**Khulshi, Chittagong-4225, Bangladesh**

**September, 2020**

# **Determination of Anatomical morphology in turkey spp. (*Meleagris gallopavo*) for post mortem diagnosis with histomorphological characteristics of liver**



**Approved as to style and content by**

.....

**Signature of Author**

**Argha Paul Shuvo**

**Intern Doctor**

**Roll No: 15/38**

**Reg. No: 01453**

**Intern ID: 36**

.....

**Signature of supervisor**

**DR. Abdullah Al Faruq**

**Assistant Professor**

**Dept. of Anatomy & Histology**

**Faculty of Veterinary Medicine**

**CVASU**

**Chattogram Veterinary and Animal Sciences University**

**Khulshi, Chittagong-4225, Bangladesh**

## Table of Contents

<b>Acknowledgments</b> .....	i
<b>Abstract</b> .....	1
<b>Introduction</b> .....	2
<b>Materials and Methods</b> .....	5
1. Study area and study population .....	5
2. Study period.....	5
3. Pre-examination of the turkey before slaughtering .....	5
4. Collection of sample .....	5
5. Required Instruments .....	5
6. Required Media and reagents.....	5
7. Methods for studying Gross anatomy of the visceral organs.....	6
8. Collection of specimen .....	6
9. Processing of tissue.....	6
9.1 Killing.....	6
9.2. Fixation of Specimen .....	7
9.3. Tagging of Specimen .....	7
9.4. Washing of fixed tissue.....	7
9.5. Dehydration .....	8
9.6. Cleaning.....	8
9.7. Infiltration .....	9
9.8. Embedding.....	9
9.9. Sectioning .....	9
9.10. Floating of Section in Water Bath.....	9
9.11. Attaching of Section on Glass slide .....	9
9.12. Drying.....	10
9.13 .Staining.....	10
9.14 . Mounting.....	11
10. Histomorphology .....	11

<b>Results</b> .....	12
Gross structures .....	12
Body weight.....	12
Proventriculus .....	12
Quantitative anatomical features of turkey.....	13
Proventriculus-gizzard junction .....	14
Liver .....	14
Cecum.....	15
Histology of liver.....	18
<b>Discussion</b> .....	22
<b>Conclusion</b> .....	25
<b>References:</b> .....	26
<b>Biography</b> .....	29
<b>My Goal</b> .....	30

## Acknowledgments

---

The author wishes to acknowledge the immeasurable grace and profound kindness of Almighty, the supreme authority and supreme ruler of universe, who empowers the author to handle the case and to complete the case report successfully.

Completion of any work or responsibility gives nice feelings. But the accomplishment of this work, as the partial fulfillment of the requirements for the degree of Doctor of Veterinary Medicine (DVM) in (CVASU) , not only has given me the pleasure but also have given me the confidence to move ahead and showed me a new opening to knowledge. Standing at this opening, it is an honor to revoke the names of the person and the Organization I am grateful to.

The author wishes to express his deep sense of gratitude and thanks to **DR. Abdullah Al Faruq**, assistant professor, Department of Anatomy and Histology, Faculty of Veterinary Medicine of Chattogram Veterinary and Animal Sciences University for his skillful supervision and guidance to make this report

The author would like to express his deep sense of gratitude and thanks to **Prof. Dr. Gautam Buddha Das**, honorable vice chancellor and **Prof. Dr. Md. Abdul Ahad**, Dean, Faculty of Veterinary Medicine, CVASU.

The author would like to thank to the Director of External affairs, **Prof. Dr. A.K.M. Saifuddin**, Dept. of Physiology, Biochemistry and Pharmacology, Chattogram Veterinary and Animal Sciences University

Finally the author expresses thanks and warmest sense of gratitude to his parents and all well-wishers.

**Argha Paul Shuvo**

(The author)

September,2020

---

# **Determination of Anatomical morphology in turkey spp.(*Meleagris gallopavo*) for post mortem diagnosis with histomorphological characteristics of liver**

## **Abstract**

---

The study was aimed to investigate the anatomical (body weight, proventriculus, proventriculus-gizzard junction, liver and cecum) and histological (liver) features of the turkey to identify the gross and histomorphological characteristics for post mortem diagnosis of disease. The study was carried out in 20 turkeys and categorized them on the basis of their age and sex. The average body weights of male and female were found  $3.55 \pm 0.034$  kg and  $2.75 \pm 0.05$  kg. In male, the average length, width and diameter of proventriculus were  $5.16 \pm 0.033$  cm,  $2.13 \pm 0.044$  cm,  $3.59 \pm 0.027$  cm, average length, width and diameter of proventriculus-gizzard junction were  $1.81 \pm 0.036$  cm,  $0.87 \pm 0.036$  cm and  $2.32 \pm 0.041$  cm and length, width and diameter of cecum were  $22.81 \pm 0.204$  cm,  $1.13 \pm 0.042$  cm and  $3.9 \pm 0.039$  cm where in female the average length, width and diameter of proventriculus were  $2.76 \pm 0.043$  cm,  $1.87 \pm 0.422$  cm,  $3.25 \pm 0.045$  cm, average length, width and diameter of proventriculus-gizzard junction were  $1.22 \pm 0.055$  cm,  $0.91 \pm 0.052$  cm and  $3.23 \pm 0.051$  cm and length, width and diameter of cecum were  $21.24 \pm 0.047$  cm,  $1.17 \pm 0.042$  cm and  $3.14 \pm 0.052$  cm. The internal surface of proventriculus was found reddish in color. The membrane of pair ceca was found greenish and membrane wall was found thick to thin according to the segments of ceca. The gross feature of liver in turkey was dark brown in color and the average weight of the liver in male was  $50.66 \pm 0.030$  gm while in female was  $59.37 \pm 0.102$  gm. Histological features revealed that liver of turkey were consists of parenchyma and stroma under microscope. Hepatocyte, central vein, hepatic sinusoids and portal triad are the main histological features of turkey liver. These prominent anatomical and histological features of several internal organs of turkey will be effective for post mortem diagnosis and treatment of turkey and it will helps to differentiate in diagnosis among contagious diseases of turkey.

---

**Key words:** Anatomy, Histology, Turkey, Proventriculus, Cecum, Sinusoid, Portal triad.

## Chapter 1

### Introduction

---

Poultry generally is referred to all domestic birds raised by man for the production of eggs, meat and other benefits for human consumption. The domestic birds include chicken, duck, turkey, guinea fowl and geese. From the last decade, demand for poultry products has been increased rapidly in Bangladesh, Experience shows that climate of Bangladesh is convenient to rear different poultry species (Islam, 2003). Broiler and layer chicken, duck and pigeon are very common in our country for the major source of poultry protein. Poultry meat alone contributes 37% of the total meat production in Bangladesh (Begum et al., 2011). In fact, poultry keeping is an integral part of the rural household that provides family income for the small, marginal and landless poor. The farmers who cannot afford to rear cattle and goat can easily rear poultry. However, among the livestock sector, the poultry industry (specially, commercial broiler and layer) is in the line to be destroyed due to severity of avian influenza (bird flu). Thus, it is crying need to search the alternative protein source to meet up the increasing demand (Asaduzzaman et al., 2017). In order to maximize food production and meet protein requirements in developing countries, variable options need to be explored and evaluated (Owen et al., 2008).

Turkey meat may be one of the best options for alternative protein source in Bangladesh. Turkey production is an important and highly profitable agricultural industry with a rising global demand for its products (Yakubu et al., 2013), and they are adaptable to wide range of climatic conditions (Onwumere and Obasi, 2010). The protein, lipid carbohydrate and mineral content of turkey egg are 13.1%, 11.8%, 1.7% and 0.8%, respectively. The cholesterol content is 15.67-23.97 mg/g of yolk. Turkey meat also has high nutritional and sensorial properties which make it almost ideal raw material for rational and curative nutrition. People prefer turkey meat because of its leanest nature. The protein, fat, and energy contents of turkey meat are 24%, 6.6%, 162 Calories per 100 g of meat. Mineral like potassium, calcium, magnesium, iron, selenium, zinc and sodium are also present in turkey meat. It is also rich in essential amino acids and vitamins



such as B3 (niacin), vitamin B6 and B12, unsaturated fatty acids and essential fatty acids, and low cholesterol contents.

Turkey is an excellent insect forager and most crops that are troubled by insect population including vegetables are candidates for insect control by turkeys (Yassin et al., 2013). Turkey thrives better under arid conditions, tolerates heat better, ranges farther and has higher quality meat (Yakubu et al., 2013). But turkey production has not been fully exploited in Bangladesh including other developing countries despite its huge potential over other poultry species due to lack of some anatomical knowledge which are helpful for turkey disease diagnosis by post mortem analysis.

Now a day turkey rearing is also getting popularity all over the country. Lots of veterinarians are regularly diagnoses the disease of chicken, duck and pigeon based on post mortem analysis. Therefore the number of their industry is increasing day by day by getting proper treatment. A large number of papers, books, and other information are available, regarding the normal anatomy of important visceral organs of chicken, duck and pigeon all over the world including Bangladesh. This information is helping to diagnose the diseased birds by post mortem and to give proper treatment. The morphology of proventriculus is important for diagnosis of Newcastle disease of poultry, proventriculus-gizzard junction morphology is important for diagnosis of Infectious bursal disease and Newcastle disease of poultry, cecum morphology is important for diagnosis of Newcastle disease and Necrotic enteritis disease of poultry, liver morphology and histomorphology is important for diagnosis of salmonellosis, fowl typhoid, colibacillosis and lymphoid leukosis disease of poultry. Although all the information is important to differentiate normal morphology of the organs from pathological conditions but there is no such information is available for turkey spp. in our country and very few all over the world (available for other poultry species) which is very much important for post mortem analysis in turkey disease diagnosis. The findings will benefit the turkey farmer to get proper diagnosis and treatment for their turkey which will improve the production and reduce the mortality rate.

Farmers are rearing turkey as an ornamental bird with a limited extent without having prior experience. Mainly interested farmers started turkey farming by importing day-old turkey chicks (Poult) from neighboring country, India or from some of our local turkey farm hatchery. So, it

may have high potential for production and marketing in Bangladesh (Asaduzzaman et al.,2017). However, there is scanty study conducted previously regarding turkey anatomy all over the world but some of the visceral organs anatomy is very much important to know for post mortem of turkey spp. regarding disease diagnosis like chicken, duck, pigeon and other common poultry spp. (Morrow et al., 2008; Ahmed et al., 2009) .Therefore, the study has been aimed to determine the Anatomical morphology in some important visceral organs (Proventriculus, proventriculus-gizzard junction, cecum and liver) in turkey spp. with histomorphological characteristics of liver for post mortem diagnosis of turkey disease.

### **Aims and Objectives of the study:**

1. The aim of the study is to determine the Anatomical morphology of some important visceral organs (Proventriculus, proventriculus-gizzard junction, cecum and liver) in turkey spp. for post mortem diagnosis of disease.
2. Histomorphological characteristics of liver for post mortem diagnosis of disease.

## Chapter 2

# Materials and Methods

---

### **1. Study area and study population**

The study was done in Chattogram area of Bangladesh. On the basis of age, Twenty turkey (10male +10female) were collected from different turkey farm in Chittagong.

### **2. Study period**

The sample was collected from August to January through 6 months of time and delivered the sample to the anatomy and histology laboratory of Chattogram Veterinary and Animal Sciences University (CVASU).

### **3. Pre-examination of the turkey before slaughtering**

All turkeys were apparently healthy and disease free. Turkeys were collected from different flocks of the farm. All the clinical examination were conducted properly and no abnormalities were found during clinical examination.

### **4. Collection of sample**

The sample was collected on different days and gross observation of the visceral organs were observed on same day. After routine slaughtering, important visceral organs were observed properly to see the normal size, shape, appearance, color, consistency and weight. All the measurement were taken like length, width and diameter at the same time. The liver sample was taken to the 10% formalin and stored for histology. For histology of liver, a procedure of making permanent slide is ongoing at the laboratory of anatomy and histology department of CVASU.

### **5. Required Instruments**

Scissors, Scalpel handle, Scalpel blade, Pencil scale, Tray,, Large beaker, Electric balance, Small beaker, Plastic bag, Pencil, pen, scalpel, knife, Scale, Gloves, etc.

### **6. Required Media and reagents**

Distilled water, 10% buffered formalin, staining agents.

## **7. Methods for studying Gross anatomy of the visceral organs**

In the laboratory, the visceral organs were cleaned and dissected the organs to remove from the body. First, we took the external measurements (length,width, and external diameter) of the visceral organs (liver,proventricuus, proventriculus-gizzard junction,cecum) and they were sectioned longitudinally and the internal materials were taken out. The internal condition of the visceral organs observed. The visceral organs were of tukeys were categorized on the basis of age. All things were done with proper hygienic management.

## **8. Collection of specimen**

Tissue samples (approximately 10mm×5 mm) were obtained from the sample of liver with a very sharp scalpel. Five pieces of sample were taken from each group for histological study.

## **9. Processing of tissue**

### **9.1 Killing**

It is the first step in the preparation of permanent mounts and is of prime importance. By killing we mean the instantaneous stoppage of all the activities of life in their respective original state without giving the tissue enough opportunity to undergo any post-mortem changes. This can only be achieved by not allowing any change in the form of the tissue through use of reagents which are quick acting.

### **Process of Killing**

A few drops of ether or absolute alcohol are placed on the slide over the object (material) and are allowed to evaporate.

## **9.2. Fixation of Specimen**

The tissue segments were immersed in Bouin's solution for a period of 1 hour for prefixation and then large piece of tissue were trimmed into smaller size. Then it was immersed in neutral buffered formalin for a period of 72 hours for completing fixation.

### **The various important fixing agents**

- (1) Bouin's fluid,
- (2) Mercuric chloride,
- (3) 70% Alcohol,
- (4) Acetic acid,
- (5) Formaline (formaldehyde),
- (6) Potassium dichromate and
- (7) Osmic acid (osmium tetra-oxide).

## **9.3. Tagging of Specimen**

Individual segments were tagged with tag paper using thread and needle by mentioning their name. The tag paper were previously made and paraffinized for less destruction with the touch of alcohol and water.

## **9.4. Washing of fixed tissue**

After 72 hours of fixation the desired tissue specimen were washed into running tap water for 2 hours. It was done to prevent any unexpected interference with subsequent processes as it helps to remove excess fixative from tissue samples.

## Various mediums used for washing

- (1) 70% Alcohol (for Bouin's)
- (2) Iodine+ 70% alcohol, (for mercuric chloride)
- (3) 50% alcohol (for acetic acid)

## 9.5. Dehydration

To remove water content from tissue samples dehydration was performed through passing of tissue sample into successive ascending concentration of alcohol (Photograph). It was done in following manner:

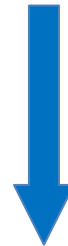- 50% Alcohol for 2 hours
- 60% Alcohol for 2 hours
- 70% Alcohol for 2 hours
- 80% Alcohol for 2 hours
- 90% Alcohol for 2 hours
- 95% Alcohol for 2 hours
- 100% Alcohol for 2 hours



## 9.6. Cleaning

After completion of dehydration, the tissue specimens were passed through successive changes of Xylene until the alcohol from the tissue was replaced. This processing was performed in following sequences:

- Alcohol (50%) + Xylene (50%) for 12 hours/ overnight
- Xylene (100%) for 2 hours
- Xylene (100%) for 2 hours



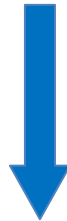## 9.7. Infiltration

When the tissue samples become clearly transparent, i.e. cleaning was completed by Xylene, the specimen were placed into melted paraffin in the oven at (58-60) °C to evaporate the Xylene and the tissue space were infiltrated with melted paraffin. Following different graded paraffin was used:

Paraffin (50%) + Xylene (50%) for 2 hours

Paraffin (100%) at 60°C for 2 hours

Paraffin (100%) at 60°C for 2 hours



## 9.8. Embedding

After completion of infiltration, the tissue samples were placed in between two L-shaped angles and it was filled with melted paraffin for making paraffin block. Then it was allowed for hardening of paraffin block.

## 9.9. Sectioning

Then the paraffin block was mounted on the object holder, cleaned of excess paraffin and clamped in the block holder on the microtome, adjusting the knife clamp toward the paraffin block and slowly beginning of the sectioning. The paraffin block with tissue was cut at 6 µm thickness using sliding microtome machine with the help of disposable Carbon blade. Only the transverse sections were taken for the study.

## 9.10. Floating of Section in Water Bath

After sectioning the ribbons like sections were floated in Luke warm water bath for stretching below melting temperature (60<sup>0</sup>c) of paraffin. Luke warm water was treated with gelatin as adhesive medium.

## 9.11. Attaching of Section on Glass slide

The well spread ribbons of sections from water bath were transferred on glass slides which was labeled by diamond pencil as labeled with tag.


## 9.12. Drying

Then the slide was dried on warmer machine for few minutes and then allowed for air drying for a period of 12 hours before staining. From the dryer machine the slides were transferred into a temporary slide box before staining. The slides were transferred from dryer machine after 12 hours from starting of drying. The temperature of the dryer machine was 37<sup>0</sup>C.2.7.2.14.

## 9.13. Staining

The tissues were stained with Hematoxylin and eosin for visualization under the light microscope. Following protocol was followed for staining (Gridley and Francis, 1960).

Treatment	Time
100% Xylene-1	2 min
100% Xylene-2	2 min
100% Alcohol-1	2 min
100% Alcohol-2	2 min
95% Alcohol	2 min
70% Alcohol	2 min
Tap Water	2 min
Hematoxylin	10-15 min
Running tap water	2 min
1% Acid alcohol	1-2 short dips
Tap water	5 min
Ammonium water	5-10 min
Running tap water	5-10 min
1% Eosin	2-4 min
70% Alcohol	30 seconds
95% Alcohol	2 min
100% Alcohol-1	2 min
100% Alcohol-2	2 min
50% Alcohol+50% Xylene	2 min
100% Xylene-1	2 min
100% Xylene-2	2 min





### 9.13 . Mounting

After staining the tissue sections with glass slide were protected by thin cover slip attached to the slide with “Canada Balsam” as mounting medium. Mounted slides were allowed to harden.

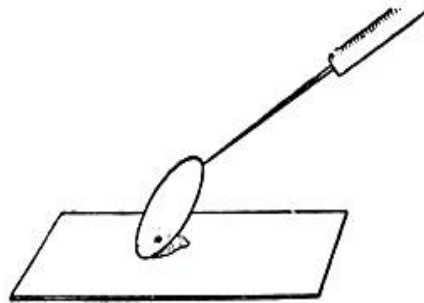


Fig. 41. METHOD OF HOLDING THE  
COVERSLIP ON SLIDE,



Fig. 42. METHOD OF PUTTING  
THE COVERSLIP

## 10. Histomorphology

Histomorphological Studies were carried out by using Hematoxylin and Eosin and Verhoeff Van geison staining with light microscope at (4x, 10x, 20x and 100x) magnifications.

## Chapter 3

### Results

---

Anatomical features such as body weight, length, width and diameter of proventriculus, proventriculus-gizzard junction, cecum and the weight of liver were measured on 20 turkeys among them ten were male and ten female. All parameters of the result were found significant. The following results were observed during investigation.

#### Gross structures

##### Body weight:

The study revealed that, the average body weight of turkey in male was  $3.55 \pm 0.034$  kg while in female was  $2.75 \pm 0.05$  kg. In male, the highest body weight was 3.7 kg while the lowest was 3.4 kg. On the other hand, the highest body weight in female was 3 kg while the lowest was 2.5 kg. It represents that male body weight were heavier than that of female.

##### Proventriculus:

Proventriculus or glandular stomach of turkeys were elongated spindle shape organ. It was extended in male approximately between levels of fifth thoracic to third lumbrosacral vertebrae and in female approximately between fourth to seventh thoracic vertebrae. The wall of the glandular stomach was thicker than that of the esophagus. Internal surface was reddish. There were many number of glands in proventriculus which functions are to produce acid and proteolytic gastric juice. The average length of proventriculus in male and in female were  $5.16 \pm 0.033$  cm and  $2.76 \pm 0.043$  cm respectively that has been shown in table. The highest length of proventriculus in male was 5.3 cm while the lowest was 5 cm. The highest length of proventriculus in female was 3cm while the lowest was 2.6 cm. It represents that male proventriculus were longer than that of female.

**Table 1: Quantitative anatomical features of turkey**

Parameter	Sex	Observation	Mean±S.E.	P value
Body weight(gm)	M	10	3.55±0.034	S
	F	10	2.75±0.05	
Proventriculus(length)	M	10	5.16±0.033	
	F	10	2.76±0.043	
Proventriculus(width)	M	10	2.13±0.044	
	F	10	1.87±0.422	
Proventriculus(diameter)	M	10	3.59±0.027	
	F	10	3.25±0.045	
Proventriculus-gizzard junction(length)	M	10	1.87±0.036	
	F	10	1.22±0.055	
Proventriculus-gizzard junction(width)	M	10	0.87±0.036	
	F	10	0.91±0.052	
Proventriculus-gizzard junction(diameter)	M	10	2.32±0.041	
	F	10	3.23±0.051	
Liver(weight)	M	10	59.37±0.102	
	F	10	50.66±0.033	
Cecum(length)	M	10	22.81±0.204	
	F	10	21.24±0.041	
Cecum(width)	M	10	1.13±0.042	
	F	10	1.17±0.042	
Cecum(diameter)	M	10	3.9±0.039	
	F	10	3.14±0.052	

\* M= male,F= female,S.E. =Standard error,S=Significant

Average width of proventriculus in male and in female were 2.13±0.044 cm and 1.87±0.422 cm. The highest width of proventriculus in male was 2.4 cm and the lowest was 2 cm. On the other hand, the highest width of proventriculus in female was 2 cm and the lowest was 1.7 cm. It was also found that the average diameter of proventriculus in male and in female were 3.59±0.027 cm and 3.25±0.045 cm respectively according to table. The highest diameter of proventriculus in male was 3.7 cm and the lowest value was 3.5 cm. In female, the highest diameter of proventriculus was 3.7 cm while the lowest was 3 cm. From these results, it represents that both width and diameter of proventriculus in male were longer than those of female.

### **Proventriculus-gizzard junction:**

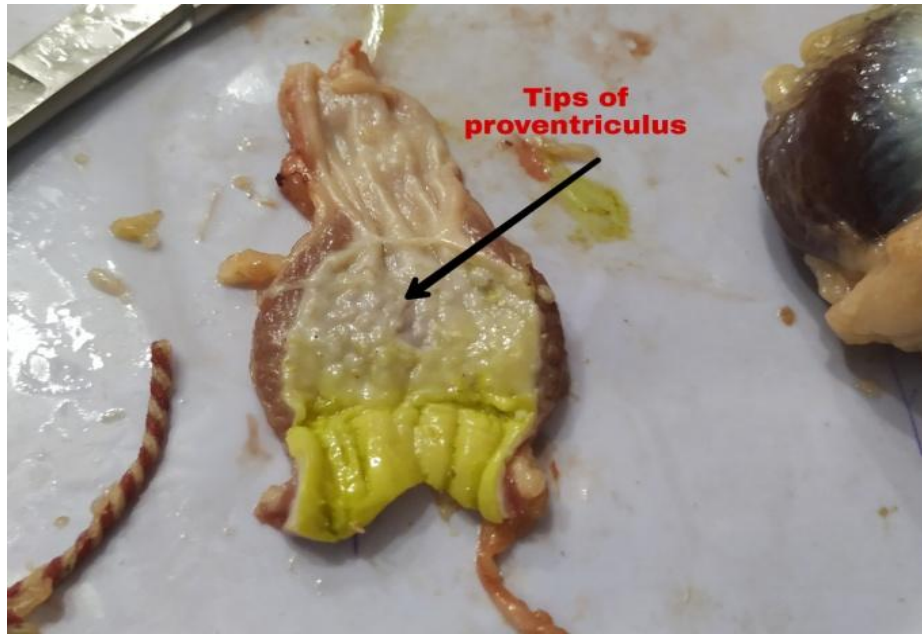
The junction between glandular stomach (proventriculus) and muscular stomach (gizzard) was situated caudally to the proventriculus which was a constricted portion and light yellow in color, a coat of yellowish mucous were covered the surface. The average length, width, diameter of the proventriculus-gizzard junction in male were  $1.81\pm 0.036$  cm,  $0.87\pm 0.036$  cm and  $2.32\pm 0.041$  cm while in female were  $1.22\pm 0.055$  cm,  $0.91\pm 0.052$  cm and  $3.23\pm 0.051$  cm respectfully according to table. In male, the highest length, width and diameter of the proventriculus-gizzard junction were 2 cm, 1 cm and 2.5 cm while the lowest were 1.7 cm, 0.7 cm and 2.1 cm. On the other hand, in female, the highest length, width and diameter of proventriculus-gizzard junction in female were 2 cm, 1.1 cm and 3.5 cm while the lowest length, width and diameter of proventriculus-gizzard junction were 1 cm, 0.6 cm and 3 cm respectively. It represents that length, width and diameter of proventriculus-gizzard in male were more than that of female.

### **Liver:**

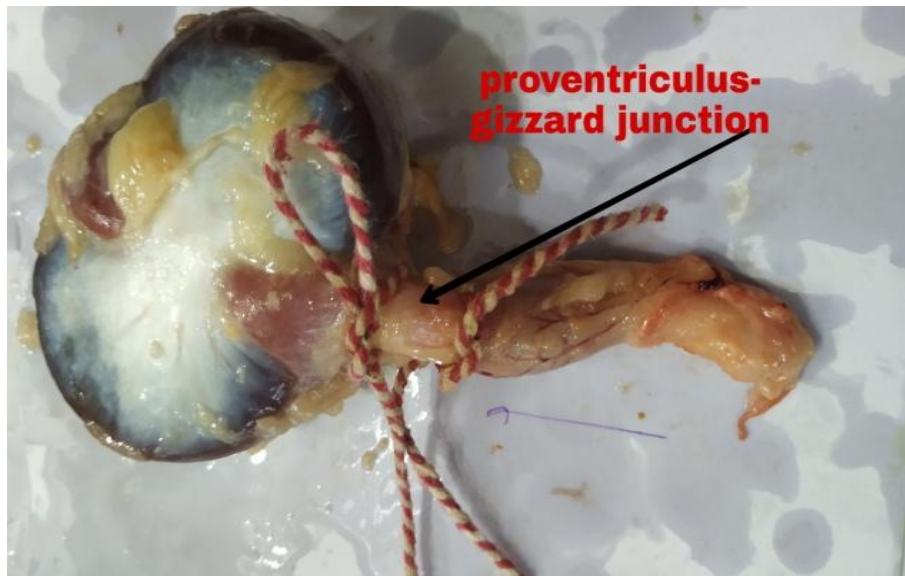
The liver of turkey was laid ventrally and posterior to the heart and was closely associated with proventriculus and spleen that was dark brown in color in fresh condition. The liver comprised two separate lobes-left and right lobes which were join cranially in the midline. The lobes were situated at the floor of the abdominal cavity. The cranial ends of the lobes were very close to the heart. The left lobe was prismshaped and smaller than the right lobe. The right lobe was somewhat heart shaped. The liver was slightly more caudally situated in the male than in that of female. The parietal surfaces were convex and the visceral surfaces were concave. The gall bladder lied on the right lobe beneath the spleen. It was found that the average weight of the liver in female was  $50.66\pm 0.030$  gm. while in male was  $59.37\pm 0.102$  gm. The highest weight of liver in female was 50.8 gm while the lowest was found 50.5 gm. In male, the highest weight of liver was found 59.8 gm while the lowest was found 59.1 gm. It represents that the weight of liver in male was heavier than that of female.

## Cecum


Pair ceca was found in turkeys which was the part of large intestine. Each cecum had proximal, middle and distal part. The short light red proximal part had a narrow lumen and a relatively thick wall. The middle part was long, bluish green to gray-green in color, wider and wall was thinner. The short light red distal part was expanded with a pointed extremity. The lumen of each cecum was mostly wider than in other parts of the intestinal tract. The wall of the each cecum was thinner than in other parts of the intestinal tract. The internal surface of the cecum were blackish white in color in normal condition. The wall contained lymphoid tissue mostly at the proximal part that was known as cecal tonsil. The average length, width and diameter of cecum in male were  $22.81\pm 0.204$  cm,  $1.13\pm 0.042$  cm and  $3.9\pm 0.039$  cm while in female were  $21.24\pm 0.047$  cm,  $1.17\pm 0.042$  cm and  $3.14\pm 0.052$  cm respectively. The highest length, width and diameter of cecum were 24 cm, 1.3 cm and 4.1 cm in male while the lowest length, width and diameter of cecum were 22 cm, 0.9 cm and 3.9 cm respectively. In female, the highest length, width and diameter of cecum were 21.5 cm, 1.4 cm and 3.4 cm while the lowest length, width and diameter of cecum were 21 cm, 1 cm and 2.9 cm respectively. It represents that the length, width and diameter of cecum in male were longer than that of female.



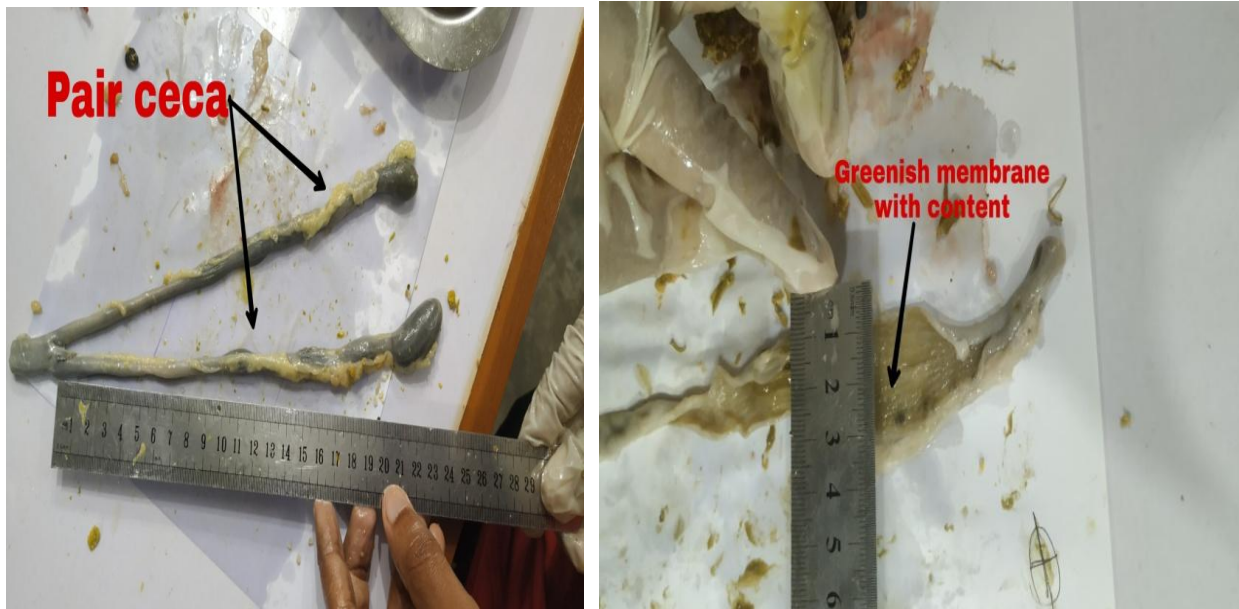**Tips of proventriculus (M)**



**Provrntriculus- gizzard junction (F)**



**Lobes of liver (F)**



**Pair ceca with greenish membrane (M)**

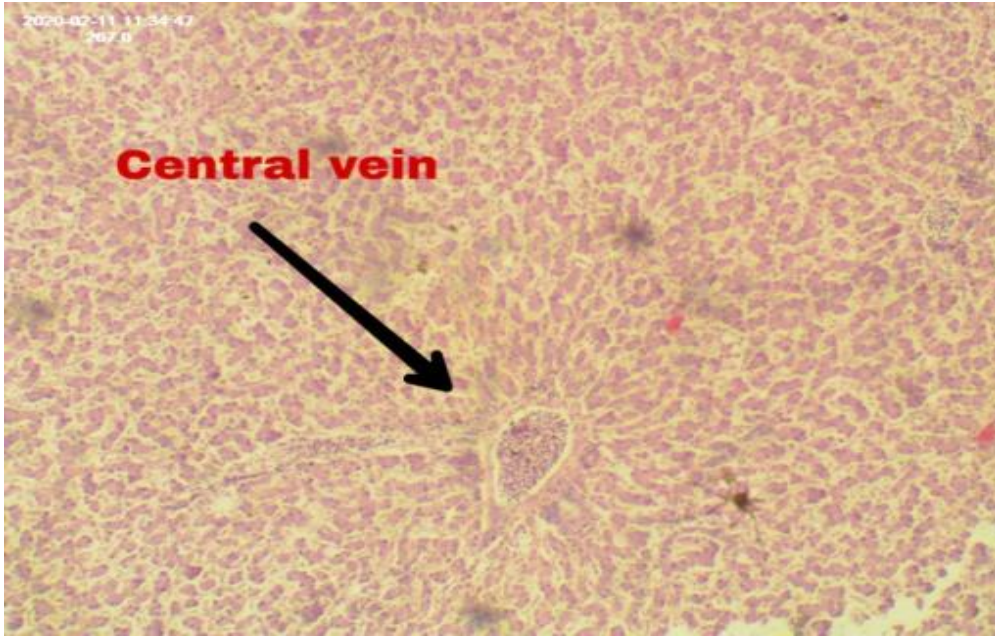
\* M= male, F= female

**Figure: Anatomical Morphology Of Turkey**

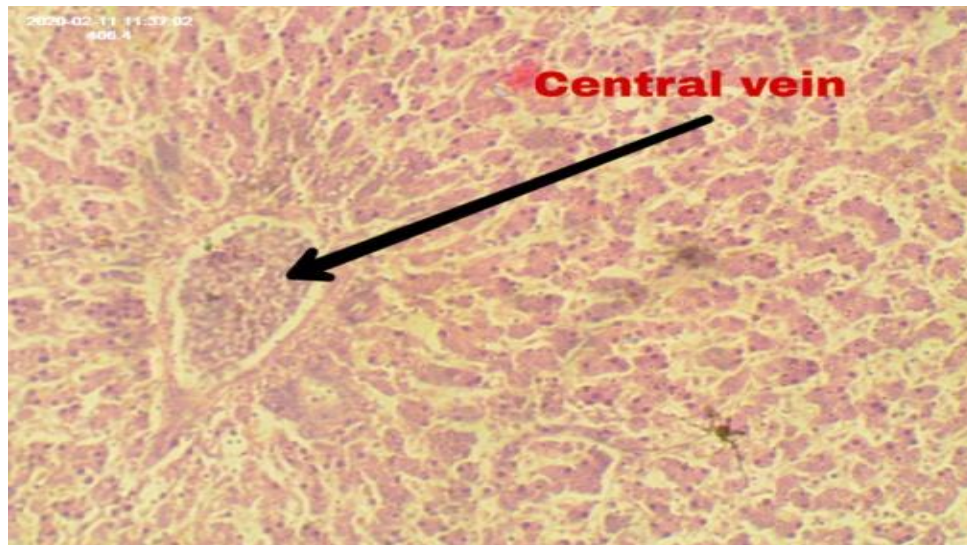
## **Histology of liver**

Histologically, liver had a complex microscopic structure that were viewed from different angles. It comprised of two major histological components, (1) parenchyma which was represented by hepatocytes and (2) stroma which comprised of connective tissue and contained vessels. The main structural and functional component of liver is hepatocytes. Hepatocytes were polyhedral cells having one or two spherical nuclei with well developed nucleoli. Under microscope, liver lobule was hexagonal in shape that formed the structural unit of liver. It had a vein at the the centre called central vein. The hepatic cells were arranged in cords in a radiating manner from the central vein and hepatic sinusoids traveled between the strips of hepatocytes, draining into the central vein. The irregular spaces between the hepatic plates were occupied by liver sinusoids which were lined by discontinuous endothelial cells. Some of the endothelial cells were modified to become phagocytic cells called kupffer's cells. The portal tract contained three structures, namely, a portal venule, hepatic arteriole and a small hepatic ductule. These three structures of the portal tracts are referred to as portal triad

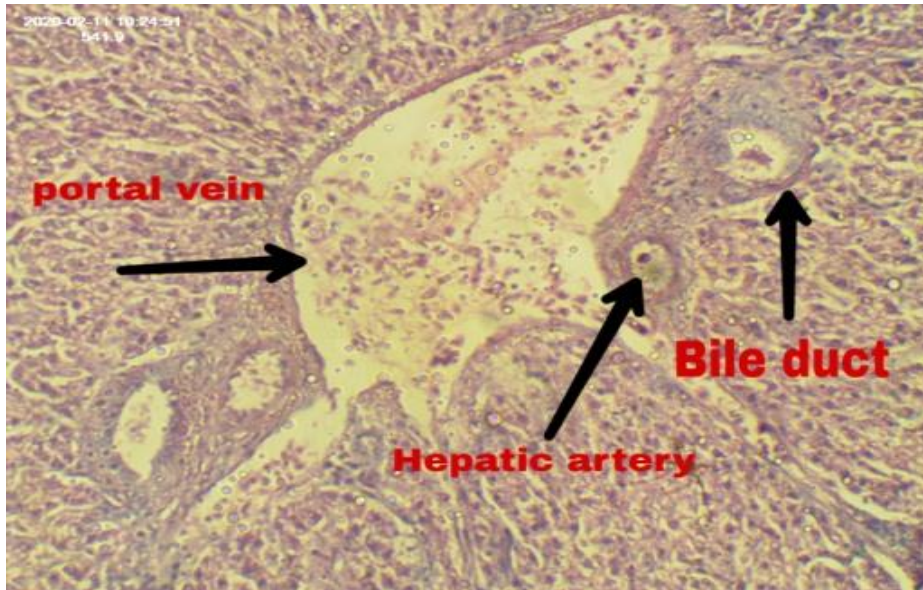




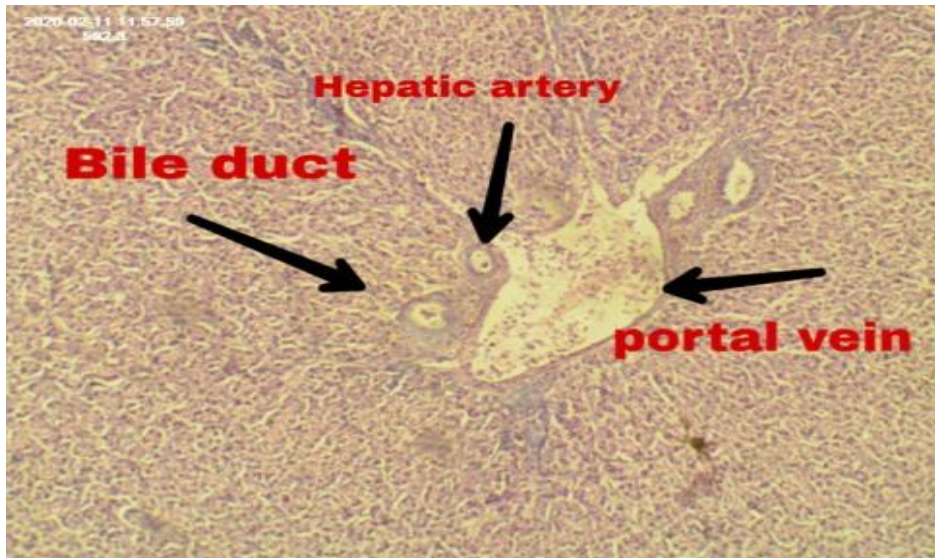
**Central Vein 10x (M)**



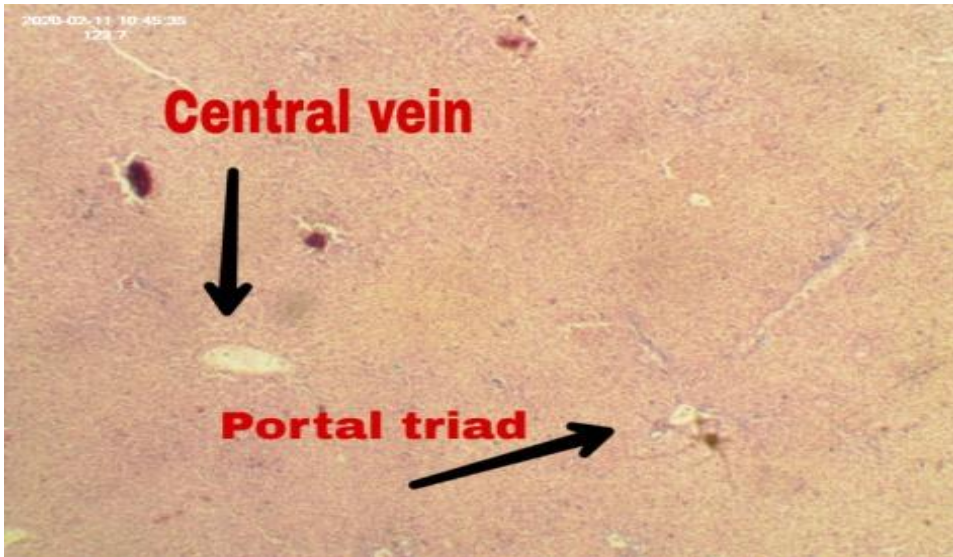
**Central Vein 20x (F)**



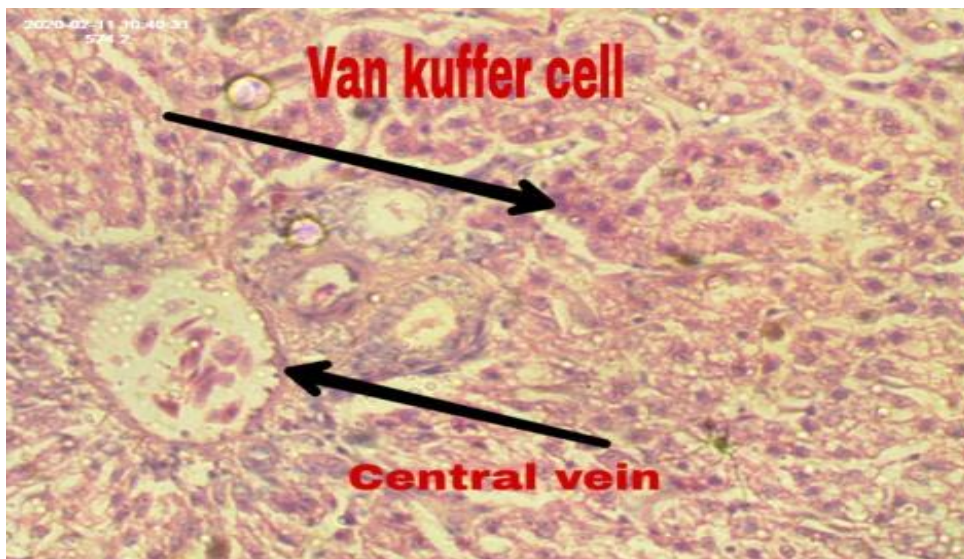
**Portral triad 20x (M)**



**Portral triad 10x (F)**



**Central vein & Portral triad 10x (M)**



**Central vein & Van Kuffer Cell 40x (F)**

\* M= male, F= female

**Figure : Histology of liver in different foci**

## Chapter 4

### Discussion

---

The study revealed that, average body weight of male and female turkey was 3.55 kg and 2.75 kg. The average body weight of male and female turkey were found 2.36kg and 1.90kg in a turkey farm of Tamilnadu, India at the age of 8<sup>th</sup> week (Venkatesakumar et al., 2018). This difference might be for age variation or dietary nutrition variation.

Average length of glandular stomach of turkey in male and female were 5.16 cm and 2.76 cm where width in male and female were 2.13 cm and 1.87 cm. The glandular stomach of domestic fowl and turkey has a length of 5 cm and a width at its widest part of 1.5 cm (McLeod, 1939; Malewitz and Calhoun, 1958). In another study showed glandular stomach has a length of 6.25 cm in the male and 5.25 cm in the female turkey (Marsden, 1940). It represents a little variation was found with the previous studies of proventriculus in turkey. The internal surfaces of proventriculus were found reddish in color. Negative response abnormalities were found in the glandular mucosa of proventriculus where a group of longitudinally arranged multi rowed crater like holes contained by deep proventricular glands. In previous study represents most of the internal surface of proventriculus of turkey was reddish in color and contained longitudinally arranged multi-rowed crater like hole containing deep gland in mucosa of proventriculus (Malewitz and Calhoun, 1958; McLelland, 1990). However, in post mortem lesion of Newcastle Disease (ND), pin point hemorrhages are commonly found in the gland tips of proventriculus in case of chicken (Hasan et al., 2010; Gowthaman et al., 2013) and petechial glandular hemorrhages are commonly found surrounding the base of each proventricular glands, heart and intestine in Salmonellosis and Avian Influenza (Bird flu) infection of chicken (Haider et al., 2004; Jones and Swayne, 2004; Rahman et al., 2004).

The average length, width, diameter of the proventriculus-gizzard junction in male were  $1.81 \pm 0.036$  cm,  $0.87 \pm 0.036$  cm and  $2.32 \pm 0.041$  cm while in female were  $1.22 \pm 0.055$  cm,  $0.91 \pm 0.052$  cm and  $3.23 \pm 0.051$  cm. There are some study about morphometry of turkey

digestive system (McLeod, 1939; Gowthaman et al., 2013) but none of them did not mention about the length, width and diameter of proventriculus-gizzard junction. According to size and weight it can be say that the length, width and diameter of proventriculus-gizzard junction will be smaller in domestic fowl then turkey. The junction between glandular stomach (proventriculus) and muscular stomach (gizzard) was light yellow in color, a coat of yellowish mucous were covered the surface. There were no papillae and plicae were found in the mucosa of proventriculus and gizzard junction area but it was more prominent in the mucosa of proventriculus. It was found similarity with some previous studies (McLeod, 1939; Malewitz and Calhoun, 1958). However, hemorrhage in the mucosa of junction between proventriculus and gizzard is the common postmortem findings for the chicken (Hasan et al., 2010).

Pair ceca had proximal, middle and distal part with wide lumen and thicker wall containing mucosa of bluish green, gray-green or blackish white in color in normal condition. Cecal tonsil remains in the proximal part. In case of some other domestic poultry species ceca is also divided into left and right as paired and it had also three segments per part like proximal, middle and distal containing more narrow lumen inside with thin wall, containing bluish green colored mucosa compared with turkey (Malewitz and Calhoun, 1958; Kausar et al., 2016). The present study represents more or less similar results compared with other study regarding ceca of other poultry species. The average length, width and diameter of cecum in male were  $22.81 \pm 0.204$  cm,  $1.13 \pm 0.042$  cm and  $3.9 \pm 0.039$  cm while in female were  $21.24 \pm 0.047$  cm,  $1.17 \pm 0.042$  cm and  $3.14 \pm 0.052$  cm respectively. The length of each cecum was 14 cm to 20 cm in some other domestic species of poultry (Kausar et al., 2016) which indicate length of turkey ceca is longer than others. No abnormalities were found in the ceca of turkey during investigation. However, granuloma with ruptured ceca in *E.coli* infection (Morishita and Bickford, 1992), flecks of blood in necrotic enteritis (Long et al., 1974), hemorrhage in ceca and cecal tonsil in ND (McLelland, 1990), profound mucus in the intestine in IBD (Zelege et al., 2005), distended ceca and filled with watery yellow-brown contents having a fetid odor and small petechial hemorrhage are commonly found in many other infectious diseases (Beasley et al., 1997; Jones and Swayne, 2004; Rahman et al., 2004).

The liver of turkeys was dark brown in color in fresh condition and firm to touch. The average weight of the liver in male was 50.66 gm while in female was 59.37 gm. The liver was dark

brown and weight of the liver was 33.9 gm to 55.5 gm in hatching age to maturity in other species of poultry (Latimer, 1925; Musalrz et al., 2006). The results indicate liver of turkey is larger than other domestic species of poultry. The structures of liver, lobes, position of gall bladder were found similarity with previous study (Getty and Sisson, 1975; Ghosh, 1998). All the livers were found normal in color and appearance during the present study findings on the other hand, granuloma found in liver in *E.coli* infection in domestic fowl (Morishita and Bickford, 1992), contain multiple small focal areas of coagulative necrosis in liver of acute fowl cholera infected turkey (Rhoades, 1964), irregular grayish yellow or grayish white nodules in liver in Marek's disease (Bhutia and Singh, 2017), necrotic and vascular congestion associated with green discoloration in liver in septicemic staphylococcal infection (Cervantes et al., 1988), pale friable and swollen liver with petechial or ecchymotic haemorrhages of liver in adenovirus infection are commonly found (Cheema et al., 1989).

Microscopically liver of turkey was less lobulated than that of other domesticated animals and interlobular septa was less distinct (Madhan and Raju, 2014). Liver were easily distinguished by parenchyma tissue and stroma. The liver parenchyma had a tubular arrangement in cross section, and appeared plate-like in longitudinal section. It was found similarity with some previous findings of turkey liver histology (Malewitz and Calhoun, 1958). Dense areolar connective tissue was observed around blood vessels, and in the thin capsule of glisson surrounding the liver. Central veins were lined with thin endothelium, and prominent sinusoids entered into them. Endothelial cells were also lined the sinusoids, and Von Kupffer cells were distinct. The portal canal contained the portal vein, hepatic artery, bile ducts and lymphatics. The microscopic result of the present study especially the arrangement pattern of different cells in liver was same like other domesticated fowl (Malewitz and Calhoun, 1958; Dellmann and Brown, 1976; Samuelson, 2007). The normal architectural details and some time also cellular details of liver become loss in common domesticated poultry during infectious disease (Hossain et al., 2006; Lu et al., 2014).

Therefore, the study results can be a bunch of information regarding differential diagnosis for post mortem of turkey by comparing with previous studies which will be helpful for poultry practitioner.

## **Chapter 5**

### **Conclusion**

---

This study was planned to determine the anatomical morphology of some important visceral organs (Proventriculus, proventriculus-gizzard junction, cecum and liver) in turkey spp. with histomorphological characteristics of liver for post mortem diagnosis of disease. From the present investigation veterinarians will get clear concept about the normal anatomy of some important visceral organs of turkey spp. which is important for disease diagnosis by post mortem in turkey. Veterinarians will be able to give proper treatment by proper diagnosis. Turkey farmers will be benefited, their loss for mortality will reduce, and production will be increased. Ultimately turkey farming will be more popular and more profitable like broiler and layer chicken farming which will fill-up the protein demand of the country and improve the economy of the country. Finally it can be said the findings of the present study might be useful for post mortem diagnosis, differentiation among contagious diseases of turkey, for effective treatment, and finally for the economy of the country.

## References:

1. Beasley, J., Norton, R., Skeeles, J., Bayyari, G., Huff, W., 1997. Histologic study of hepatic lesions in two turkey flocks. *Avian Dis.*, 347-353.
2. Bhutia, L., Singh, Y.D., 2017. Marek's disease outbreak in poultry population of Mizoram, India. *Indian J. Vet. Pathol.* 41, 224-227.
3. Cervantes, H., Munger, L., Ley, D., Ficken, M., 1988. Staphylococcus-induced gangrenous dermatitis in broilers. *Avian Dis.*, 140-142.
4. Cheema, A., Ahmad, J., Afzal, M., 1989. An adenovirus infection of poultry in Pakistan. *Rev. sci. tech. Off. int. Epiz* 8, 789-795.
5. Dellmann, H.-D., Brown, E.M., 1976. Textbook of veterinary histology. Lea & Febiger.
6. Getty, R., Sisson, S., 1975. Sisson and Grossman's the Anatomy of the Domestic Animals.
7. Ghosh, R.K., 1998. Primary veterinary anatomy. Current Books International.
8. Gowthaman, V., Singh, S.D., Barathidasan, R., Ayanur, A., Dhama, K., 2013. Natural Outbreak of Newcastle Disease in Turkeys and Japanese Quails Housed Along With Chicken in a Multi-Species Poultry Farm in Northern India. *Adv. Anim. Vet. Sci* 1, 17-20.
9. Gridley, Francis, M., 1960. Manual of histologic and special staining technics. McGraw-hill, 1-25.
10. Haider, M., Hossain, M., Hossain, M., Chowdhury, E., Das, P., Hossain, M., 2004. Isolation and characterization of enterobacteria associated with health and disease in Sonali chickens. *Bangladesh Journal of Veterinary Medicine* 2, 15-21.
11. Hasan, A.R., Ali, M., Siddique, M., Rahman, M., Islam, M., 2010. Clinical and laboratory diagnoses of newcastle and infectious bursal diseases of chickens. *Bangladesh Journal of Veterinary Medicine* 8, 131-140.
12. Hossain, M., Chowdhury, E., Islam, M., Haider, M., Hossain, M., 2006. Avian salmonella infection: isolation and identification of organisms and histopathological study. *Bangladesh Journal of Veterinary Medicine* 4, 7-12.
13. Jones, Y.L., Swayne, D.E., 2004. Comparative pathobiology of low and high pathogenicity H7N3 Chilean avian influenza viruses in chickens. *Avian Dis.* 48, 119-128.
14. Kausar, R., Qureshi, A.S., Ali, M.Z., Ateeq, M.K., Usman, M., 2016. Age induced changes in the microscopic anatomy of the digestive system of Japanese quails (*Coturnix japonica*). *Biosci Res* 13, 26-31.



15. Latimer, H.B., 1925. The relative postnatal growth of the systems and organs of the chicken. *The Anatomical Record* 31, 233-253.
16. Long, J., Barnum, D., Pettit, J., 1974. Necrotic enteritis in broiler chickens II. Pathology and proposed pathogenesis. *Can. J. Comp. Med.* 38, 467.
17. Lu, A., Diao, Y., Chen, H., Wang, J., Ge, P., Sun, X., Hao, D., 2014. Evaluation of histopathological changes, viral load and immune function of domestic geese infected with Newcastle disease virus. *Avian Pathol.* 43, 325-332.
18. Madhan, K., Raju, S., 2014. Comparative histology of human and cow, goat and sheep liver. *J Surg Acad* 4, 10-13.
19. Malewitz, T.D., Calhoun, M.L., 1958. The gross and microscopic anatomy of the digestive tract, spleen, kidney, lungs and heart of the turkey. *Poult. Sci.* 37, 388-398.
20. Marsden, S.J., 1940. Weights and measurements of parts and organs of turkeys. *Poult. Sci.* 19, 23-28.
21. McLelland, J., 1990. A colour atlas of avian anatomy. Wolfe Medical Publications Ltd.
22. McLeod, W., 1939. Anatomy of the digestive tract of the domestic fowl. *Vet. Med.* 34, 722-727.
23. Morishita, T., Bickford, A., 1992. Pyogranulomatous typhlitis and hepatitis of market turkeys. *Avian Dis.*, 1070-1075.
24. Musalrz, H., Chen, G., Chengl, J., Li, B., Mekkil, D., 2006. Study on carcass characteristics of chicken breeds raised under the intensive condition. *International Journal of Poultry Science* 5, 530-533.
25. Rahman, M., Samad, M., Rahman, M., Kabir, S., 2004. Bacterio-pathological studies on salmonellosis, colibacillosis and pasteurellosis in natural and experimental infections in chickens. *Bangladesh Journal of Veterinary Medicine* 2, 1-8.
26. Rhoades, K.R., 1964. The microscopic lesions of acute fowl cholera in mature chickens. *Avian Dis.* 8, 658-665.
27. Samuelson, D.A., 2007. Textbook of veterinary histology.
28. Venkatesakumar, E., Ramprabhu, R., Enbavelan, P., Ramkumar, P., Mohanambal, K., Sundararajan, R., 2018. Therapeutic management of Turkey pox using ethno-veterinary herbal preparations. *Journal of Pharmacognosy and Phytochemistry* 7, 2436-2437.
29. Zeleke, A., Gelaye, E., Sori, T., Ayelet, G., Sirak, A., Zekarias, B., 2005. Investigation on infectious bursal disease outbreak in Debre Zeit, Ethiopia. *International Journal of poultry science* 4, 504-506.
30. Ahmed, M., Sarker, A., Rahman, M., 2009. Prevalence of infectious diseases of broiler chickens in Gazipur district. *Bangladesh Journal of Veterinary Medicine* 7, 326-331.

31. Ali, M.M., Hossain, M.M., 2012. Problems and prospects of poultry industry in Bangladesh: An analysis. American International University-Bangladesh (AIUB), Office of Research.
32. Asaduzzaman, M., Salma, U., Ali, H.S., Hamid, M.A., Miah, A.G., 2017. Problems and prospects of turkey (*Meleagris gallopavo*) production in Bangladesh. Research in Agriculture Livestock and Fisheries 4, 77-90.
33. Begum, I., Alam, M., Buysse, J., Frija, A., Van Huylenbroeck, G., 2011. A comparative efficiency analysis of poultry farming systems in Bangladesh: A Data Envelopment Analysis approach. Applied Economics 44, 3737-3747.
34. Islam, M., 2003. Poultry products processing and marketing system in Bangladesh. Pakistan Journal of Biological Sciences 6, 883-886.
35. Morrow, C.J., Samu, G., Mátrai, E., Klausz, A., Wood, A.M., Richter, S., Jaskulska, B., Hess, M., 2008. Avian hepatitis E virus infection and possible associated clinical disease in broiler breeder flocks in Hungary. Avian pathology 37, 527-535.
36. Onwumere, J., Obasi, R., 2010. Analyses of Small-Scale Turkey Production in Owerri Agricultural Zone of Imo State, Nigeria. International Journal of Agriculture and Rural Development 13.
37. Owen, O., Amakiri, A., Ngodigha, E., Chukuigwe, E., 2008. The biologic and economic effect of introducing poultry waste in rabbit diets. International Journal of Poultry Science 7, 1036-1038.
38. Yakubu, A., Abimiku, H., Musa-Azara, I., Idahor, K., Akinsola, O., 2013. Assessment of flock structure, preference in selection and traits of economic importance for domestic turkey (*Meleagris gallopavo*) genetic resources in Nasarawa State, Nigeria. Livestock Research for Rural Development 25.
39. Yassin, O.E., Gibril, S., Hassan, A., Bushara, B., 2013. A study on Turkey (*Meleagris gallopavo*) raising in the Sudan. Journal of Applied and Industrial Sciences 1, 11-15.

# Biography

---

Intern Doctor of Veterinary Medicine

Chattogram Veterinary and Animal Sciences University

E-mail: [steynlee1000@gmail.com](mailto:steynlee1000@gmail.com)

Mobile: +8801866692325

## Personal Profile:

Name: Argha Paul Shuvo

Father's Name: Arindam Paul

Mother's Name: Shelly Paul

Permanent Address: West Dabua, Upozila; Raozan

District; Chattogram

Birth Date: 19<sup>th</sup> August, 1996

Nationality: Bangladeshi

Religion: Hindu

Blood group: A +ve



## Academic Qualification:

Name of the examination/course	Name of the institutions	Board	Passing Year	Grade
SSC	Halishahar Meher Afzal High School	Chattogram	2013	5
HSC	Chattogram Biggan College	Chattogram	2014	5
DVM	Chattogram Veterinary and animal Sciences University	CVASU	-----	-----

## **My Goal**

---

As a human being, I have a long cherished dream to serve my nation through my knowledge, creativity and profession. As a veterinarian, I think I have a great opportunity to fulfill my dream by developing my career in the field as a veterinary practitioner. By dealing as a veterinary surgeon, I would be able to expand and spread my knowledge also.

I have also a high interest in Medical Research, Wildlife Conservation and Eco health approach.