

## INTRODUCTION

Normally, a female dog one to two months of age following estrus is very much affected with pyometra due to elevated progesterone level whether she was bred or not. Clinically, she may present with inappetence, depression, polydipsia, lethargy and abdominal distension. She may or may not have vaginal discharge and fever. About 24% cases The bitch of 10 years age or less then 10 year age are affected with pyometra .(Hagman, 2000). During this time, progesterone levels are elevated and help to create the ideal conditions for infection. This progesterone-primed condition stimulates uterine glandular secretions within the uterus, which suppresses uterine contractions (Cox, 1970) and inhibits the effect of infection-fighting blood cells in the uterus. The effects are cumulative in that each estrous cycle results in more glandular activity and higher levels of inflammatory cells and fluid or mucous within the uterus. After the establishment of a bacterial infection, which may originate from vaginal infection, urinary tract infection, or fecal contamination, the bacteria enter the uterus and multiply. This bacterium produces endotoxins (that are capable of initiating the cytokine cascade and the release of many inflammatory mediators. *E. coli* is thought to be the cause of the local and systemic inflammatory reactions associated with pyometra. Cystic Endometrial Hyperplasia (CEH) often precedes the disease, but can also be found in many older bitches with no signs of pyometra. The clinical manifestations of canine pyometra are well known. Some breeds are more prone to uterine infection like golden retriever, miniature schnauzer, Irish terrier, Saint Bernard, Airedale terrier, Cavalier King Charles spaniel, rough collie, Rottweiler and Bernese mountain dog and some are low susceptible to developing the disease include Drevers, German shepherds, miniature dachshunds, dachshunds (normal size) and Swedish hounds (Egenvall et al., 2001). Severe pyometra sometimes leads to fatal and systemic infection and infertility. Scientific reports on canine pyometra are not frequent in Bangladesh, but common reproductive problems in pets have been reported (Juyena et al., 2005). Different treatment methods have been applied during pyometra treatment but the popular and effective methods is ovario-hysterectomy (OHE) (Feldman and Nelson, 2004; Johnston et al., 2001).

# Materials and Methods

## Study area and duration

My study was conducted Teaching & training pet hospital & research center, CVASU, Dhaka Bangladesh during my internship placement at Teaching & training pet hospital & research center, CVASU, from 15<sup>th</sup> September to 25<sup>th</sup> September, 2019.

## CASE HISTORY

A 7-year-old spitz dog;weight:4kg;name:smoky was admitted to the Teaching & training pet hospital & research center, CVASU, Dhaka Bangladesh, with a several-day history of Purulent vaginal discharge .The clinical examination found that the dog was dull and depressed, licked her backside (vagina) and was uncomfortable. Her daily food intake was decreasing day by day & was becoming weaker day by day. **In** physical examination, the dog was found to be quite normal with the exception of vaginal discharge and a deteriorated body condition. A USG report revealed several dark spaces in the uterus which indicate watery substance in uterus which normally remain empty. So infection in uterus was confirmed. Ovario-hysterectomy is the only solution in that case because it helps to stop disease recurrence.

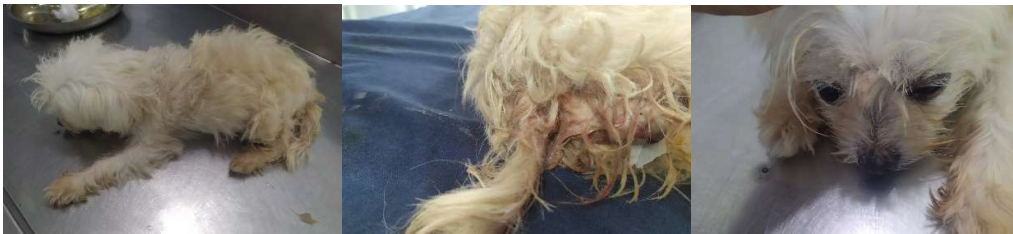

FIG: purulent discharge from vagina & depressed smoky

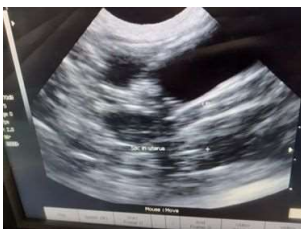

FIG: USG (ultrasonography)

Ovariohysterectomy was aseptically performed according to a standard procedure.

## **Surgical Approaches**

### **Surgical Equipment**

#### **a) Preparation of the Animal**

Ensure that the bitch has been fasted since the previous day especially in the context of elective surgery:

Premedication with xylazine

General anesthesia with ketamin

#### **(b) Preparation of the Surgeon & co-surgeon**

Wear a clean and sterile gown, scrub our hands thoroughly using surgical scrub solution, and wear sterile gloves.

#### **(c) Preparation of the Material**

- sterilized gauze
- 4 artery forceps,
- 4 clamps,
- Scissors
- Needle holder
- Suture (catgut, silk)
- Scalpel blade handle

### **Surgical procedure**

At first the dog was kept in his back on the surgical table. The incision area was filter out by draper. Then a continuous skin incision was performed through the linea alba 2 inches distal from the umbilicus. Then incised the muscle & tissue be sure that no incision of underlying organ . then find out the uterine horn which differentiate from intestinal part by its consistency and color(uterine horn is more

consistence & pink then intestinal parts). Both of the horns are exteriorized to the outside then ovary is exteriorized. The broad ligament is bluntly broken down by finger then ovarian ligament is clamped with two artery forceps then ligated under one forceps strongly with suture then cut with the scalpel blade over the suture & inspect if there was any bleeding finally remove the forceps as there was no bleeding. Same procedure is performed for the 2<sup>nd</sup> ovary. Then uterine body is exteriorized clamp the area between cervixes & uterine body with two forceps. Ligated under one forceps with suture & then cut between ligated area and forceps with scalpel. Inspect if there was bleeding. No bleeding & remove the suture. Removal of uterine body & ovary at kidney tray. Then performed simple continuous suture at muscle by absorbable suture catgut and then simple interrupted suture at skin by non-absorbable silk suture. The operated area was applied BETADIN cream to stop 2<sup>nd</sup>ary bacterial infection. Then prescribed inj.trizon vet, inj. allerin, inj malvet for next 5 days. And application of BETADIN cream at affected place until dry.



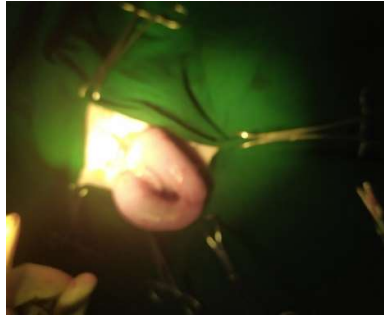
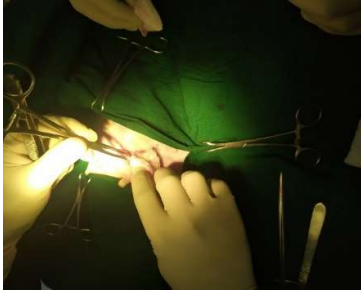
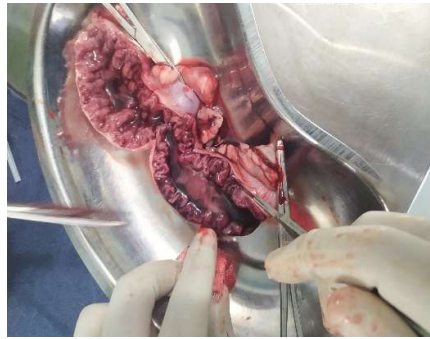
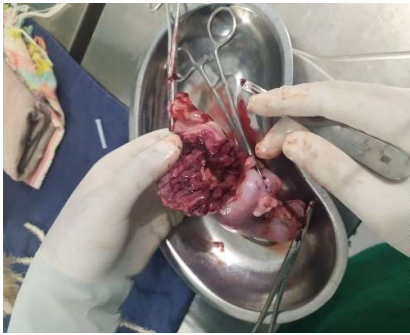


Fig: Surgery, ovario-hystorectomy

## RESULTS AND DISCUSSION

Postoperative gross examination was performed over the uterine horns and ovaries. The gross examination revealed that the uterine horns were flabby the endometrial wall was thick and profuse sanguinopurulent discharge had accumulated in the uterine horn (Fig. 1). This may have been due to inflammation of the myometrium and endometrium wall. The endometrial layer was corrugated and a small cyst-like structure was found on the endometrium (Fig. 2). Some of the endometrial wall had been sloughed off.



## CONCLUSION

Overio-hystorecomy is the recommended treatment in case of pyometra in dog otherwise it may cause systemic diseases.

The best and only prevention for pyometra is to have your dog spayed. Spaying (whether by removing the uterus and ovaries or just the ovaries) removes the hormonal stimulation that causes both heat cycles and the uterine changes that allow pyometra to happen. It is considerably safer (and less expensive) to spay a healthy dog with a healthy uterus than it is to take a sick dog with an abnormal uterus to surgery. The current recommendation is to have female dogs spayed prior to their first heat cycles, but most older dogs are also good candidates for undergoing the spay procedure. Speak with your family veterinarian about the spay procedure, its risks, and its benefits.

## Reference

1. Barton, C., 1992. Diseases of the Uterus-Cystic Endometrial Hyperplasia/Pyometra Complex. In: Handbook of Small Animal Practice, Morgan, R.V. (Ed). 2nd Edn., Churchill Livingstone, New York, USA., pp: 655-658.
2. Coggan, J.A., P.A., Melville, C.M. de-Oliveira, M. Faustino, A.M. Moreno and N.R. Benites, 2008. Microbiological and histopathological aspects of canine pyometra. *Brazilian J. Microb.*, 39: 477-483.
3. Cox, J.E., 1970. Progestagens in bitches: A review. *J. Small Anim. Prac.*, 11: 759-778.
4. CrossRef |
5. De Bosschere, H., R. Ducatelle, H. Vermeirsch, W. Van-Den Broeck and M. Coryn, 2001. Cystic endometrial hyperplasia-piometra complex in the bitch: Should the two entities disconnected?. *Theriogenology*, 55: 1509-1519.
6. Feldman, E.C. and R.W. Nelson, 2004. Cystic Endometrial Hyperplasia/Pyometra Complex in Canine and Feline Endocrinology and Reproduction. In: *Canine and Feline Endocrinology and Reproduction*, Kersey, R. and D. LeMelledo (Eds.). 3rd Edn., W.B. Saunders Company, USA., pp: 847-860.
7. Hagman, R., 2000. New aspects of canine pyometra. Ph.D. Thesis, The Swedish University of Agricultural Sciences, Uppsala, Sweden.
8. Johnston, S.D., M.V.R. Kustritz and P.N.S. Olson, 2001. Disorders of the Canine Uterus and Uterine Tubes in Canine and Feline Theriogenology. In: *Canine and Feline Theriogenology*, Kersey, R. and D. LeMelledo (Eds.), W.B. Saunders Company, USA., pp: 174-220.
9. Juyena, N.S., M.G.S. Alam, M.A. Hossain and M. Hossain, 2005. Occurrence of dog diseases in Dhaka Metropolitan City. *The Bang. Vet.*, 22: 50-53.
10. Susi, A., R. Iris and H. Madeleine, 2006. Canine pyometra: New approaches to an old disease. *Proceedings of the 31st World Small Animal Veterinary Conference, (WSAV'06), Czech Republic*, pp: 691-692.



## **Acknowledgement**

All the commendations and most profound feeling of appreciation has a place with the Almighty God, the Merciful ,the transcendent, and the Beneficent however the incomparable Ruler of the Universe Who empowered me to finish my work effectively for temporary position program.It is my great privilege to express deep sense of gratitude and heartfelt indebtedness, sincere appreciation and profound regards to my honorable supervisor Professor **Professor Md. Abdul Ahad**, Dean, Faculty of Veterinary Medicine, Chattogram Veterinary and Animal Sciences University for the enormous support, supervision, advice, guidance and for offering numerous valuable ideas, suggestions, who has devoted hours and hours of time and patience, motivation and immense knowledge for me. His guidance helped me during every steps of this study from its inception to completion.

I am also highly expresses my sincere gratitude and gratefulness to the internship Coordinator, **Professor Dr. A.K.M. Saifuddin**, Director, External Affairs, Chattogram Veterinary and Animal Sciences University,

I would like to thank the animal owner ( arpon chowdury), Main surgeon (Byazid sir) & the staffs of the TTPHRC for their cordial support during the work.

## **BIOGRAPHY**

My self jony dev, the author of this case report would like to introduce as Intern. DR of Chittagong Veterinary and Animal Sciences University (CVASU) have passed

four years academic career in faculty of veterinary medicine and attended several clinical training programs on Veterinary Medicine in Bangladesh. As

a student of Veterinary science, the main mission and vision of my life is to do something better and creative job by dint of my academic knowledge and experience, for the development of livestock as well as development of the economic condition of our country. This case report on pyometra is the first step to fulfill my dream. I strongly assure that I have done all the works furnished here in this report and I hold entire responsibility of the information given here which are collected from different books, journal and websites.