

## Table of contents

Chapter	Contents	page
	Table of contents	1
	List of Figures	2
	List of table	2
	Abstract	3
Chapter I	Introduction	4
Chapter II	Review Literature	5-8
	2.1 Ovary	
	2.2 Oviduct	
	2.2.1 Infundibulum	
	2.2.2 Magnum	
	2.2.3 Isthmus	
	2.2.4 Shell Gland/Uterus	
	2.2.5 Vagina	
	2.3 Gross morphological study of oviduct	
Chapter III	Results and Discussion	9-10
Chapter IV	Conclusion	11
Chapter V	Limitations	11
	References	12-13
	Acknowledgement	14
	Biography	15-16

## LIST OF FIGURES

<b>Figure</b>	<b>Content</b>	<b>Page</b>
Figure (a)	Ovary of Chicken .....	5
Figure (b)	Oviduct of Chicken .....	5
Figure (c)	Reproductive system of hen.....	8
Figure(d)	Left oviduct odDeshi Chicken.....	9

## LIST OF TABLES

<b>Content</b>	<b>Page</b>
Representation of oviduct and its segment.....	10

## ABSTRACT

The present study was carried out on the oviduct of laying native chicken of Bangladesh at the age range of 8-12 months old. After dissection, morphological parameters such as total length and weight of oviduct, length and weight at the age range of 8-11 months were determined. For the histological study, after preparation and staining with hematoxylin and eosin, histological layer of oviductal tissues were recognized. The mean length and weight of total oviduct of native chicken were  $7.18 \pm 4.22$  cm and  $24.45 \pm 1.81$  gm respectively. The mean length and weight of oviductal segments, infundibulum ( $7.18 \pm 4.22$  cm and  $7.18 \pm 4.22$  gm), magnum ( $18.40 \pm 6.75$  cm and  $18.40 \pm 6.75$  gm), isthmus ( $7.68 \pm 3.46$  cm and  $7.68 \pm 3.46$  gm), uterus ( $6.10 \pm 2.80$  cm and  $6.10 \pm 2.80$  gm) and vagina ( $6.83 \pm 2.82$  cm and  $6.83 \pm 2.82$  gm) were measured. Both the length and weight of oviductal segment was progressively increasing from 8-10 months and was decreased at 11 months age. Histological features of oviductal segments varied in regards to the distribution of gland, connective tissues arrangement and mucosal folding. Particularly, the distribution of tubular glands among the segments of oviduct was significantly different. In the magnum and isthmus, populations of tubular glands were higher whereas other segments had limited glands.

**Keywords:** Chicken, Oviduct, Gross morphological study

## Chapter I

### INTRODUCTION

Bangladesh is a developing country. She has small land area about 1,47,570 sq. km but large amount of population about 160 million. So in the recent years poultry rearing becomes popular than any other livestock in our country because of its small size, easy of handling, low feed intake, high multiplication rate, less space requirement, less cost, quick return and protein source. According to DLS (2007), meat requirement is 120gm/day/head and 6.26 million metric ton/year. But our achievement is 20gm/day/head and 1.04 million metric ton/year. Poultry meat contributes approximately 37% of the total animal protein supplied in the country (Rahman, 1998). So we can say that the production cannot cope at with the high demand by our native chicken. For this the government encourages the people for poultry farming as an industry. In Bangladesh, 50 commercial poultry industry has seen a tremendous development in the recent years. According to number provided by government of Bangladesh livestock department, the total chicken population is steadily increasing from about 143 million birds in 2006 (DLS, 2007). Recent data showed that total number of chicken in 2008 is 175.15 million (Krishi dairy, 2008). Reproduction in poultry is completely different from other farm animal species. In the poultry, there are two principle reproductive organs; ovary and oviduct; which are participated in the production of egg in laying hen. The oviduct of chicken is an egg producing organ, which convey the ovum to the cloaca and it successively adds the albumin from the glands of magnum. Finally, shell membrane added from isthmus, the hard calcite shells and shell pigments from uterus and the bloom or cuticle from the gland of vagina. Therefore, oviduct play vital role in the assembly of egg components after receiving ova from ovary. From the available literature it is observed that the anatomical study of oviduct was confirmed in hybrid chicken (Khan et al., 1999).

#### Objectives:

- To develop knowledge about anatomy of chicken oviduct.
- To clear concept about different parts and their functions in oviduct.

## Chapter II

### REVIEW LITERATURE

The oviduct of chicken consists mainly of 2 part,

1. Ovary

2.Oviduct

The oviduct has 5 parts. These are: i) Infundibulum, ii)Magnum,iii) Isthmus, iv) Shell gland ( Uterus) and (v) Vagina .

### OVARY

The ovary (shown in Figure) is a cluster of developing ova, and is located midway between the neck and the tail of the bird and attached at the back. The ovary is fully formed when a pullet chick hatches but is very small until the chick reaches sexual maturity. At hatch, a pullet chick has tens of thousands of ova, or potential eggs that theoretically could be laid, although most never develop to the point of ovulation. The maximum number of eggs a hen can lay is determined when it hatches because no new ova form after the chick hatches.

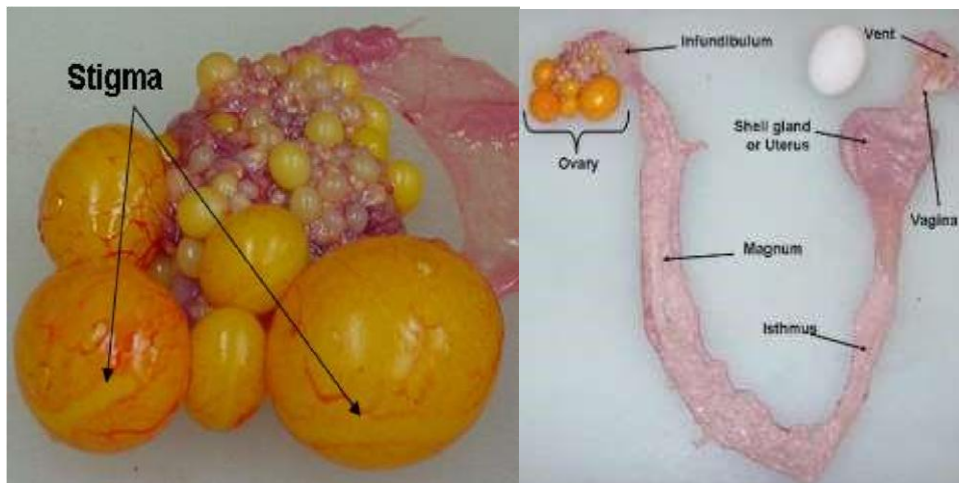


Figure: ovary of chicken (a), oviduct of chicken(b)

## **OVIDUCT**

When ovulation occurs, the ovum (yolk) enters the oviduct. The oviduct is a twisted tube that is 25 to 27 inches long when fully developed and is divided into five major sections. These sections are the infundibulum, magnum, isthmus, shell gland and vagina.

### **INFUNDIBULUM:**

The first part of the oviduct, the infundibulum (or funnel) is 3 to 4 inches long and engulfs the ovum released from the ovary. The term funnel is an inaccurate name for this section because it suggests that the infundibulum is waiting for the yolk to fall into it, which is not the case. Instead, the released yolk stays in place, and the muscular infundibulum moves to surround it. The yolk remains in the infundibulum for 15 to 17 minutes. Fertilization, if it is going to occur, takes place in the infundibulum.

### **MAGNUM:**

The next section of the oviduct is the magnum. At 13 inches long, it is the largest section of the oviduct, as its name implies (magnum being the Latin word for “large”). The yolk remains here 3 hours, during which the thick albumen (egg white) forms.

### **ISTHMUS:**

The third section of the oviduct is the isthmus, which is 4 inches long. The isthmus, as its name implies, is slightly constricted (the term isthmus referring to a narrow strip of land joining two larger tracts of land). The isthmus is where the inner and outer shell membranes form. The developing egg remains here for 75 minutes.

## **SHELL GLAND OR UTERUS**

The next section of the oviduct is the shell gland (or uterus), which is 4 to 5 inches long. In this section, the egg shell forms on the egg. The egg shell largely is made of calcium carbonate. The hen's body mobilizes 8 to 10 percent of body calcium from its bones to make the egg shell. Bone calcium provides 47 percent of the calcium required to make a shell, and the hen's diet provides the remainder. Pigment deposition, if there is any, occurs in the shell gland. The egg remains here for 20 or more hours.

## **VAGINA**

The last part of the oviduct is the vagina, which is about 4 to 5 inches long. The vagina does not really play a part in egg formation but is important in the laying of the egg. The vagina is made of muscle that helps push the egg out of the hen's body. The bloom, or cuticle, forms on the egg in the vagina prior to oviposition (the laying of the fully formed egg). The egg travels through the oviduct small end first but turns in the vagina and comes out large end first.

Near the junction of the shell gland and the vagina are deep glands known as sperm host glands that can store sperm for long periods of time, typically 10 days to 2 weeks. (One of the unique things about birds is that the sperm remain viable at body temperature.) When a hen lays an egg, sperm can be squeezed out of these glands into the oviduct and then can migrate to the infundibulum to fertilize an ovum.

## GORSS MORPHOLOGICAL STUDY OF OVIDUCT

In this study, deshi chickens were killed by cervical subluxation. Standard anatomical dissection of each bird was done as described previously. Total four deshi chickens were used from 8, 9, 10, 11 months of age (one from each month). The whole oviduct was quickly dissected out and stretched on tray. The morphometrical study included the color, length and weight of oviduct. Individual weight of each segment of oviduct was measured by balance weight machine. Length was measured by scale. Relative weights of the oviduct were also calculated adopting following formula according to Federova (1987).

**Relative weight of oviduct= (weight of oviduct/body weight) / 100**

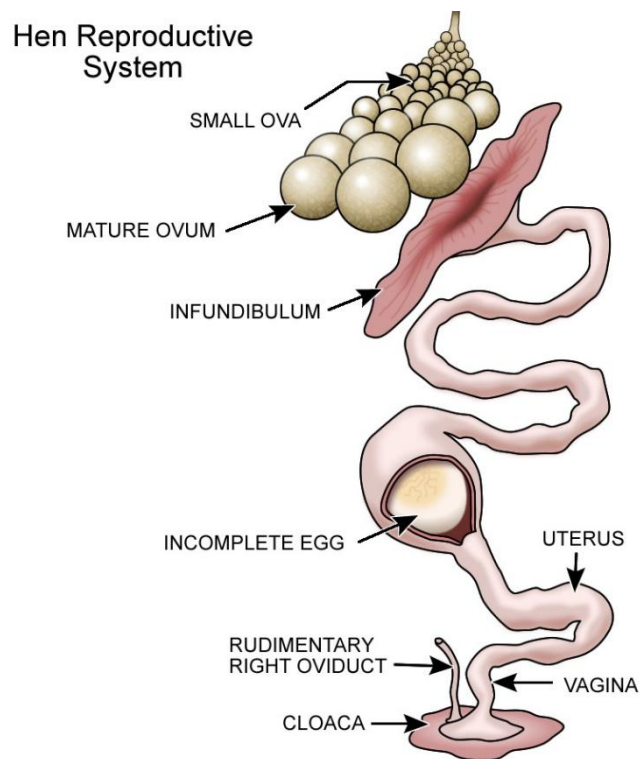


Figure (c) Reproductive system of hen.



## Chapter III

### RESULT AND DISCUSSION

#### General morphology of the oviduct

In the present study, only the left oviduct was found functional as described by several authors in different poultry breed (Kar., 1947).

The left oviduct was extended from ovary to cloaca and had occupied the largest part of abdominal cavity. In the local deshi chicken of Bangladesh, oviduct was initially thin and fiber like structure at one day old, and highly coiled at 30 weeks. Similar result was observed in hybrid chicken (White Leghorn) at one-day old to 15 weeks old chicken by Kar (1947). These authors showed the developmental changes in the oviduct from Day-1 to 30 weeks (5 month). In the

and had clearly five segments . The total length and weight of the oviduct was  $46.18 \pm 9.49$  cm and  $24.45 \pm 1.81$  gm respectively. Therefore, the present study revealed the additional present study, using the adult laying hen at 8-11 months old, oviduct was highly convoluted,

information of adult deshi laying hen at 8-11 months old.

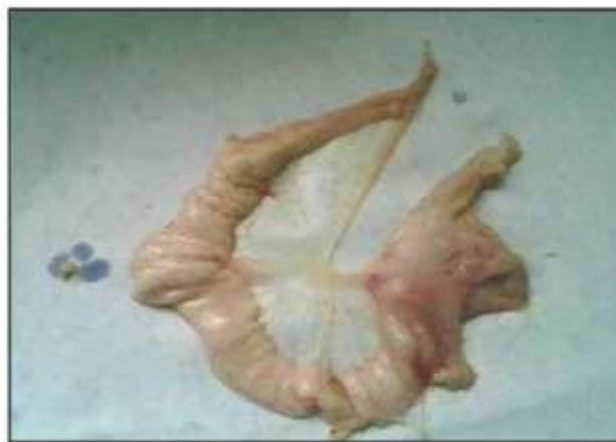

Figure (d): Left oviduct of deshi chicken dissection

**Table: Representation of Oviduct and Its Segment**

<b>Serial No</b>	<b>Part of oviduct</b>	<b>Functions</b>	<b>Duration of developing stages</b>	<b>Length in cm</b>
1	Infundibulum	Picking and engulfing the yolk sac	15 minutes	9
2	Magnum	Secretion of thin and thick albumin	3 hours	33
3	Isthmus	Formation of shell membrane	1 hour and 15 minutes	10
4	Uterus	Formation of shell	18 to 21 hours	10
5	Vagina	Oviposition	2 to 5 minutes	6
Total			24 hours and 35 minutes	68

## **Chapter IV**

### **CONCLUSION**

The study was conducted in order to understand the oviduct of Chicken and through analysis we found out the ovary is a cluster of developing ova and the oviduct is a twisted tube, which have five parts to form a complete egg. Infundibulum is the first part where fertilization takes place. Magnum works as a resting place of the yolk and thick albumen forms there. Isthmus is the place, where inner and outer shell membrane forms and the next part is uterus which is the shell former of an egg. An egg stays about 20 hours or more in the Uterus. The last part of oviduct is vagina, which helps to lay the egg. We measured the length and different parameters by dissecting chicken oviduct. The study was informative and enjoyable.

## **Chapter V**

### **LIMITATIONS**

Data keeping was not done properly sometimes. Some data were collected indirect way. No fixed protocol was practiced for management. The period of the study was short to analyse. Direct Regular follow up of management practices was not possible. Moreover, due to pandemic of the CoViD19 outbreak, data collection was not possible directly at the ending of the study.

## REFERENCES

- Breen PC, De Bruyn PPH (1969). The fine structure of the secretory cells of the uterus (shell gland) of the chicken. *Journal of Morphology* 128, 35–66.
- Curtis MR (1910). The ligaments of the oviduct of the domestic fowl, *Bull. The Maine Agricultural Experiment No 176*: 1-20.
- Federova NN (1987). Growth and development of the reproductive system in white Leghorn hens in different light system. *Sobor. Nanch. Trud. Moskovaskaya Veterinaraya Akademyia* 128: 37-40.
- Fujii S (1963). Histological and histochemical studies on the oviduct of the domestic fowl special reference to the region of utero-vaginal juncture. *Archives of Histology and Japanese* 23: 447-459.
- Giersberg H (1922). Untersuchungen über Physiologie und Histologie des Eileiters der Reptilien und Vogel: Nebsteinernbeifpagzurfaseganese. *Zeitschrift für wissenschaftliche Zoologie* 120: 1-97.
- Gridley MF (1960). *Manual of histologic and special staining technique*. MacGraw-Hill Book Company, USA, 28-29: 82-83.
- Islam MR, Khan MZI, Rahaman ML and Mohsin K (2002). Postnatal growth and development of oviduct of desi chicken (*Gallus gallus domesticus*) of Bangladesh. *Bangladesh Veterinary Journal* 36 (1-2): 35-41.
- Johnston HS, Aitken RNC and Wyburn GM (1963). The fine structure of the uterus of the domestic fowl. *Journal of Anatomy* 97: 333-344.
- Kar AB (1947). Studies on the ligaments of the oviduct in the domestic fowl. *Anat. Rec.* 97:175-192.
- Khan MZL, Asaduzzaman M, Rahman A and Islam Kh N (1999). Distribution and quantification of large granular lymphocytes (LGLs) in the sperm host glands of chicken oviduct. *Bangladesh Journal of Animal Science* 28(1-2): 47-51.
- Richardson KC (1935). The secretory phenomena in the oviduct of the fowl, including the process of shell formation examined by microincineration technique. *Philosophical Transactions of the Royal Society B* 225: 149-195.

Romanoff AL and Romanoff AJ (1949). *The avian Egg*. John Wiley and Sons, New York.

Taylor T and Hertelendy F (1960). Parallel distribution of calcium and citric acid in the oviduct of the hen. *Nature* 187: 244-245.

Warren DC and Scott HM (1935). Physiological factors influencing the, rate of egg formation in the domestic hen. *Journal of Agricultural Research* 51: 565-572.

## ACKNOWLEDGEMENT

All praises are due to the immeasurable grace and immense kindness of Almighty “GOD”, the supreme authority and supreme ruler of universe, who has empowered me to complete the work successfully. I would like to express my gratitude to my supervisor, **Professor Dr. Kh. Nurul Islam**, Dept. of Anatomy and Histology, Chattogram Veterinary and Animal Sciences University.

My heartfelt thanks to his for valuable guidance, suggestion, supervision and encouragement during the entire period of this study to complete this Clinical report.

I would like to express my deep sense of gratitude and thanks to **Professor Dr. Md. Alamgir Hossain**, Dean, Faculty of Veterinary Medicine, CVASU.

I express my sincere gratitude and thanks to **Professor Dr. A. K. M. Saifuddin**, Director of External Affairs, for his supervision and kind co-operation during the period of internship

Last but not least, I am profoundly grateful to my family members for their endless sympathies, kind co-operation, sacrifices and prayers. The Author

November, 2021.



**Intern Doctor, Faculty of Veterinary Medicine**

**Chattogram Veterinary and Animal Sciences University**

E-mail: laboni206barua@gmail.com

Mobile: +8801521566906

**Personal Profile:**

Name: Himaddry Barua

Father's Name: Nandan Barua

Mother's Name: Rinku Barua

Permanent Address: Village: Betagi; P.O: Betagi; Upazilla: Rangunia; District: Chattogram

Birth Date: 17th March, 1998

Nationality: Bangladeshi, Religion: Buddhism, Blood group: A+

**Academic qualification:**

<b>Name of the examination/ Course</b>	<b>Name of the institution</b>	<b>Board</b>	<b>Passing year</b>	<b>Grade</b>
SSC	Chittagong Engineering University School and College	Chattogram	2013	5.00
HSC	Chittagong Engineering University School and College	Chattogram	2015	5.00
DVM	Chattogram Veterinary and Animal Sciences University	CVASU	----	

### **My goal**

As a human being, I have a long-cherished dream to serve my nation through my knowledge, creativity and profession. As a veterinarian, I think I have a great opportunity to fulfill my dream by developing my career in the field as a veterinary practitioner. By dealing as a veterinary surgeon, I would be able to expand and spread my knowledge also. I have also a high interest in Medical Research and Public health approach..