

Caesarean section of a Persian cat: A surgical intervention for management of dystocia due to partial primary uterine inertia



A clinical report submitted in partial satisfaction of the requirement for the Degree of Doctor of Veterinary Medicine (DVM)

**Submitted by:
Partha Paul
Roll No: 18/46
Reg No: 03008
Intern ID: 44
Session: 2017-18**

**Faculty of Veterinary Medicine
Chattogram Veterinary and Animal Sciences University
Khulshi, Chattogram – 4225, Bangladesh**

Caesarean section of a Persian cat: A surgical inter-vention for management of dystocia due to partial primary uterine inertia.



Approved by:

(Dr. Mohammad Masuduzzaman)

Professor

Department of Pathology and Parasitology

Faculty of Veterinary Medicine

**Chattogram Veterinary and Animal Sciences University
Khulshi, Chattogram – 4225, Bangladesh**

November 2023

Acknowledgment

All the praises go to the Almighty of God, the creator and supreme ruler of the universe, who enabled the author to complete the work successfully.

The author expresses his sincere gratitude, humble respect and immense indebtedness to his supervisor Professor Dr. Mohammad Masduzzaman, Department of Pathology and Parasitology, Chattogram Veterinary & Animal Sciences University for her guidance, kind co-operation, sincere help, valuable suggestions, constructive criticism and for his active involvement with this study from its inception. The author also expresses his gratitude and deep sense of respect to all of his friends and well-wishers for their support and inspiration throughout the study period and for preparing this report.

Last but not least, the author extended his appreciation to all of his teachers and his parents for their unforgettable support, suggestion, criticism and cordial help from its inception to the last of his study.

Author

Nov, 2023

Table of Contents

Chapter	Content	Page no.
	Abstract.....	1
Chapter 1	Introduction.....	2
Chapter 2	i. Case Details.....	3
	ii. Case diagnosis.....	4
	iii. Surgical procedure.....	5-7
	iv. Post-operative care.....	8
Chapter 3	Results and discussion.....	9
Chapter 4	References	10
	Biography.....	11

Abstract

The incidence of dystocia in cats is relatively low compared to that in other pet and farm animals. However, when dystocia occurs in cats, manual, medicinal, or surgical intervention is required. This case report is mainly focused on dystocia in a cat case, and a caesarian section has been done for it. A one-year-old Persian cat has been brought into a Teacher and Training pet hospital in Dhaka with dystocia symptoms. The queen delivered the new-born kitten 22 hours earlier and was unable to deliver the next kitten. After 3 hours, the newborn died. The queen was depressed, off-feed, and made no straining effort. On the X-ray report, we found two fetuses remaining in her uterine horn, and the ultra-report found one was heartbeat present and the other was absent. The queen was diagnosed with dystocia due to partial primary inertia. After the medicinal treatment, when it did not work, a c-section was performed. A C-section was performed, and without any complications, the dead fetus and live fetus were expelled from the uterine horn. The queen recovered fully. To the best of our knowledge, we are here for the first time with a successful surgery on a dystocia case of a Persian cat due to partial primary inertia > 22 hr.

Chapter 1

Introduction

The term "dystocia" has its origins in the Greek language. It is derived from the Greek words "dys," meaning "difficult," and "tokos," meaning "childbirth" or "labor" (Mee, J.F. 2008). Dystocia refers to the dam's inability to naturally deliver the fetus during birth without any external help. It manifests as prolonged straining that fails to produce a kitten, extreme restlessness, and vocalization during labor. Birth canal blockages that occur during labor can soon endanger the lives of both the queen and the kitten (Naoman 2021). Possibility of dystocia is relatively rare in companion animals such as dogs and cats from large animals (Jackson 1995)

According to a study, it was found that cats experience dystocia in approximately 3.3% to 5.8% of all births (Pretzer 2008). But, when it does happen, it can pose life-threatening risks to both the mother and her offspring. The incidence of dystocia more common in Persian cats and less common in Norwegian forest cats compared to other breeds (Ekstrand, C., & Linde-Forsberg 1994). Maternal and fetal factors are the two main causes of dystocia (Stedile, R. 2011). Sometimes it can occur as a combination of two. According to the report, 67.1% of cases were caused by maternal factors, and 29.1% were caused by fetal factors (Jackson 1995). The fetal causes of dystocia include fetal oversize, malformation, malposition and abnormal posture. The maternal causes of dystocia mainly include abnormal force of contractions (abdominal and uterine) and incomplete dilatation of birth canal (narrow pelvis, uterine torsion, cervical/vaginal tumor, abscess, cyst and fibrosis etc. The most common case of dystocia in cats is uterine inertia, which is about 60.6% of cases. Uterine inertia is a condition of weak or lack of uterine contraction during parturition (Raut et al. 2009). It is also associated with abnormalities in the birth canal and an imbalance of hormones. Uterine inertia can be classified as primary or secondary inertia (Gendler, Brouman, and Graf 2007).

Primary uterine inertia is more common than secondary in felines. Depending on the type of dystocia, management should be most important for surviving the fetus and mother. Either it should be surgical or treatmental. Surgery for dystocia is the most common & save from medical treatment in small animals such as cat (Traas 2008).

Chapter 2

CASE REPORT

1)Case history

A 1-year-old Persian queen cat (Fig1), weighing 3.10 kg body weight was presented to the Teaching and Training Pet Hospital and Research Center (TTPHRC) on November 4, 2023 with signs of dystocia. The cat underwent natural mating and completed the full 65-day gestation period, as reported by the owner. The cat displayed signs of impending labor, such as restlessness, loss of appetite, and rapid breathing approximately 1-2 hour before delivery the first kitten. Then, the queen had given birth to one dead kitten before 36 hours ago and was unable to give birth to her next kitten. In the history, we know that she had three live-kitten ultra-reports from her owner. The date of childbirth was set for November 3rd. But after giving birth, she cannot deliver the next kitten. The cat was anorectic and depressed; her abdomen was extremely large, and she showed no effort to strain.

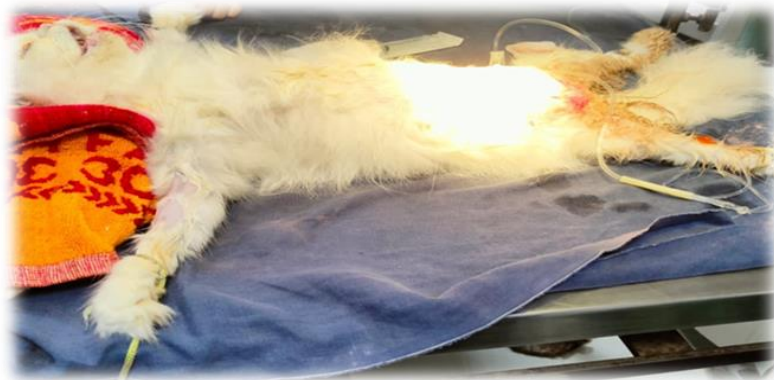

Fig: Before surgery patient condition

2)Case diagnosis

A physical examination was performed, and on palpation, bone-like structures were found in the pelvic cavity. In order to make a more accurate diagnosis, an X-ray was taken (Fig. 2), which showed the existence of two fetuses. An ultrasonography (USG) examination was then carried out for confirmation, which proved the presence of two fetuses in one uterine horn. Here, one fetus was present heart beat and the other had no heart beat (Fig 3). The case was diagnosed as dystocia and referred to surgery immediately to save the mother and the live fetus.

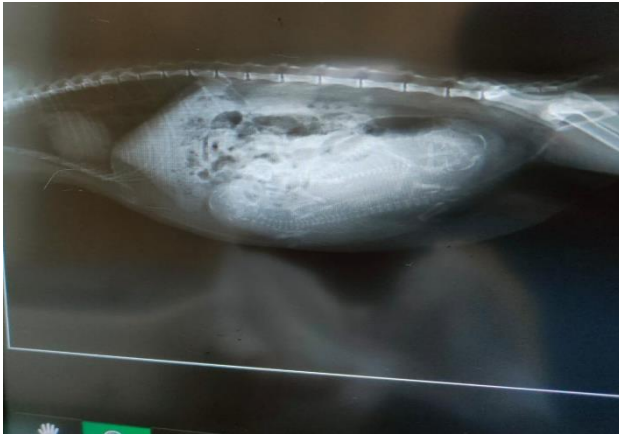


Fig 2: X-Ray report of queen

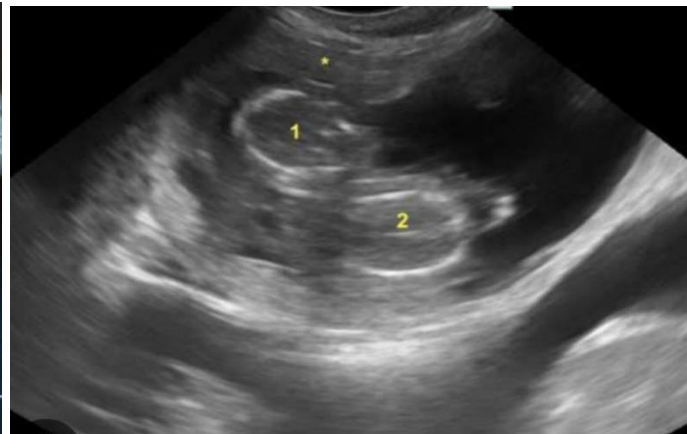


Fig 3: Ultra- report of queen

3)Surgical procedure:

At first, the queen received an initial injection of a pre-anesthetic substance, specifically xylazine administered intramuscularly at a dosage of 1mg/kg body weight. Following a 10-minute interval, general anesthesia (GA) was induced by administering ketamine hydrochloride (Ketaride®, manufactured by Incepta Pharmaceuticals Ltd.) at a dosage of 10mg/kg of body weight in intramuscularly. The cat reached anesthetized within 15 minutes. Subsequently, the cat was transferred to the surgical table, and its limbs were securely fastened using surgical gauze ropes. Tongue forceps were used to pull the tongue to the side, and the mouth was closed. Next, a surgical drape was positioned over the patient. Then 5-6 cm incision was carefully created along the ventral midline of the abdomen, situated 1 cm caudal to the umbilicus (Fig-4a)F. This incision involved several layers, including the skin, subcutaneous tissue, linea alba, and finally, the peritoneum, all of which were incised sequentially. A longitudinal cut was then made along the greater curvature of the uterus, near the point where the uterine horns bifurcate, to avoid major blood vessels and the placental attachment. After that, the two fetuses were extracted from the left uterine horn (Fig-4b). Here first fetus was lived and second fetus was dead. After removing two fetuses, the lived fetus was cleaning from palcenta fluid and other dirty. (Fig-5).

The peritoneum, muscle and subcutaneous tissue were closed using simple continuous suture with cat-gut 1-0 (Figure 4c), and the skin was closed by applying horizontal mattress sutures with silk thread (Fig-4d). dead.

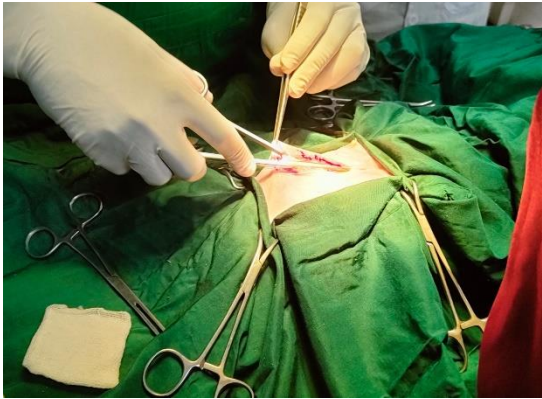

Fig 4a-The incision site

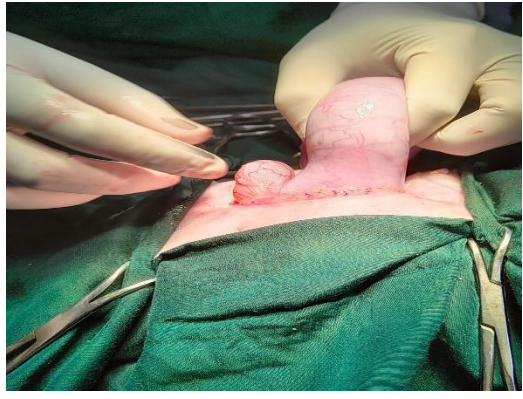


Fig 4b- fetus expelled from uterine horn

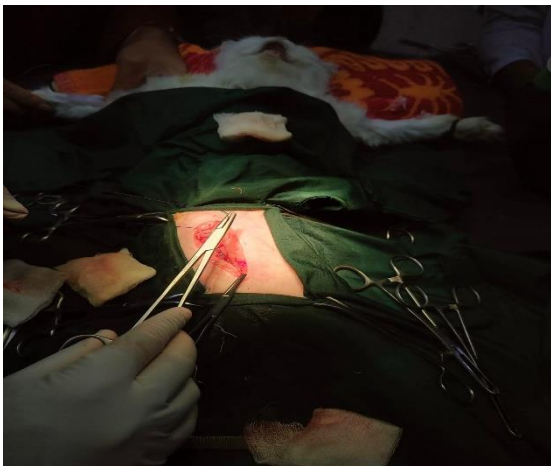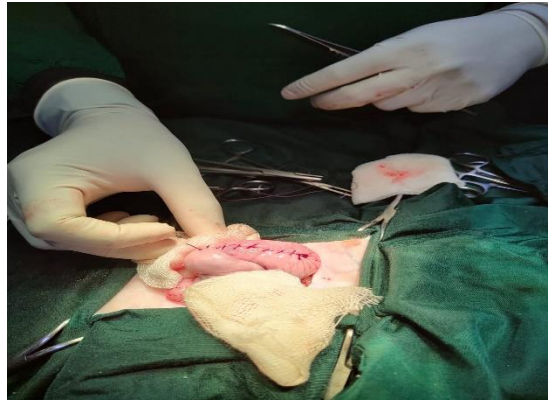
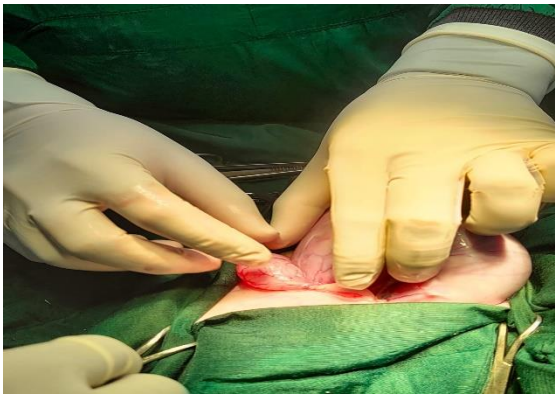


Fig-4c- Suturing in the muscle

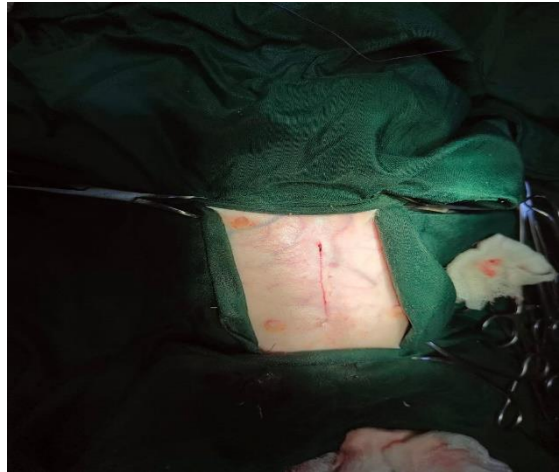

Fig-4d-Suturing in the skin.

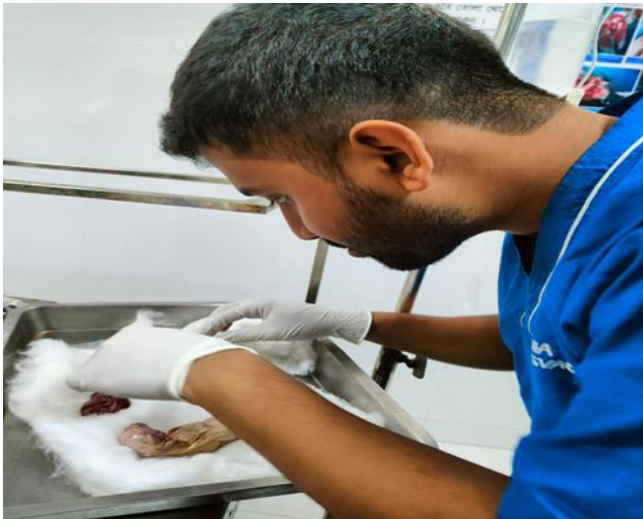
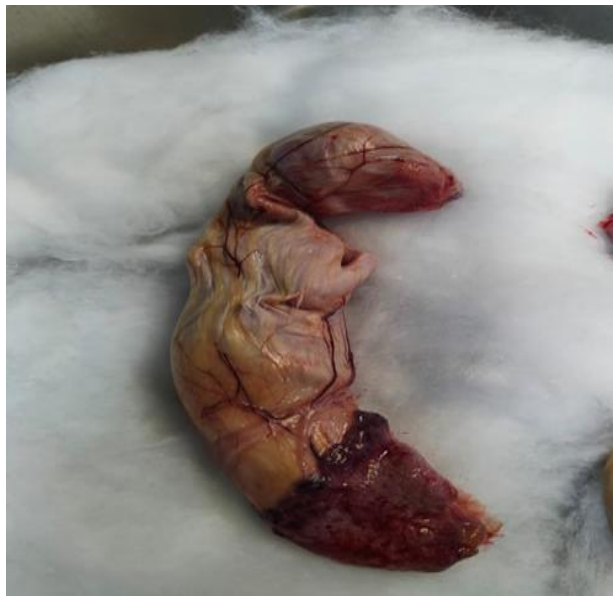
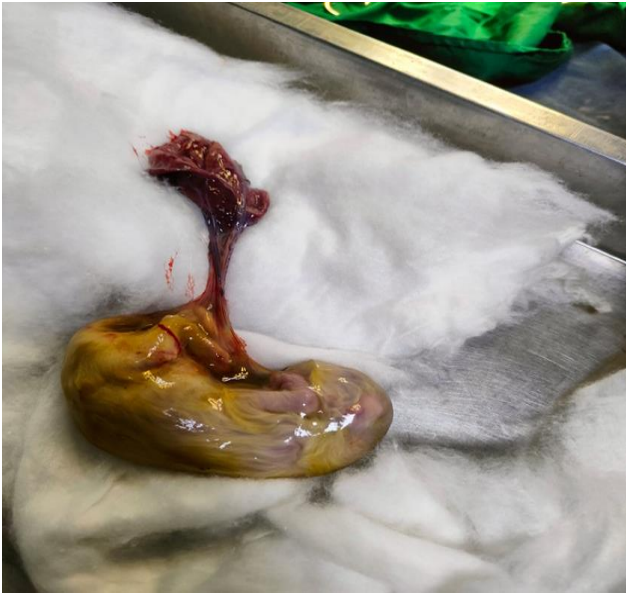Fig- 5 Live and dead fetus and cleaning the live fetus

Post-operative care

Postoperative care is very important after surgery. It helps to regenerate the healing tissue and keeps the animal healthy without any further complications. In postoperative care, a broad-spectrum antibiotic drug, Ceftriaxone (Trizect Vet, Eskayef Company), was administered intramuscularly at 25 mg/kg body weight. Then given SAID (steroidal anti-inflammatory drug) pednisolone (Roxadex, Nuvista Pharma) in intramuscularly 1 mg/kg body weight as a pain killer and antihistamine, then Aminovit plus drug 0.6 ml intramuscularly given as a multivitamin drug. Further, it is suggested that if the queen feels weak or off-feed, give 5% dextrose saline with 7-8 drops twice daily orally . Additionally, after 10 days of full healing, external skin stitches were removed.

Chapter 3

Result and discussion

In surgery, two fetuses, one dead and the other live, with their placenta removed by c-section. The live fetus was cleared of dirty placenta fluid. The dead fetus kept another palace. After the surgery, the queen returned to all normal activities, including eating, urinating, and milking her kitten. However, when dystocia occurs, there are two forms of treatment: medicinal and surgical (Pretzer 2008). The drug of choice for treatment of uterine inertia is oxytocin, along with calcium borogluconate and glucose solution in cats (Jackson 1995). In the case of our queen, she delivered the first kitten 22 hours ago, and he couldn't deliver the next kitten. The queen did not show any straining effort, and he failed to respond to medical therapy. But in the case of some cats normal physiological condition delivered their next kitten duration range had 48 hours found from (Sparkes et al. 2006). They responded to their strain after the first kitten birth. But in our case, after medical treatment, he never showed any response, and our queen had a live fetus. In addition, anorexia, sadness, dullness, and foul-smelling vaginal discharge were indicated as signs of maternal toxemia. According to (Barolia et al. 2010) this situation may be the consequence of an exhausted uterus that was unable to contract in order to deliver the remaining fetuses. Due to all of these circumstances, we had to perform an emergency C-section to deliver the remaining fetuses and preserve the mother's life.

Chapter 4

Reference

1. Gendler, A, J D Brouman, and K E Graf. 2007. "Canine Dystocia: Medical and Surgical Management." *Compendium: Continuing Education For Veterinarians* 29: 551–62.
2. Jackson, P.G.G. 1995. *Handbook of Veterinary Obstetrics*. Philadelphia, USA: W.B. Saunders Co.
3. Mee, J.F., 2008. 2008. "Managing the Cow at Calving Times." *Irish Veterinary Journal*: 41: 35-41.
4. Pretzer, S D. 2008. "Medical Management of Canine and Feline Dystocia." *Theriogenology* 70(3): 332–36.
<https://www.sciencedirect.com/science/article/pii/S0093691X08002197>.
5. Raut, B. M. et al. 2009. "Uterine Inertia in Bitch." *Veterinary World* 2(2): 71.
6. Stedile, R., Oliveira. 2011. *Dystocia in a Cat Due to an Ectopic Artery*No Title.
7. Traas, A M. 2008. "Surgical Management of Canine and Feline Dystocia." *Theriogenology* 70: 337–42.
8. Barolia, Y et al. 2010. "Dystocia Due to Secondary Uterine Inertia in a Bitch." *J. canine develops. Res* 6: 66–68.
9. Naoman, U. 2021. "Causes and Treatment of Feline Dystocia." *Journal of Applied Veterinary Sciences* 6.
10. Sparkes, Andrew H et al. 2006. "A Questionnaire-Based Study of Gestation, Parturition and Neonatal Mortality in Pedigree Breeding Cats in the UK." *Journal of feline medicine and surgery* 8(3): 145–57.s university.

Biography

The author Partha Paul, son of Salil kanti paul and Anjana paul passed his Secondary School Certificate (SSC) examination from KPM Chandraghona, Chittagong, in 2015 and Higher School Certificate (HSC) examination from Cuet College, Chittagong in 2017. Use the "Insert Citation" button to add citations to this document.

There after, he enrolled for Doctor of Veterinary Medicine (DVM) degree in Chattogram Veterinary and Animal Sciences University (CVASU), Bangladesh and now is an intern student in this university.