

**Study on The confirmatory diagnosis and therapeutic management  
of pigeon canker**



A clinical report submitted in partial satisfaction of the  
requirement for the Degree of Doctor of Veterinary Medicine (DVM)

By:

**Swagata Das Gupta**

**Roll No: 18/11**

**Reg. No: 02068**

**Intern ID: 11**

**Session: 2017-18**

**Faculty of Veterinary Medicine**

Chattogram Veterinary and Animal Sciences University

Khulshi, Chattogram-4225, Bangladesh

**Study on The confirmatory diagnosis and therapeutic management  
of pigeon canker**



**Approved by:**

---

**Dr. A. S. M. Golam Kibria**

**Professor and Head**

**Department of Anatomy and Histology**

**Faculty of Veterinary Medicine**

Chattogram Veterinary and Animal Sciences University

Khulshi, Chattogram-4225, Bangladesh

**November 2023**

## **ACKNOWLEDGEMENT**

All praise is due to the Almighty, who created everything in nature and allowed me to complete my dissertation. It gives me great pleasure to express my gratitude to my supervisor Professor Dr. A. S. M. Golam Kibria of the Department of Anatomy and Histology at the Chattogram Veterinary and Animal Sciences University for his academic direction, suggestions, and encouragement throughout the entirety of my study.

A special thank you to Professor Dr. A. K. M. Saifuddin, Director of External Affairs, and Professor Dr. Mohammad Lutfur Rahman, Dean, Faculty of Veterinary Medicine, Chattogram Veterinary and Animal Sciences University, for their constant inspiration and suggestions, respectively.

The author is also grateful to the farm owner for his cooperation throughout the study period.

<b>Table of Contents</b>	<b>Pages</b>
ABSTRACT.....	vii
CHAPTER 1: INTRODUCTION.....	1
CHAPTER 2: METHODS AND MATERIALS .....	3
2.1 Case history.....	3
2.2 Post-Mortem examination:.....	5
2.3 Confirmatory diagnosis.....	5
2.3.1 Sample collection: .....	5
2.3.2 Microscopic observation .....	6
2.3.3 Giemsa staining: .....	7
CHAPTER 3: RESULTS.....	7
3.1 Treatment and Follow-up.....	8
CHAPTER 4: DISCUSSION .....	9
LIMITATIONS.....	10
CONCLUSION.....	12
REFERENCES .....	12
BIOGRAPHY .....	17

<b>List of Figures</b>	<b>Pages</b>
Figure 1. Greenish diarrhea found in the physical examination.	4
Figure 2. Presence of yellowish-white caseous nodules in the oral cavity.	4
Figure 3. Post-mortem lesions in domestic pigeon– A) Congested proventriculus and nodule in the crop wall. B) Hepatomegaly and Congested heart.	5
Figure 4. Collection of samples from the oropharynx and crop.	6
Figure 5. Trophozoite of <i>T. gallinae</i> .	7
Figure 6. Confirmation of Trophozoite by Giemsa staining.	7
Figure 7. After the treatment, the pigeon was successfully recovered.	8

## List of Acronyms Symbols Used

Abbreviation	Elaboration
etc.	Et cetera
et. al	And his associate
mg/kg	Milligram per kilogram
PCR	Polymerase Chain Reaction
SSC	Secondary School Certificate
HSC	Higher Secondary School Certificate
CVASU	Chattogram Veterinary and Animal Sciences University

## **Study on The confirmatory diagnosis and therapeutic management of pigeon canker**

### **ABSTRACT**

*Trichomonas gallinae* is a protozoan parasite that causes the avian trichomoniasis disease known as "canker," which primarily affects the esophagus and upper digestive tract in pigeons. A common case of pigeon cankers was diagnosed in two pigeons 40 days of age who came to S.A. Quaderi Teaching Veterinary Hospital, Chattogram Veterinary and Animal Sciences University (CVASU). Clinical history indicated that the birds were taking food and water from the same source, clinical investigations showed greenish diarrhea, postmortem studies revealed hepatomegaly, congested heart, and proventriculus, and found nodules in the crop wall as tentative diagnoses. Trophozoite was identified through microscopic examination by direct wet smear and giemsa staining. The canker was treated orally with metronidazole at a dose of 20 mg/kg body weight, and the farmer was also advised on the hygienic management of his farm. After careful treatment, all the clinically affected pigeons were cured within three days.

Keywords: Pigeon Cankers, Diagnosis, Giemsa staining, Metronidazole, Protozoa

## CHAPTER 1: INTRODUCTION

The poultry sector is the most efficient and cost-effective way to obtain animal protein in the shortest period, but due to rising future demand, it is still unable to meet the animal protein supply and demand gap. Although commercial broiler and layer farms meet the current demand for protein, consumers consider chicken meat to be repetitive and desire alternative safe meats. So many people started pigeon farming to meet consumer demand and develop economically (Paul et al., 2015). About 10.8 million pigeons resided in Bangladesh, and 11% of them were reared on commercial farms (Agricultural Sample Survey, 2013). However, these farms went unidentified. Domestic pigeons have traditionally been reared in Bangladesh for their meat. However, this pigeon has viral (25.5%), bacterial (29.28%), parasitic (31.67%), and fungal (5.18%) diseases (Paul et al., 2015). In parasitic disease, Ecto-parasitic (67%) and endo-parasitic (72%) infections are prevalent in the Chittagong district of Bangladesh (Ghosh et al., 2014). Pigeons are susceptible to a variety of health problems, with ecto and endo-parasites with a significant role (Tietz et al., 2007). The endo-parasitic diseases are caused by cestode, nematode, trematode, and protozoal. In protozoa, one important disease is Pigeon cankers caused by *Trichomonas gallinae* which is the reason for the big economic loss of farmers (Villanúa et al., 2006). The age of the host also enhanced the prevalence of infection (Bunbury et al., 2008). Overall 60% of the pigeon population in Bangladesh had cankers, of which 75%, 50%, and 44.4% were squabs, adult males, and adult females, respectively (Arfin et al., 2019). Avian trichomoniasis is caused by a flagellated protozoan named *T.gallinae* that affects the upper digestive system of numerous bird species, especially pigeons (Al-Sadi et al., 2011). It is a flagellate protozoan without a posterior flagellum but has four anterior flagella and an undulating membrane on one side. There is no intermediate host, and the life cycle is simple and direct (Bunbury et al., 2008). The domestic pigeon, *Columba livia*, is the main host of this parasite (Qiu et al., 2012). Additionally susceptible are domestic and wild turkeys, hens, and raptors such as hawks and golden eagles (Bulbul et al., 2018). It typically inhabits various bird species' upper gastrointestinal tract, particularly Columbiformes pigeons and doves (Seddiq et al., 2014). Invasion of the



oropharyngeal mucosa by the organisms results in inflammation and ulceration (Pennycott et al., 2005). Early lesions in pigeon squabs appear as small, white to yellowish spots in the oral cavity, particularly the soft palate, 3 to 14 days after infection (Bulbul et al., 2018). Which results in significant losses and high mortality, particularly in young birds. If the infection is severe and possibly fatal in young birds, mortality can be as high as 80–90% or more in squabs (Begum et al., 2008). Through pigeon milk, adults transmit *T.gallinae* through squabs (Bulbul et al., 2018), and the infection takes place in a matter of minutes and is also transmitted by direct contact with an infected bird or indirectly via contaminated food or water (Forzan et al., 2010; McDougald, 2003). In this case, the transmission was caused by contaminated drinking water. All the pigeons drank water from a common source and took feed in the same place. When it was examined under a light microscope, trichomonas are translucent tiny flagellates that can appear alone or in clusters. They move quickly (jerkily and in circles without a distinct direction, not departing the microscope field). The anti-protozoal drug was suggested for the prevention of this disease. The most used drug for treating cankers in pigeons is metronidazole (Aydın et al., 2000). So far there is a limited study on pigeon cankers in Bangladesh, and believe that this is the first case report on pigeon cankers from Chittagong in Bangladesh. The main goal of this study is laboratory diagnosis and therapeutic management of the cankers.

## CHAPTER 2: METHODS AND MATERIALS

### *2.1 Case history*

At the age of 40 days, two domestic pigeons one alive and the other dead brought to the S.A. Quaderi Teaching Veterinary Hospital at Chattogram Veterinary and Animal Sciences University (CVASU), Chattogram, Bangladesh, on 10<sup>th</sup> April 2023, with a history of about 20 pigeons 1-2 months of age started to die suddenly and described that the affected pigeons showed diarrhea, loss of appetite, gradual weight loss and only drink of water. Other clinical examination findings were greenish diarrhea (Figure 1), weakness, depression, ruffled feathers, and respiratory distress were also noted. There found many of them had some signs of difficulty while closing their mouths because of the presence of cheesy materials in the oral cavity (Figure 2). Watery eyes were apparent in pigeons due to lesions in the sinuses or tissues around the eyes. The pigeon owner came up with a history that all the birds were drinking water from a common water source and given wheat, maize, paddy, and rice together in the same place. After the Clinical history, inspection, and postmortem examination of the affected birds assumed that it could be the infection of pigeon cankers. For the confirmatory diagnosis collection of an oropharyngeal swab from the infected birds at the parasitology lab in the Department of Pathology and Parasitology (Chattogram Veterinary and Animal Sciences University, Chattogram, Bangladesh) confirmed that the infection of “pigeon cankers” which is caused by *T.gallinae*.



Figure 1: Greenish diarrhea found in the physical examination.

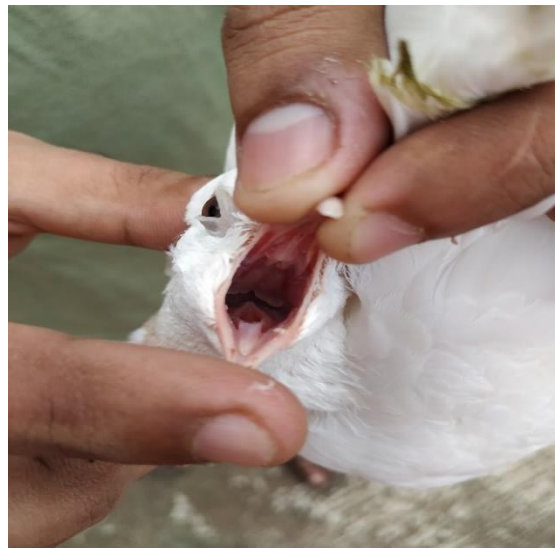

Figure 2: Presence of yellowish-white caseous nodules in the oral cavity.

## ***2.2 Post-Mortem examination:***

A post-mortem examination was done on the clinically affected dead pigeon. After the post-mortem examination of the dead pigeon, gross changes in the heart and proventriculus were found. In the crop wall nodule was visible. On palpation, it felt like a firm mobile lump. Congested heart and proventriculus were visible. Hepatomegaly was also noted (Figure 3).

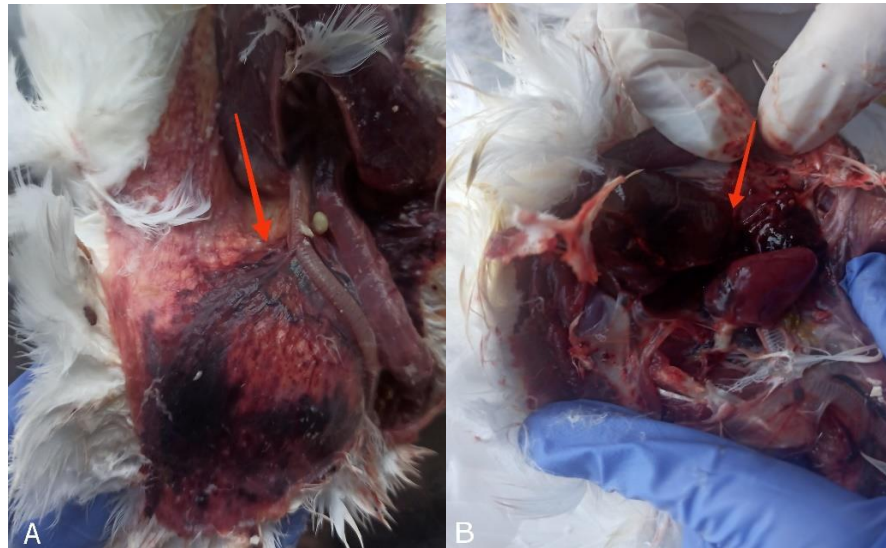

Figure 3: Post-mortem lesions in domestic pigeon– A) Congested proventriculus and nodule in the crop wall. B) Hepatomegaly and Congested heart.

## ***2.3 Confirmatory diagnosis***

### ***2.3.1 Sample collection:***

A swab sample was taken with a cotton swab from the oropharynx. Before taking the swab, the cotton bud was dipped in normal saline. Then inserted it through the mouth and gently rotated it (Figure 4). Finally, a smear was prepared on a clean glass slide and dried it.




Figure 4: Collection of samples from the oropharynx and crop.

### ***2.3.2 Microscopic observation***

Clinical signs, gross lesions, microscopic inspection, and other methods are used to diagnose the illness. Direct wet smears of organisms from the crop, and cultures formed from the mouth lesions (Anderson et al., 2009). A clean glass slide was taken, and saline smears (wet mount) were prepared on a glass slide. Then coverslip was placed on a glass slide and observed under a microscope (10x & 40x) magnification (Anderson et al., 2009; Dovč et al., 2004). Trichomoniasis can be recognized as a wriggling flagellar parasite. The trapezoid of the parasite was visible under a microscope and confirmed that it was the infection of *T.gallinae* (Figure 5).

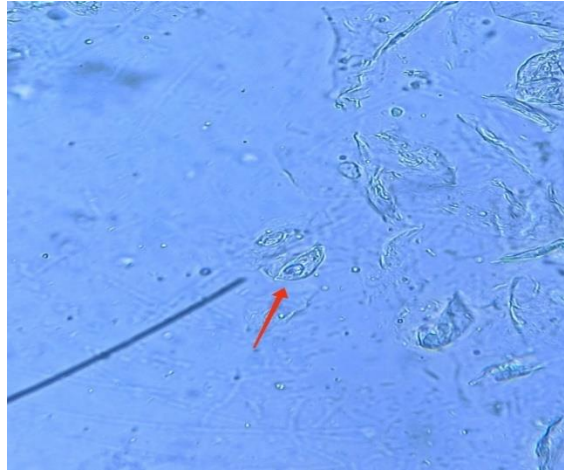


Figure 5: Trophozoid of *T. gallinae*.

### **2.3.3 Giemsa staining:**

For further confirmation, giemsa staining was performed in the laboratory and observed under the microscope (100x) magnification using immersion oil.

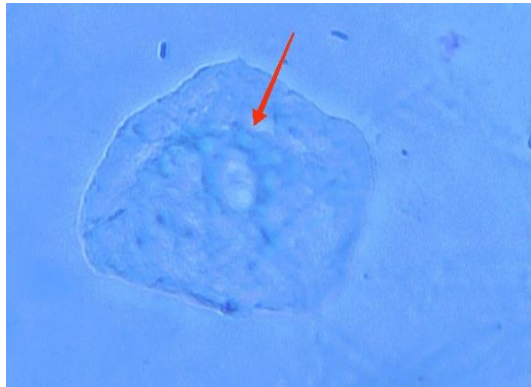


Figure 6: Confirm of Trophozoite by Giemsa staining.

## CHAPTER 3: RESULTS

### *3.1 Treatment and Follow-up*

The pigeon was treated with Metronidazole (20 mg/kg once daily) for constructive 3 days as a specific etiological treatment and advised to provide feed, and fresh water separately. It reduced the contamination on the premises. The mortality of the pigeon decreased following the first day of treatment. All of the pigeons were successfully cured without any difficulties within 3 days. After 14 days of recovery, the sample was collected again from the oral cavity to crop which was examined under a microscope and found negative results. The pigeons were recovered with no evidence of mortality and diarrhea (Figure 7).



Figure 7: After the treatment, the pigeon was successfully recovered.

## CHAPTER 4: DISCUSSION

Young pigeons called "squabs" are frequently infected with *T. gallinae* and can develop the infection to the point of death, although adult and recovery pigeons can act as carriers while exhibiting no clinical signs (Bunbury et al., 2008, Mohamed et al., 2022). The clinical sign of this disease is greenish fluid or cheesy materials in the mouth and crop and it is a common lesion for all cankers cases. In the current study greenish diarrhea, ruffled feathers, weakness, and depression were also visible which is similar to Paul et al. (2015). There is a dissimilarity with Kennedy, (2001) claimed that canker damages the tissues of the mouth, throat, crop, and esophagus and affected birds may drool saliva which was not found in this study. The oral lesions started as little white caseous nodules, which expanded into large yellowish-white caseous nodules over time (Figure 2), Similar findings were noted by Fadhil et al. (2020). Infection can also come through contaminated water and food (Bunbury et al., 2007, Forzan et al., 2010; McDougald, 2003). According to Forzan et al. (2010) in the post- mortem examination, a mass of necrotic materials is initially discovered in the mouth and esophagus, This study also supports the authors, that the wall of the crop nodule was visible. On palpation, it felt like a firm mobile lump which was supported by Pennycott et al. (2005) and Grunenwald et al. (2018) but there were no yellowish lesions found in the esophagus which was described by this author. In several cases, liver abscesses are prominent which indicates the infection of cankers, and due to abscess pigeon can die within a few days (Bulbul et al., 2018). Ali et al. (2014) found encephalopathies, brain dysfunction, and as well as cerebral congestion which were not present in this case. Hepatomegaly was found in this case because the organism may enter the pharyngeal gland, penetrate the undulating tissue, and reach the liver. Furthermore, due to the similarities in liver lesions, histomoniasis, and trichomonosis have occasionally been mistaken for one another, which was seen in this case (Bulbul et al., 2018). In this case, the organism was detected by wet smear methods and giemsa staining method which is supported by the authors Anderson et al. (2009); Hamad and Hasan, (2017). Moreover, it can be confirmed by histopathology (Bunbury et al., 2008, Arenales et al., 2014) and molecular technique which is performed by PCR (Höfle et al., 2004, Mohamed et al.,



2022, Qiu et al., 2017). According to Bulbul et al. (2018) and Raza et al. (2018), the culture technique such as artificial and diamond media is also used to detect *Trichomonas*. Using a hemocytometer (Neubauer Improved, Germany) at a 40x magnification, migrating trophozoites were counted according to Hamad and Hassan, (2017). There are mainly two drugs used worldwide for the treatment of cankers Metronidazole and Ronidazole. In the current case, metronidazole was used and found effective results, which support the author of Aydın et al. (2000). They used metronidazole and found a positive result which is similar to this study. It works by inhibiting protein synthesis after diffusion through the organism. Metronidazole interacts with organisms' DNA and causes the breakdown of DNA strands. As a result, the organism dies due to cell death. But Bulbul et al. (2018) used 2-Amino-5-nitro thiazole (45 mg/kg body weight for other birds and 30 mg/kg daily for 7 days for homing pigeons), carnidazole (10 mg/kg body weight), metronidazole (60 mg/kg body weight), and dimetridazole (50 mg/kg body wt, PO; or in the drinking water at 0.05% for 5–6 days). In this study collection of swabs from a recovered bird after 14 days of follow-up found negative results which was similar to the author Seddiek et al. (2014) who claimed that after 5 and 7 days of Metronidazole treatment, 100% of the birds had recovered and all trophozoites had been eliminated.

## **LIMITATIONS**

The report would be more informative if additional techniques, such as PCR and culture, could be employed. One farm was used to conduct the experiment. The goal of this study would be much more effectively achieved if additional farms were included.

## **CONCLUSION**

This case report narrates the diagnosis and therapeutic management of cankers in pigeons. This case was diagnosed mainly based on clinical history, physical and parasitological examination. The affected pigeons were observed regularly after the administration of metronidazole from day 1<sup>st</sup> to the 3<sup>rd</sup>. Pigeons were fed separately and ensured the fresh water source.

## REFERENCES

- Ali, H. A., Ramadan, M. Y., and Ata-Allah, A. M. (2014). Biochemical effects of *Trichomonas Gallinae* on pigeons reared on irrigation channels water and water treated with anti-protozoal agents. *Benha Veterinary Medical Journal*, 27, 150-156.
- Al-Sadi, H. I., and Hamodi, A. Z. (2011). Prevalence and pathology of trichomoniasis in free-living urban pigeons in the city of Mosul, Iraq. *Veterinary World*, 4(1), 12.
- Anderson, N. L., Grahn, R. A., Van Hoosear, K., and BonDurant, R. H. (2009). Studies of trichomonad protozoa in free ranging songbirds: prevalence of *Trichomonas gallinae* in house finches (*Carpodacus mexicanus*) and corvids and a novel trichomonad in mockingbirds (*Mimus polyglottos*). *Veterinary Parasitology*, 161(3-4), 178-186.
- Arenales, A., Almeida, A. C. O., Prado, L. F., Garcia, S., and Luvizotto, M. C. R. (2014). Cytopathology in the diagnosis of oral trichomoniasis in a rock pigeon (*Columba livia*). *Brazilian Journal of Veterinary Pathology*, 7(2), 98-99.
- Arfin, S., Sayeed, M. A., Sultana, S., Dash, A. K., and Hossen, M. L. (2019). Prevalence of *Trichomonas gallinae* infection in pigeon of jessore district, Bangladesh. *Journal of Advanced Veterinary and Animal Research*, 6(4), 549.
- Aydın, L., Coşkun, Ş., and Güleğen, E. (2000). Efficacy of carnidazole (Spatrix®) and metronidazole (Flagyl®) against *Trichomonas gallinae* in naturally infected pigeons. *Acta Parasitologica Turcica*, 24(1), 65-66.
- Begum, N., Mamun, M. A. A., Rahman, S. A., and Bari, A. S. M. (2008). Epidemiology and pathology of *Trichomonas gallinae* in the common pigeon (*Columba livia*). *Journal of the Bangladesh Agricultural University*, 6(452), 2016-35515.
- Bulbul, K. H., Shahardar, R., Allaie, I. M., Wani, Z. A., Tramboo, S. R., Ashraf, A., and Shubeena, S. (2018). Avian trichomonosis with special reference to

- pigeon. *International Journal of Veterinary Sciences and Animal Husbandry*, 3, 11-13.
- Bunbury, N., Jones, C. G., Greenwood, A. G., and Bell, D. J. (2007). *Trichomonas gallinae* in Mauritian columbids: implications for an endangered endemic. *Journal of Wildlife Diseases*, 43(3), 399-407.
- Bunbury, N., Jones, C. G., Greenwood, A. G., and Bell, D. J. (2008). Epidemiology and conservation implications of *Trichomonas gallinae* infection in the endangered Mauritian pink pigeon. *Biological Conservation*, 141(1), 153-161.
- Bunbury, N., Stidworthy, M. F., Greenwood, A. G., Jones, C. G., Sawmy, S., Cole, R. E., and Bell, D. J. (2008). Causes of mortality in free-living Mauritian pink pigeons *Columba mayeri*, 2002–2006. *Endangered species research*, 9(3), 213-220.
- Dovč, A., Zorman-Rojs, O., Vergles Rataj, A., Bole-Hribovšek, V., Krapež, U., and Dobeic, M. (2004). Health status of free-living pigeons (*Columba livia domestica*) in the city of Ljubljana. *Acta Veterinaria Hungarica*, 52(2), 219-226.
- Fadhil, L. T., Faraj, A. A., and AL-Amery, A. M. (2020). *Trichomonas gallinae* identification and histopathological study in pigeon (*Columba livia domestica*) in Baghdad city, Iraq. *The Iraqi Journal of Veterinary Medicine*, 44: 57-63.
- Forzan, M. J., Vanderstichel, R., Melekhovets, Y. F., and McBurney, S. (2010). Trichomoniasis in finches from the Canadian Maritime provinces an emerging disease. *The Canadian Veterinary Journal*, 51(4), 391.
- Ghosh, K. K., Islam, M. S., Sikder, S., Das, S., Chowdhury, S., and Alim, M. A. (2014). Prevalence of ecto and gastrointestinal parasitic infections of pigeon at Chittagong Metropolitan Area, Bangladesh. *The Journal of Advances in Parasitology*, 1(1), 9-11.
- Grunenwald, C., Sidor, I., Mickley, R., Dwyer, C., and Gerhold, R. (2018). Tetratrichomonas and trichomonas spp.-associated disease in free-ranging common Eiders (*Somateria*

- mollissima) from Wellfleet Bay, MA and description of ITS1 region genotypes. *Avian diseases*, 62(1), 117-123.
- Hamad, S. S., and Hassan, H. H. (2017). Isolation, diagnosis and cultivation of *Trichomonas gallinae* from domestic pigeon in Kirkuk City, Iraq. *International Journal of Current Research Academic Review*, 5(2), 10-18.
- Höfle, U., Gortázar, C., Ortiz, J. A., Knispel, B., and Kaleta, E. F. (2004). Outbreak of trichomoniasis in a woodpigeon (*Columba palumbus*) wintering roost. *European Journal of Wildlife Research*, 50, 73-77.
- Kennedy, M. J (2001). *Trichomoniasis in Birds*" Food Safety Division, Alberta Agriculture and Food. *Agdex*, 663-634
- McDougald, L. R. (2003). *Diseases of poultry*, 11st Edit. Editorial Broad for American Association of Avian Pathogenesis, 1006-1011.
- Mohamed, H. M., Saad, A. S., Khalifa, M. M., Abdel-Maogood, S. Z., Awadalla, S. M., and Mousa, W. M. (2022). Detection and molecular characterization of *Trichomonas gallinae* recovered from domestic pigeons in Egypt. *Parasitology Research*, 122(1), 257-263.
- Paul, T. K., Amin, M. R., Alam, M. A., Rahman, M. K., Sarker, Y. A., and Rizon, M. K. (2015). Occurrence of pigeon diseases at Khulna Sadar, Bangladesh. *Bangladesh Journal of Veterinary Medicine*, 13 (2), 21-25
- Pennycott, T., Lawson, B., Cunningham, A., Simpson, V., and Chantrey, J. (2005). Necrotic ingluvitis in wild finches. *The Veterinary Record*, 157(12), 360.
- Qiu, S. B., Lv, M. N., He, X., Weng, Y. B., Zou, S. S., Wang, X. Q., and Lin, R. Q. (2017). PCR identification and phylogenetic analysis of *Trichomonas gallinae* from domestic pigeons in Guangzhou, China. *The Korean journal of parasitology*, 55(3), 333.
- Qiu, S. B., Yan, C., Zhou, D. H., Hou, J., Wang, Q. Q., Lin, Y., and Lin, R. Q. (2012). High prevalence of *Trichomonas gallinae* in domestic pigeons (*Columba livia domestica*)

in subtropical southern China. *African Journal of Microbiology Research*, 6(6), 3261-3264.

Raza A., Qamar MF., Rubtsova N., and Saneela S., (2018). Pathogenicity and diagnostic sensitivity of culture media for identification of *Trichomonas gallinae* in Domestic Pigeons of Lahore, Pakistan *Journal of Protocol Research*, 28(2), 11-21.

Seddiek, S. A., El-Shorbagy, M. M., Khater, H. F., and Ali, A. M. (2014). The antitrichomonal efficacy of garlic and metronidazole against *Trichomonas gallinae* infecting domestic pigeons. *Parasitology Research*, 113, 1319-1329.

Tietz Marques, Sandra., Marinho de Cuadros, Rosileia Jardim da Silva, Cintia., and Baldo, M. (2007). Parasites of pigeons (*Columba livia*) in urban areas of lages, Southern Brazil. *Parasitología latinoamericana*, 62(3-4), 183-187.

Villanúa, D., Höfle, U., Perez-Rodriguez, L. O., and Gortázar, C. (2006). *Trichomonas gallinae* in wintering common wood pigeons *Columba palumbus* in Spain. *Ibis*, 148(4), 641-648.

## **BIOGRAPHY**

I am Swagata Das Gupta. I passed my secondary school certificate (SSC) in 2014 with a GPA of 5.00 from Dr. Khastagir Government Girls' High School and my higher school certificate (HSC) in 2016 with a GPA of 4.83 from Govt. Hazi Muhammad Mohsin Collage, Chattogram. I was admitted to Chattogram Veterinary and Animal Sciences University in 2018 and at present, I am an intern student of the 23rd batch under the Faculty of Veterinary Medicine at CVASU. I would like to pursue my higher education in Microbiology and Veterinary Public Health in the near future.