

**Macroscopic and Microscopic Anatomy of Some Organs of
an Adult Oriental Magpie-robin (*Copsychus saularis*)**



Submitted by:

Name: Labannya Dutta Tithi

Roll No: 18/14

Registration No: 02072

Intern ID: 13

Session: 2017-2018

A clinical report submitted in partial satisfaction of the requirement for
the Degree of **Doctor of Veterinary Medicine (DVM)**

**Faculty of Veterinary Medicine
Chattogram Veterinary and Animal Sciences University
Khulshi, Chattogram – 4225, Bangladesh**

October, 2023

**Macroscopic and Microscopic Anatomy of Some Organs of
an Adult Oriental Magpie-robin (*Copsychus saularis*)**



Approved by:

Dr. Subrata Kumar Shil

Associate Professor

Department of Anatomy and Histology

Faculty of Veterinary Medicine

Faculty of Veterinary Medicine

Chattogram Veterinary and Animal Sciences University

Khulshi, Chattogram – 4225, Bangladesh

October, 2023

List of Contents

No. of Chapters	Name of Chapters	No. of Pages
	List of Figures	
	Abstract	
Chapter 1	Introduction	1-3
Chapter 2	Materials and Methods	3-4
Chapter 3	Results	4-11
Chapter 4	Discussion	12-13
Chapter 5	Limitations	13
Chapter 6	Conclusion	13
Chapter 7	References	14-16
	Acknowledgments	17
	Biography	18

List of Figures

No. of Figures	Name of Figures	No. of Pages
1	Distribution of Oriental Magpie Robin worldwide	1
2	External morphology of a female Oriental Magpie Robin	5
3	Syrinx, Trachea, Intestine	6
4	Ovary	6
5	Microphotograph of trachea in 10x	7
6	Microphotograph of trachea in 40x	7
7	Microphotograph of the lung in 4x.	7
8	Microphotograph of the lung in 10x.	7
9	Microphotograph of lung in 10x showing parabronchi	8
10	Microphotograph of the lung in 40x.	8
11	Microphotograph of heart in 4x.	8
12	Microphotograph of heart in 10x.	8
13	Microphotograph of heart in 40x.	9
14	Microphotograph of small intestine in 10x	9
15	Microphotograph of small intestine in 40x	9
16	Microphotograph of large intestine in 10x	10
17	Microphotograph of large intestine in 40x	10
18	Microphotograph of ovary in 4x	11
19	Microphotograph of ovary in 10x	11
20	Microphotograph of ovary in 40x	11

Abstract

The gathering and analysis of field data on various facets of bird life is thought to be essential for the advancement of ornithological study. The Oriental Magpie-Robin is renowned for its distinctive and beautiful vocalizations, although research on it is extremely underdeveloped. This study aims to comprehend the gross and microscopic anatomy of the tropical songbird Oriental Magpie Robin (*Copsychus saularis*). It is the national bird of Bangladesh. It is a medium-sized passerine bird where males have a white and black combination of plumage and in females, the black part is replaced by grayish brown. This study showed that it is smaller in size and weight. Some similarities and dissimilarities have been found with other birds throughout the whole study. Some important organs like the trachea, lung, heart, small intestine, large intestine, and ovary were emphasized during the study period. This study also provided proof of its having syrinx on the base of the tracheal bifurcation for which it is known as a songbird. Investigation of lungs, and heart showed similarities of histological aspects with other birds like chickens, Iraqi pigeons, etc. Ovarian follicles provided information on atretic follicles that matched with the data found on laying hens. Aspects of histology of the intestine showed a resemblance with the data found on the English sparrow which is also a passerine bird. This work may mark the start of a new phase in the study of Oriental Magpie Robins. It can largely assist our doctors and conservationists in taking further actions for the diagnosis of diseases and observing the conservation of this species. If not, the population of the species will begin to decline, which may lead to an ecological imbalance.

Keywords: Oriental Magpie Robin, *Copsychus saularis*, tropical songbird, passerine, syrinx, conservation.

Chapter 1

Introduction

Oriental Magpie Robins are considered the national bird of Bangladesh. They are called songbirds and go by the name Doyel or doel. They are extremely intelligent and can mimic the songs of other birds. They are found in Bangladesh, India, Singapore, southern China, Sri Lanka, Malaysia, eastern Indonesia, and eastern Pakistan. They frequently coexist with people in urban, suburban, and rural regions despite their tendency to be reticent birds.

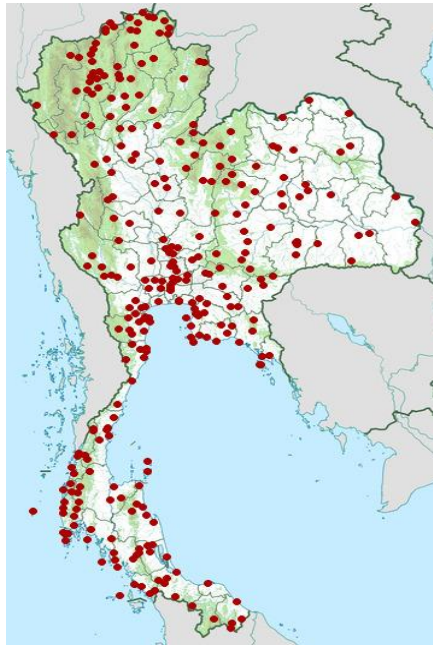


Fig 1: Distribution of Oriental Magpie Robin worldwide.

They belong to the *Copsychus* genus of insectivorous birds [Jobling et al, 1991]. Some species also eat berries and other fruits. Now considered to be a member of the Old-World flycatcher family Muscicapidae, they were earlier classified as members of the thrush family Turdidae. The name *Copsychus* is derived from the Ancient Greek “kopsukhos” or “kopsikhos”, which means "blackbird" [Jobling et al, 2018]. The Oriental magpie-robin (*Copsychus saularis*) was named by the English zoologist George Robert Gray in 1840 [Mayr et al, 1964; Gray et al, 1840].

Individually, in couples, or in small family groups, these birds can be found. Adult small to medium-sized robins (doel) have outer tail feathers and a broad white wingbar from the shoulder to the tip of the wing. While females are brownish-greyish-white, males fly around in a black-and-white display. They are usually observed close to the ground, hopping along branches, or feeding in leaf litter with a cocked tail. They occasionally take a bath in the rainwater that has gathered on the leaves. They have a unique, lovely song of their own. They can whistle regrettably and produce loud, alarming notes with a raspy quality. Beautiful melodies and a variety of calls, such as territorial calls, emergence, and roosting calls, threat calls are used by these birds to communicate with one another. During the breeding season, males can be heard singing loudly from higher perches or the tops of trees. They usually eat insects, but some species also eat berries and other fruits. This bird is widespread and locally abundant across its range, according to the IUCN Red List, but there is no estimate of its total population. Despite being one of the species with the "least concern" in the entire world, it is dwindling in some places. For the cagebird trade, the species is being trapped and exploited to some extent. They were prevalent in Singapore in the 1920s but went extinct in the 1970s, perhaps as a result of competition from newly introduced common mynas [Huong SL, Sodhi NS, 1997]. Again, due to habitat degradation, and hunting in Singapore, the species had previously been in decline [Collar et al, 2020]. Varied diets and dominant position in food webs are particularly the reasons for birds being vulnerable to environmental changes. To detect the changes and save this species from extinction in the near future, it is obvious to study the macroscopic and microscopic descriptions of the organs of the body. On this subject, not much research has been done. Recently, an adult female Oriental Magpie Robin has allowed us to describe various organs anatomically and histologically, with comparisons to and differences from those found in domestic birds. This could aid in our comprehension of the pathological and physiological state of this species.

Objectives:

- To identify the macroscopic and microscopic characteristics that are specific to this species and how they compare to those of other avian species.

- To provide a baseline study for future investigation on the pathological state of the species, which could aid in its conservation.

Chapter 2

Materials and Methods

2.1 Bird: One of our doctors recently discovered a dead Oriental Magpie Robin in a jungle close to DC Hill in the Chattogram Metropolitan region. One day after its demise, it was placed in a polythene bag and transported to the Chattogram Veterinary and Animal Sciences University (CVASU) through an icebox. Consequently, the organs have already begun to deteriorate. A postmortem team of experts was assembled, and they inspected the bird. It was 26 grams in weight and could be identified as an Oriental Magpie Robin by its distinguishing characteristics. A glossy black head, dark grey breast, upperparts with white underparts, long white bars on wings, and a black tail with white outer tail feathers were characteristics that helped identify it [Ali & Ripley, 2001]. Furthermore, the ovaries of the bird were visible during dissection, confirming that it was a female. The cause of death was unknown, and a necropsy revealed no pathognomonic lesions.

2.2 Sample Collection and Biometry: The postmortem examination was conducted according to standard procedure [Van Riper III et al,1980; Rae and M, 2006]. A measuring tape, slide calipers, and scale were used to perform in-situ and ex-situ biometry on several organs.

2.3 Histological Slide Preparation: The study of tissues and how they are arranged to form organs is done through histology [Junqueira, L. C., & Carneiro, J., 1985; Gartner, L. P. 2007]. Some organs were preserved in 10% neutral buffered paraffin for creating histology slides, which was followed by dehydration, washing, and embedding in paraffin. For microscopic examination, 5µm thick

serial paraffin slices were stained with eosin and hematoxylin [Bancroft et al, 2013].

Chapter 3

Results

3.1 External Morphology: The bird was 19 cm long and weighed about 26gm.

The entire head, upper body, and bottom margin of the breast with a square cut are mid-grey in color. The white coverts and scapulars of secondaries 6-7 formed a lengthy bar that ran over the interior of the closed wing. Black matte covers all other flight feathers. 1-3 tail feathers had a matte black color, whereas 4-6 were entirely white. The upper tail coverts and rump gradually darkened to a slaty black color, never as vividly black as the male counterpart. White made up the remaining underparts. The buff-colored lower tail coverts and flanks varied in the wash. The upper and lower beak lengths were 1.5cm, tail length was 7 cm. The wing length was 12cm for both the right and left wings. Legs were about 7.5 cm and in both legs, 1st digit had a single phalanx, 2nd digit had 2 phalanges, 3rd digit had 3 phalanges and 4th one had 4 phalanges, with no presence of spur.




Fig 2: External morphology of a female Oriental Magpie Robin. a) upper and lower beak b) wing c) tail

3.2 Macroscopic Description of Some Organs: As the death of the bird occurred 1 day before it was taken to the lab, many organs were not in the actual shape due to the start of decomposition. The following organs that worked well for the measurements:

3.2.1 From Respiratory System:

Trachea: The length of the trachea with syrinx was 4.5 cm. At the bifurcation of the trachea, the syrinx was made up of soft tissue including muscles, connective tissue, nerves, blood vessels, and cartilages. It weighed roughly 0.18 gm.

Lung: Each lung weighed roughly 0.15 g. The width of the lung was 5.07 mm and the length was 10.27 mm. Strong consistency, spongy appearance, and rib adhesion are seen after necropsy—impression on the lung created because of the rib adhesion.

3.2.2 From Cardiovascular System

Heart: It was about 0.19gm in weight. The length of it was 10.10mm and at the base, the diameter of it was 6mm. The heart was found to be somewhat to the right of the midline during necropsy.

3.2.3 From Digestive System

Liver: The measurement of it could not be taken properly as the organ was ruptured. The correct structure of it was deteriorated. We were able to take the weight of it which was 0.51gm.

3.2.4 From Urinary System

Kidney: The length of both kidneys was 10.17mm and the width was 5.38mm. It weighed about 0.51gm.

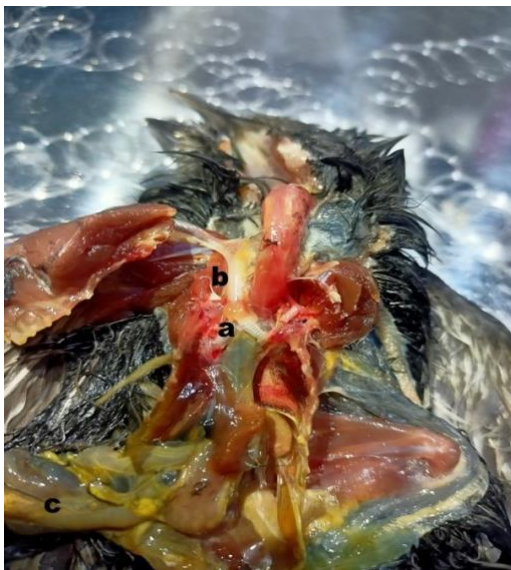


Fig 3: a) Synx b) Trachea c) Intestine

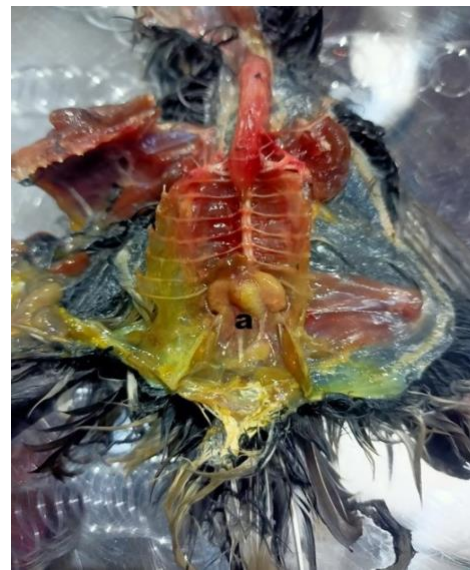

Fig 4: a) Ovary

3.3 Microscopic Description of Some Organs:

3.3.1 From Respiratory System:

Trachea: The histological findings of the trachea revealed that it was lined with ciliated pseudostratified columnar epithelium, and the lamina propria was a loose connective tissue made up of collagen bundles and blood vessels. There was the presence of a submucosa layer and hyaline cartilage tissue as well.

Lung: The parabronchi or tertiary bronchi, which are generated in the core of the pulmonary lobule and separated by the interlobular septa or septa interparabronchialia, are the histological characteristics of the lungs. Arterioles, venules, and nerve fibers can be found in these septa. Polygonal

out pouches (atria), which branch through funnel-shaped ducts (infundibula), bulge into the parabronchial wall from the parabronchial lumen and the air capillaries (pneumocapillaries). In the wall of the parabronchi, blood capillaries and air capillaries exchange gases. We found that parabronchi were lined with simple squamous epithelia to facilitate gaseous exchange in the lungs and blood vessels were encircled by connective tissue.

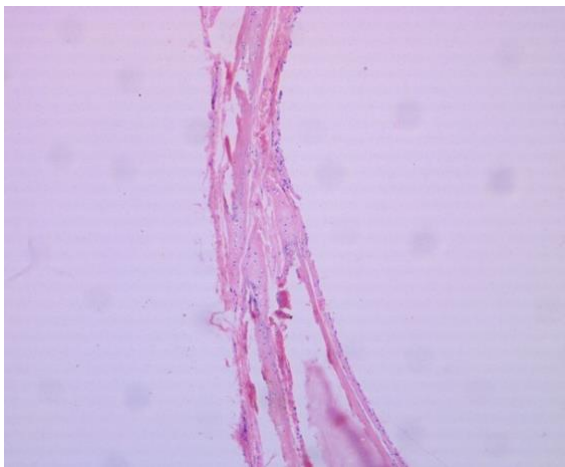


Fig 5: Microphotograph of trachea in H and E stain, 10x.

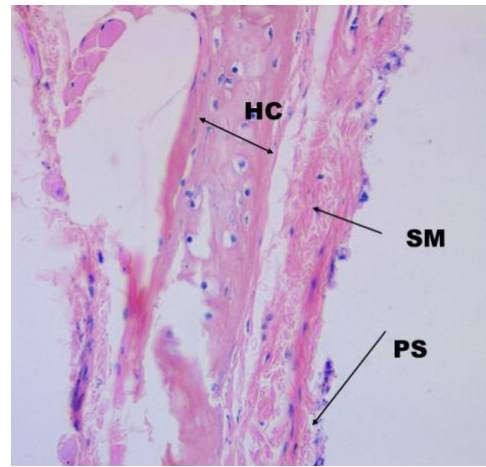


Fig 6: Microphotograph of trachea in H and E stain, 40x, showing that the lining epithelium is pseudostratified columnar epithelium (PS) then submucosa layer (SM) and Hyaline cartilage (HC).

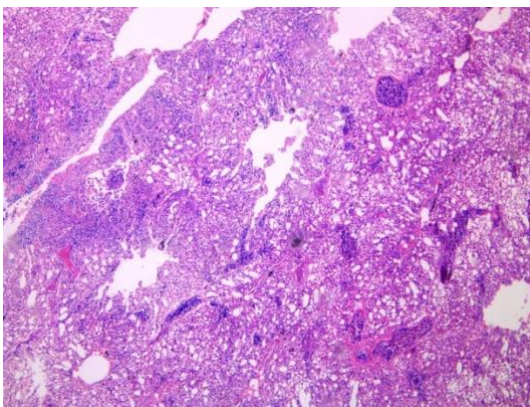


Fig 7: Microphotograph of lung in H and E stain, 4x.

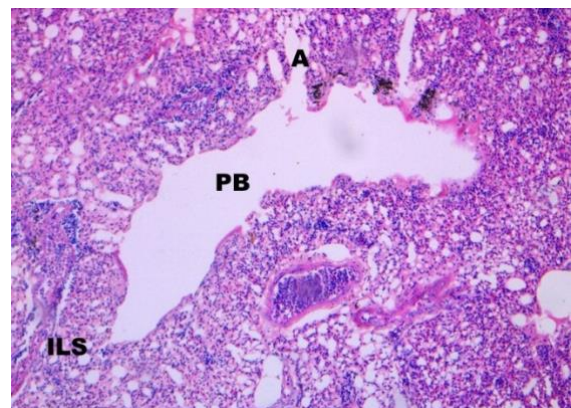


Fig 8: Microphotograph of lung in Hand E stain, 10x showing Parabronchi (PB), Atria (A), Interlobular septa (ILS).

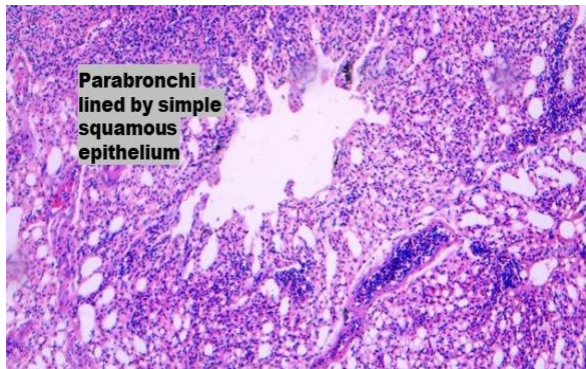


Fig 9: Microphotograph of Lung in H and E stain, 10x showing lining epithelium of parabronchi is simple squamous epithelium

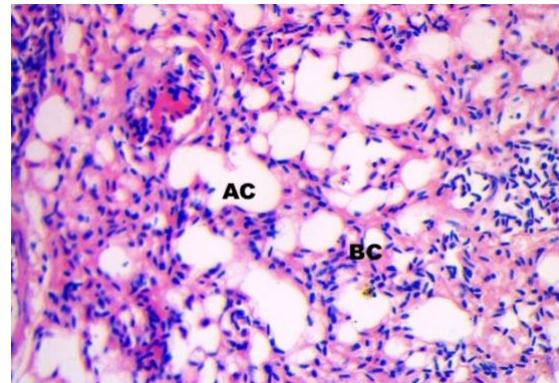


Fig 10: Microphotograph of lung in H and E stain, 40x showing air capillaries (AC) and Blood capillaries (BC).

3.3.2 From Cardiovascular System:

Heart: Histologically, connective tissue and cardiomyocytes make up the majority of the heart. The epicardium, which is made up of a layer of mesothelial cells covering adipose and connective tissue, is the outermost layer. The cardiac wall is constructed from the union of cardiomyocytes. Similar to the myocytes of skeletal muscle, these cardiomyocytes are striated. Due to the arrangement of thick and thin myofilaments within the myocytes, cardiac muscle is striated. They are mononucleated and branching, unlike skeletal muscle cells. The nuclei are located centrally unlike skeletal muscle, where the nuclei are found peripherally.

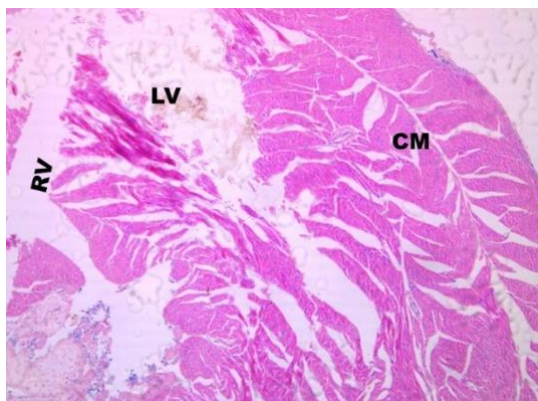


Fig 11: Microphotograph of heart in H and E stain, 4x showing cardiac muscle (CM), left ventricle (LV) and right ventricle (RV).

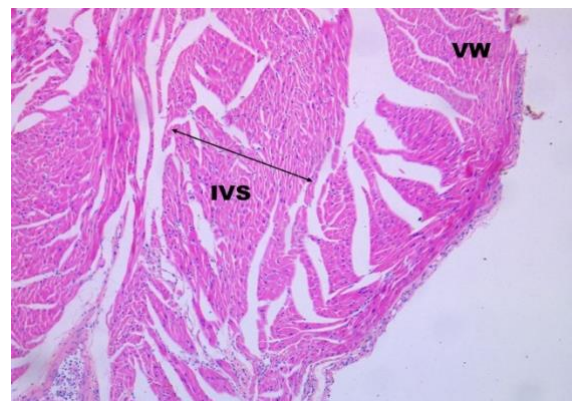

Fig 12: Microphotograph of heart in H and E stain, 10x showing ventricular wall (VW) and interventricular septum (IVS).

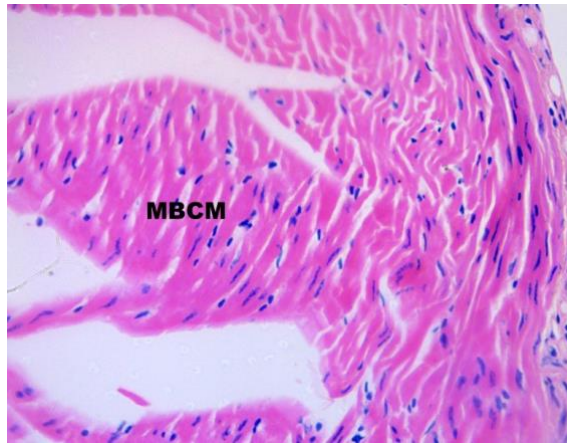


Fig 13: Microphotograph of heart in H and E stain, 40x showing mononucleated branched cardiomyocytes (MBCM).

3.3.2 From Digestive System:

Small Intestine: In the small intestine, there are four well-known classic layers. Mucosa, submucosa, muscularis, and serosa are these. The mucosa layer is made up of finger-shaped mucosal projections comprised of lamina propria and simple columnar cells that make up the lining epithelium and goblet cells. Due to the deterioration of the tissue, the villi and other parts of the organ got distorted. So, it had become difficult to identify whether it was the duodenum jejunum or ileum. But seeing the mucus glands or Brunner's glands in the submucosal layer, we confirmed it to be the duodenum of the small intestine. Usually, the submucosa is made up of irregular, dense connective tissue. Under the submucosa, the muscular portion is made up of two layers of smooth muscle fibers (inner circular and outer longitudinal layers).

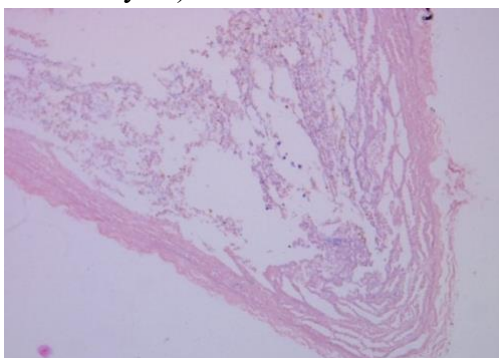


Fig 14 Microphotograph of small intestine in H and E stain, 10x where the villi are distorted.

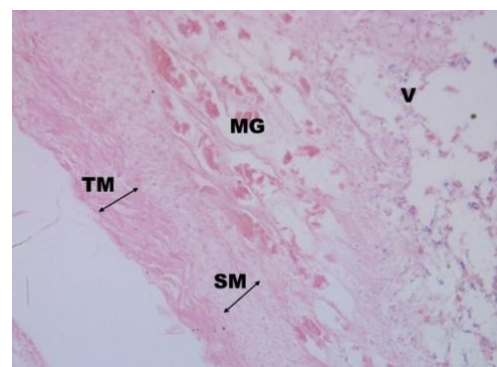


Fig 15: Microphotograph of small intestine in H and E stain, 40x where mucus glands (MG) or Brunner's glands helped to identify the portion as the duodenum. Also, there are presence of distorted villi (V), submucosa (SM) and tunica muscularis (TM).

Large Intestine: Histologically 4 layers are found in the large intestine similar to the small intestine and those are mucosa, submucosa, muscularis, and serosa. As most of the parts were ruptured and decomposed seriously, it was hard for us to identify which portion of the intestine it was. As there were no villi and goblet cells were more in number, we were enabling to detect it as a large intestine.

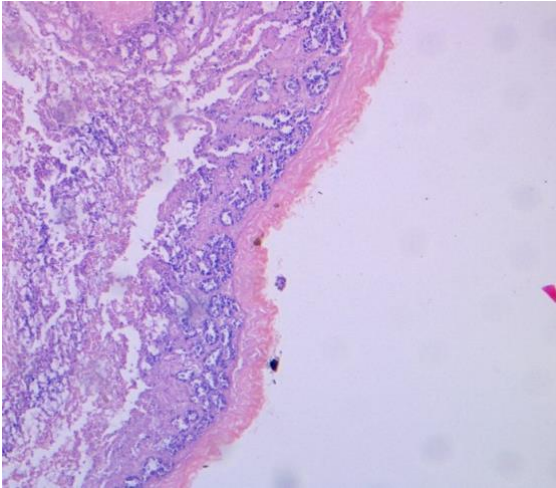


Fig 16: Microphotograph of large intestine in H and E stain, 10x where it is seen that there are no villi.

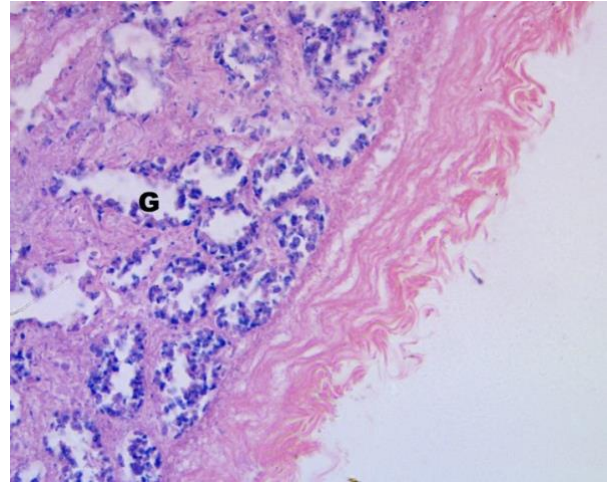


Fig 17: Microphotograph of large intestine in H and E stain, 40x where goblet (G) cells are abundant in number.

3.3.3 From Genital System:

Ovary: The outer cortex and inner medulla of the ovum are two distinct regions. There are follicles in the cortex which is a large peripheral zone. Blood, lymph, and nerve vessels are all present in the medulla. Primordial, primary, secondary, and tertiary follicles are developed in the order of the follicular development. After the preparation of the slide of the ovary, we found several growing follicles and mature or Graafian follicles. Atretic follicle is also found which is considered to be the fate of follicles. Another fate of these follicles can be considered ovulation. Atretic follicles cannot ovulate.

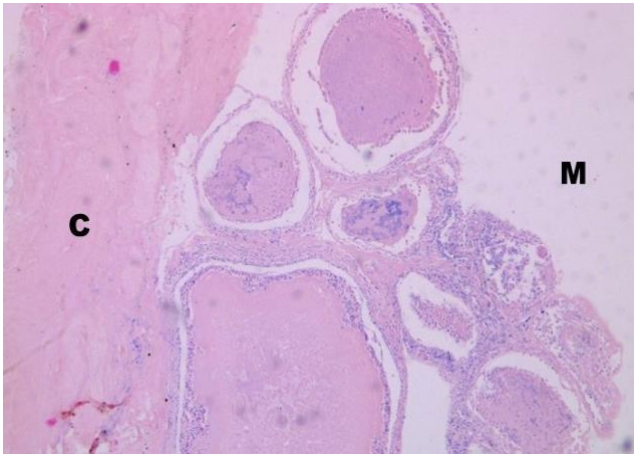


Fig 18: Microphotograph of ovary in H and E stain, 4x showing cortex and medulla.

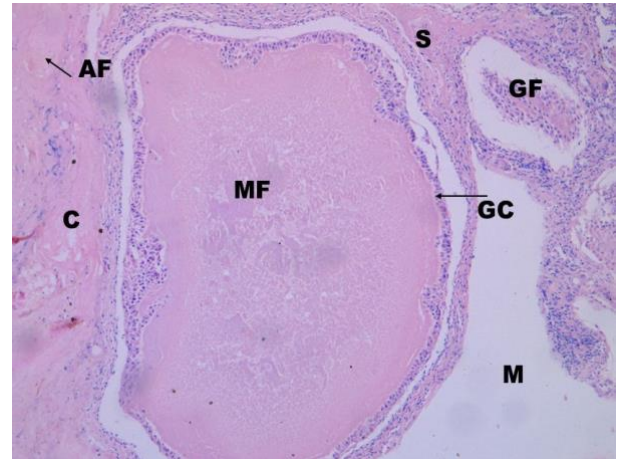


Fig 19: Microphotograph of ovary in H and E stain, 10x showing mature follicle (MF), growing follicle (GF), stroma (S), granulosa cell layer (GC), atretic follicle (AF), cortex (C) and medulla (M).

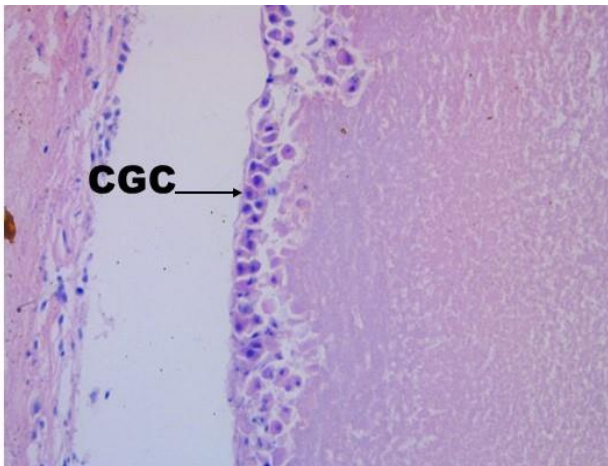
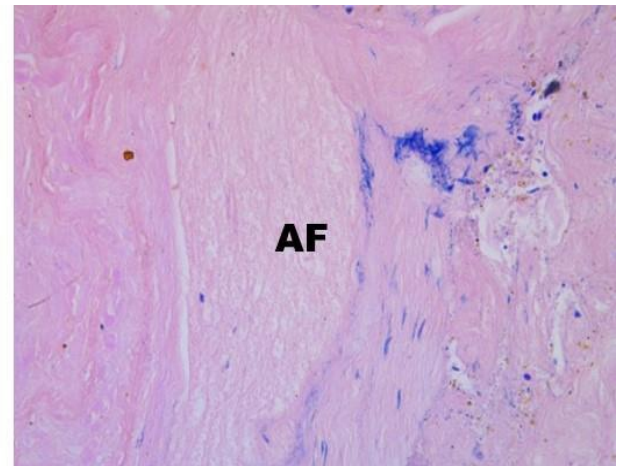


Fig 20: Microphotograph of ovary in H and E stain, 40x showing cuboidal granulosa cell layer (CGC) and atretic follicle (AF)



Chapter 4

Discussion

Throughout the entire study, we discovered several parallels and differences between the Oriental Magpie Robin and other birds. According to the exterior morphology of the Oriental Magpie Robin, they are smaller than chickens and measure around 19 cm in total length which is supported by the book called “Birds of South-East Asia” [Robson C, 2015]. According to Britannica, old-world birds that are referred to as songbirds have syrinx. As Oriental Magpie Robin is a songbird and syrinx is seen at the base of the trachea during the investigation of its anatomy after postmortem, it is confirmed that the data agrees with Britannica. Spongy look and rib adhesion were visible on the lungs. In *Color Atlas Of Veterinary Anatomy*, this statement is supported. Baumelet et al,1993 stated the same theory of lung. Spur in the toe which is an essential part of chicken was not found in the Oriental Magpie Robin. The heart was found to be relatively positioned on the right side of the midline during dissection. This statement is somewhat similar to the theory of Pees et al, 2009 and Ross et al, 2006. Now if we check the microscopic features of this bird, we will find some resembled data. In the case of the respiratory system, we found from the histological slides that there are three layers- mucosa, submucosa, and hyaline cartilage tissue in the case of the trachea. This information is supported by AL-Taai and S. A.,2021 through the journal where similarities are found with adult Iraqi pigeons. The lining of parabronchi is agreed upon by Sereno et al, 2008 and Mclelland, 1990 who stated that the parabronchi should be lined with squamous cells for the gaseous exchange and divided by interlobular septa. Mesothelial cells make up the epicardium of the heart, which was discovered during the study period in the case of the heart. Epithelial cells from the mesoderm make up these cells. Normally, the lining of body cavities is formed by this cell layer. This observation is supported by Dyce K.M. et al, 2009. Folker, E. S and Baylies, M. K., 2013 stated that nuclei of cardiomyocytes are positioned centrally. This is also similar to the case of our histological investigation of cardiomyocytes of the heart of Oriental Magpie Robin. From a digestive portion of the study, it was not easy to collect data as organs were too much deteriorated. But seeing Brunner’s gland, we were able to identify the duodenum section and this finding is supported by Gier L. J and Grounds O., 1944 who worked on English

Sparrow which is also a member of the Passeriformes order. Last but not least, we are going to talk about the genital system of the Oriental Magpie Robin. Here in the histological slide, we found an atretic follicle in the ovary. In the ovaries of birds, atresia is a crucial process. The largest pre-ovulatory follicle in birds does not, as in human species, ovulate upon follicle atresia. In the case of wild birds during the breeding season or continuously in the case of commercial layers, follicles in all developmental stages are maintained. In this bird we found, small follicles undergoing atresia. [Apperson, K. D et al, 2017](#) mentioned this similarity in the case of laying hens. [Johnson, A.L. and Woods, D.C, 2007](#) stated about atresia of follicles in their journal which gave us the emphasis on our findings from the histological slide of the ovary of Oriental Magpie Robin.

Chapter 5

Limitations

Throughout the entire investigation, we encountered certain challenges:

- As organs started decomposing, it was really hard for us to collect actual data from the specimen.
- Insufficient data on macroscopic and microscopic descriptions of the Oriental Magpie Robin as very little research is done on this species of bird.

Chapter 6

Conclusion

Little research has been done on the macroscopic and microscopic descriptions of the Oriental Magpie Robin, according to the literature that is currently available. We did our best to describe these qualities in this study. Therefore, this study may serve as a foundation for future work on the pathophysiology of this species. The information presented here can also aid in improving the methods for the conservation of this species by helping to better comprehend postmortem inspection and disease diagnosis.

Chapter 7

References

- Ali, S., & Ripley, S. D. (2001). Handbook of the Birds of India and Pakistan, (9). New Delhi: Oxford University Press.
- AL-Taai, S. A. (2021). Microscopic and morphometric study in trachea and lungs of adult Iraqi pigeon (*Columba livia*). *Sys Rev Pharm*, 12(2), 342-6.
- Apperson, K. D., Bird, K. E., Cherian, G., & Löhr, C. V. (2017). Histology of the ovary of the laying hen (*Gallus domesticus*). *Veterinary Sciences*, 4(4), 66.
- Bancroft, J.D. and Layton, C. (2013) The Hematoxylin and Eosin. In: Suvarna, S.K., Layton, C. and Bancroft, J.D., Eds., Theory & Practice of Histological Techniques, 7th Edition, Churchill Livingstone of El Sevier, Philadelphia, Ch. 10 and 11, 172-214.
- Britannica, T. Editors of Encyclopaedia (2021, April 9). *syrinx*. *Encyclopedia Britannica*. <https://www.britannica.com/science/syrinx-bird-anatomy>.
- Bacha, J. William; and Bacha, M. Linda. (2000). Color atlas of veterinary histology. Lippincott Williams and Willcons Company. 2nd edition, USA.
- Baumel, J.J.; King, A.S.; Breazile, J.E.; Evans, H.E.; and Vandan Berge, J.C. (1993). Respiratory system. In: Handbook of Avian Anatomy Nomina Anatomica.
- Collar, N., Christie, D. A., and Kirwan, G. M. 2020. Oriental Magpie-Robin (*Copsychus saularis*), version 1.0. In: J. del Hoyo, A. Elliott, J. Sargatal, D. A. Christie, and E. de Juana (eds), *Birds of the World*, Cornell Lab of Ornithology, Ithaca, NY, USA.

- Dyce, K. M., Sack, W. O., & Wensing, C. J. G. (2009). *Textbook of veterinary anatomy-E-Book*. Elsevier Health Sciences.
- Folker, E. S., & Baylies, M. K. (2013). Nuclear positioning in muscle development and disease. *Frontiers in physiology*, 4, 363.
- Gartner, L. P. (2007). *Tratado de histologia em cores*. Elsevier Brasil.
- Gray, George Robert (1840). A List of the Genera of Birds: with an Indication of the Typical Species of Each Genus. London: R. and J.E. Taylor. p. 21
- Gier, L. J., & Grounds, O. (1944). Histological study of the digestive system of the English Sparrow. *The Auk*, 241-243.
- Huong SL, Sodhi NS (1997). "Status of the Oriental Magpie Robin *Copsychus saularis* in Singapore". *Malay Nat. J.* **50**: 347–354.
- Jobling, James A. (1991). A Dictionary of Scientific Bird Names. Oxford University Press. p. 216. ISBN 0-19-854634-3.
- Jobling, J.A. (2018). del Hoyo, J.; Elliott, A.; Sargatal, J.; Christie, D.A.; de Juana, E. (eds.). "Key to Scientific Names in Ornithology". Handbook of the Birds of the World Alive. Lynx Edicions. Retrieved 10 May 2018
- Junqueira, L. C., & Carneiro, J. (1985). Histologia básica. In *Histologia básica* (pp. 512-512).
- Johnson, A.L.; Woods, D.C. Ovarian dynamics and follicle development. In *Reproductive Biology and Phylogeny of Birds*; Jamieson, B.G.M., Ed.; Science Publishers: Enfield, NH, USA, 2007; Volume 6A, pp. 243–277.
- Mayr, Ernst; Paynter, Raymond A. Jr, eds. (1964). Check-list of Birds of the World. Vol. 10. Cambridge, Massachusetts: Museum of Comparative Zoology. pp. 64–65

- McLelland, J., (1990): Respiratory system. In: A Colour Atlas of Avian Anatomy. Wolfe Ltd. Eng. PP. 95-119 10.
- Pees, M., & Krautwald-Junghanns, M. E. (2009). Cardiovascular physiology and diseases of pet birds. *Veterinary Clinics of North America: Exotic Animal Practice*, 12(1), 81-97.
- Rae, M. (2006). Necropsy. *Clinical avian medicine*, 2, 661-678.
- Ross, M. H., & Pawlina, W. (2006). *Histology*. Lippincott Williams & Wilkins.
- Robson, C., 2015. *Birds of South-East Asia. Second Edition*. Christopher Helm Publishers Ltd, London. 544pp.
- Sereno, P.C., Martinez, R.N., Wilson, J.A., Varricchio, D.J., Alcober, O.A., Larsson, H.C.E. (2008): Evidence for avian intrathoracic air sacs in a new predatory dinosaur from Argentina. *PLOS ONE* 3(9): 1-20.
- Van Riper III, C., & Van Riper, S. G. (1980). A necropsy procedure for sampling disease in wild birds. *The Condor*, 82(1), 85-98.

Acknowledgments

All glory goes to the omnipotent God, who made it possible for the author to finish the research on “Macro And Microscopic Anatomy Of Some Organs Of Adult Oriental Magpie Robin (*Copsychus saularis*).”

Assistance, support, and cooperation have all been given. The author wishes to express her sincere gratitude, appreciation, respect, and debt of gratitude to her honorable teacher and Clinical Report supervisor Professor Dr. Subrata Kumar Shil, of the Department of Anatomy and Histology, CVASU who currently holds the position of Associate Professor of that department, for his supportive supervision and academic direction.

The author would also like to express her sincere gratitude to the Vice-chancellor of Chattogram Veterinary and Animal Sciences University, Professor Dr. A.S.M. Lutful Ahsan, heartfelt respect to the Dean of Faculty of Veterinary Medicine, CVASU Professor Dr. Lutfur Rahman, and also to the Director of external affairs, Professor Dr. A. K. M. Saifuddin, Department of Physiology, Biochemistry and Pharmacology, CVASU.

Last but not least, the author would like to express her eternal gratitude and unending debt to her parents for their warmest and most loving blessings, encouragement, and numerous sacrifices made in support of her higher education and the successful completion of this study work. Additionally, she thanks her friends, elders, and well-wishers for their ongoing support.

The Author

October, 2023

Biography

I am Labannya Dutta Tithi, daughter of Debidas Dutta and Lucky Dutta. I passed my Secondary School Certificate examination from St. Scholastica Girls' High School, Chattogram in the year 2014 obtaining a G.P.A-5.00. In 2016, I passed my Higher Secondary Certificate examination from Govt. Hazi Mohammad Mohsin College, Chattogram obtaining G.P.A-5.00. Now I am currently working as an intern veterinarian under the Faculty of Veterinary Medicine at Chattogram Veterinary and Animal Sciences University, Bangladesh.

I am very much interested in the veterinary medicine research sector. I want to learn more and more about this profession and serve the nation with my knowledge through my inventions to face the challenges in this field.