

# **Polycystic Liver Disease in a Male Cat: A Case Study**



**Submitted By**

**Shimu Moni**

Roll No: 18/29

Reg. No: 02089

Session: 2017-2018

Intern ID: 27

A Clinical report submitted for the partial satisfaction of the requirements for the  
Degree of Doctor of Veterinary Medicine

**Faculty of Veterinary Medicine**

**Chattogram Veterinary and Animal Sciences University**

Khulshi, Chattogram-4225, Bangladesh

**November 2023**

# **Polycystic Liver Disease in a Male Cat: A Case Study**



---

**Supervisor**

**Dr. Amir Hossan Shaikat**

Professor

Department of Physiology, Biochemistry and Pharmacology

**Faculty of Veterinary Medicine**

**Chattogram Veterinary and Animal Sciences University**

**Khulshi, Chattogram-4225, Bangladesh**

**November, 2023**

## **Acknowledgment**

All honors are due to Almighty "Allah," who is infinitely powerful, infinitely knowledgeable, and universal and who has made it possible for the author to successfully write this work. The author is indebted to her honorable teacher and internship supervisor, Dr. Amir Hossan Shaikat, Professor, Department of Physiology, Biochemistry and Pharmacology, Chattogram Veterinary and Animal Sciences University, and is utterly indebted to her for all of his academic guidance, sympathetic supervision, helpful advice, ongoing inspiration, radical investigation, and constructive criticism throughout the course of the study. Thanks to Professor Dr. A. K. M. Saifuddin, Director (External Affairs) for his dedication to a successful internship program. And thanks to Professor Dr. Mohammad Lutfur Rahman, Dean, Faculty of Veterinary Medicine, Chattogram Veterinary and Animal Sciences University for his valuable suggestion and inspiration. The author also thanks to her parents and friends for their support throughout this internship and for their inspiration.

## Table of Contents

Abstract.....	v
CHAPTER 1: INTRODUCTION.....	1
CHAPTER 2: CASE PRESENTATION .....	3
2.1 Case presentation .....	3
2.2 Diagnosis Protocol.....	3
2.5 Treatment.....	4
CHAPTER 3: RESULTS .....	5
CHAPTER 4: DISCUSSION .....	7
LIMITATION .....	10
CONCLUSION .....	11
REFERENCES.....	12
BIOGRAPHY .....	15

## List of Tables

<b>Table 1:</b> CBC test findings of Cat.....	5-6
<b>Table 2:</b> Serum biochemistry findings of cat.....	6

## **Abstract**

There have been reports of polycystic liver disease (PLD) in humans, dogs, cats, hamsters, rats, deer, and even farm animals like goats and pigs. In cats, PLD typically manifests in those over one year old and resembles congenital polycystic diseases seen in humans. The case at hand involves a male Persian crossbreed cat, aged 10, presenting with bilateral abdominal distention upon physical examination. The presence of ascites and fluctuating structures within the cranial abdominal region was observed. An ultrasound examination revealed the presence of liver cysts, which appeared as multiple anechoic cystic structures. Hyperbilirubinemia and hypoalbuminemia were identified in the serum biochemistry results. Consequently, this cat with complaints of anorexia and abdominal distension was diagnosed with PLD, a condition typically asymptomatic and found incidentally, based on clinical, biochemical, and imaging findings. Transabdominal ultrasound examinations were found to be valuable in diagnosing PLD cases. It is considered that the presented case will provide useful information in veterinary medicine practice regarding clinical symptoms and diagnosis of PLD.

**Keywords :** Polycystic Liver Disease, Cat, USG.

## CHAPTER 1: INTRODUCTION

The most prevalent liver condition in cats is parenchymal and interstitial hepatitis, accounting for 45.1% of all diagnoses. Within feline hepatitis cases, neutrophilic cholangiohepatitis made up 23.9%, lymphocytic cholangiohepatitis 14.1%, and chronic hepatitis 5.6%. Adult polycystic liver disease constituted 5.6% of cases. Among proliferative liver diseases in felines, lymphoma and primary epithelial tumors, including hepatocellular carcinoma, cholangiocellular adenoma, and cholangiocellular carcinoma, were observed, each at 4.2%. Hepatic degeneration was seen in 14.1% of cases, and 12.7% were diagnosed with microvascular dysplasia (Hirose et al., 2014). Polycystic liver disease is a rare condition characterized by the development of multiple cysts in the liver which are small, benign growths that are typically filled with fluid. It is often associated with polycystic kidney disease (PKD), which is more commonly seen in some cat breeds, such as Persians and Himalayans. Polycystic liver disease (PLD) has been reported in humans, dogs, cats, hamsters, white-tailed deer, llamas, and some farm animals. It is a challenging research topic in terms of its clinical course, genetic and pathological features, classification, origin, and development (Handler, 1965). The polycystic liver disease in cats (PLD) is considered a genetic disorder. In many felines diagnosed with PLD, the condition is secondary to the autosomal dominant polycystic kidney disease (AD-PKD). Most of the time, the causes of the condition are unknown.

Liver cysts can be congenital or acquired. The congenital disease is usually polycystic (Center, 2009; Johnson, 2000), with Persian and Persian crossbred cats over-represented; the polycystic form may be associated with cystic lesions in other organs, main kidneys (Center, 2009; Bosje et al., 1998) with a clear cyst content (Center, 1996; Crawford, 2005). In cases of congenital liver cysts identified in dogs, 3 single/solitary cysts, 3 PLDs, and one congenital bile duct dilatation have been identified and it has been reported that the majority of cysts do not have an intrahepatic biliary duct system involvement and there is no bile acid and bilirubin in the cyst content (Van den Ingh, 1985; Rothuizen, 1985). Acquired cysts are usually parasitic cysts and the microscopic analysis of cystic fluids may detect the parasite itself or scolex. Another reason is

biliary cystadenoma (Somvanshi et al, 1987). The acquired disease is commonly solitary, with blood or bilirubin cyst content and may be produced by inflammation, trauma or neoplasia (Center, 2009). According to Bowman (2003), in the infection caused *Platynosomum concinnum*, the prepatent period lasts for 2 or 3 months, and the cat's stool still carries eggs for 1.5 year after the initial exposure. The organs affected by the infection are the liver, the bile ducts and the gallbladder. Occasionally other organs can be infected, such as the small intestine, the pancreatic ducts and the lungs. In both acquired or congenital disease, the cystic structures are derived from ductular epithelium (Center, 2009). The presence of liver cysts in felines may be related to the parasitism caused by trematode helminths (Foley, 1994). A large number of liver cysts were identified in a 10-year-old cat's liver, with less than 1 mm wall thickness, 1-4.5 cm in diameter, filled with a slightly mucoid clear fluid, exceeding the capsular level of the liver (Stebbins, 1989). PLD diagnosis was made in wild goats with numerous non-parasitic cysts with hepatomegaly, subcapsular, uni/multilocular, thin-walled, 0.5-0.8 cm in diameter, filled with 1-15 ml serous and amber-colored fluid (Glawischnig and Bago, 2010). Also, autosomal dominant polycystic kidney and liver disease in humans has been described in rats (Lager et al., 2001).

Cats with polycystic liver disease may not show any clinical signs, especially in the early stages. The condition can remain asymptomatic for a long time. Some cats may exhibit mild abdominal discomfort, which can manifest as restlessness, pacing, or sensitivity to touch in the abdominal area. In more severe cases, when cysts compress the bile ducts or cause liver damage, cats may develop jaundice. This leads to yellowing of the skin, gums, and whites of the eyes. Cats with advanced polycystic liver disease may experience intermittent or persistent vomiting. Progressive liver damage and discomfort can lead to weight loss in affected cats.

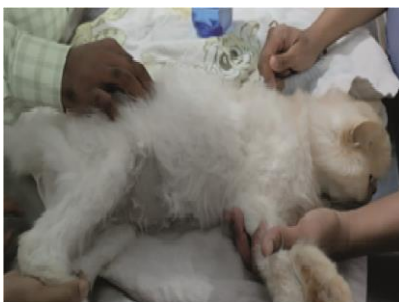
## CHAPTER 2: CASE PRESENTATION

### 2.1 Case presentation

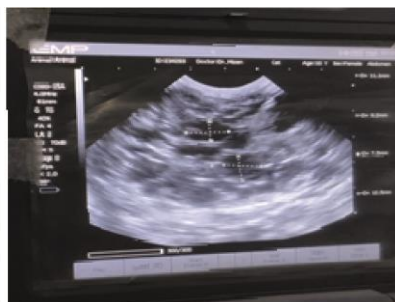A Persian crossbreed 10 years old male cat of 4.0kg that was presented to Teaching and Training Pet Hospital and Research Center, Purbachal, Dhaka. It had history of abdominal distention and inappetence of 7days. During physical examination, a swollen mass on the belly with bilateral abdominal distension was found (Figures 1). The cat had normal body temperature, respiration rate, heart rate, urination and defecation. It was vaccinated and dewormed regularly. There were no symptoms of enteritis. Abdominal palpation revealed the presence of abdominal fluid, thickening of the abdominal wall, and intraabdominal fluctuant structures in the cranial abdominal area. Although the mucous membranes of eyes were pale, icterus was not apparent.

### 2.2 Diagnosis Protocol

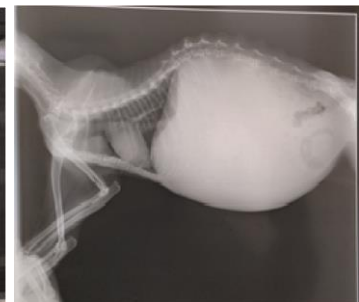In order to make a confirmatory diagnosis, radiographic and ultrasonographic examinations as well as laboratory tests (including blood tests and serum biochemistry) were requested. 5 ml blood was collected from cephalic vein. Complete blood count (CBC) testing was performed on half of the sample, which was mixed with 10% ethylenediaminetetraacetic acid (EDTA), and serum biochemistry testing was performed on the remaining sample, which was kept in a blood collection tube without anticoagulant.



**Figure 1: Abdominal distention**



**Figure 2: Cysts in liver**



**Figure 3: Radio Opaque zone & ascities**



### **2.3 Treatment**

An amino acid, vitamin, mineral combined preparation (Inj. Aminovit plus vet<sup>®</sup>, Popular Company) 0.5 ml, Subcutaneously, once daily was administered for a week. A zinc plus Vitamin B complex preparation (Syp. Xinc B<sup>®</sup>, Eskayef Bangladesh Limited) 2 ml was given orally for 10 days and Omega 3 Fatty Acid preparation (Cap. OMG 3<sup>®</sup>, Drug International) 4 drops was given orally for 10 days.

### CHAPTER 3: RESULTS

Radiographic and ultrasonographic examinations were conducted to the differential diagnosis of abdominal distention (ileus, gas in the intestines, change of pathological status, obesity, etc.). On abdominal radiographic examination, a bright opaque (radio-opaque) zone (both lateral views) and ascites were verified (Figure 3). In ultrasonographic examination thin-walled, numerous, anechogenic cystic structures with diameters ranging from 0.25 to 3 cm were found in the hepatic parenchyma (Figure 2) and the abdominal effusion found. (Figure 2)

The rates of erythron (red blood cell (RBC) count 3.57 m/cumm, hematocrit 20.70% and hemoglobin 5.5 g/dl) were lower the normal range. Platelet count (4,14,000/mm<sup>3</sup>) and white blood cell (WBC) count (19,100/mm<sup>3</sup>) were within the normal range. The white blood cell differential count showed a discreet lymphopenia. The serum biochemistry testing showed a normal rate of creatinine (1.45 mg/dL), whereas the enzymes alkaline phosphatase (ALP: 54 U/L) and alanine transaminase (ALT: 212 U/L), Bilirubin (1mg/dl) rates were above the normal range for the species.

**Table 1:** CBC test findings of Cat

Test Name	Result	Reference Value
Hemoglobin (Hb%)	5.5 g/dl	9.0-15.0 g/dl
TEC	3.57 m/cumm	4.60 - 10.00 m/cumm
HCT / PCV	20.70%	26.0 - 49.0 %
TLC	19,100 / cumm.	5,000-19,000 / cumm.
MCV	58.1 fL	39.0-53.0 fL
MCH	15.4 pg	13.0 - 20.0 pg
MCHC	26.5 g/dl	29.0 - 37.0 g/dl
RDW CV	30.10%	15.0-22.0 %
MPV	15.4 fL	8.1-13.9 fL
PCT	0.92	0.09 - 1.00
Neutrophils	88%	38 - 75 %
Lymphocytes	6%	12 - 45 %

Monocytes	4%	1 - 7%
Eosinophil's	2%	01 - 11 %
Basophils	0%	00 - 01 %
Absolute Eosinophil's Count	382/cumm	100 – 1200 / cumm
Platelet Count	4,14,000 /cumm	1,00,000 - 5,18,000 / cumm

**Table 2 : Serum biochemistry findings of cat**

<b>Parameters</b>	<b>Test Results</b>	<b>Reference Value</b>
Glucose	47.4	50-170 mg/dl
Total Protein	5.8	5.2-8.8 g/dl
Albumin	2.3	2.5-3.9 g/dl
Bilirubin	1	0.1-0.4 mg/dl
Alanine Aminotransferase (ALT/SGPT)	212	10-100 u/l
Aspartate Aminotransferase (AST/SGOT)	101	10-100 u/l
Alkaline Phosphatase (ALP)	54	10-50 u/l
Cholesterol	155.8	75-220 mg/dl
Blood Urea Nitrogen (BUN)	21	14-36 mg/dl
Serum Creatinine	1.4	0.6-1.6 mg/dl

## CHAPTER 4: DISCUSSION

Congenital diseases like polycystic diseases are sometimes detected incidentally. Cysts can be asymptomatic and usually appear in the liver. Congenital polycystic diseases in humans and polycystic disease in cats share similarities (Goodman, 1976). PLD is frequently noticed in cats older than a year. Cysts are characterized as thin-walled sacs filled with amber-colored fluid and found in the liver, epididymis, ovary, adrenal glands, renal pelvis, endometrium, pancreas, and esophagus. The liver is the organ where cysts appear most frequently among them. In the case at present, liver ultrasonography revealed thin-walled multiple cystic structures (uni-/multi-loci) with sizes ranging from 0.25 to 3 cm, which is consistent with earlier descriptions of PLD (Van Aerts et al., 2018; Lager et al., 2001; Stebbins et al., 1989). Along with ultrasonographic examination findings, the patient was diagnosed with PLD based on the radiological examination (Figure 3b) and analysis of blood and serum biochemistry.

The SGOT/AST and SGPT/ALT, ALP enzyme activity in both humans and animals are assessed as key indicators of oxidative stress and liver issues. The enzymes SGOT, SGPT, arginase, lactate dehydrogenase, and gamma-glutamyl transaminase are free to leave the cells and enter the blood vessels faster than anticipated when the liver is injured and this causes an increase in their blood levels (Calbreath, 1992). Although there are other enzymes, SGOT and SGPT will expand more quickly and dramatically than the other enzymes (Fathoni, 2008). Increases in SGPT or SGOT are indicators of hepatic abnormalities in liver cells, which are triggered due to alterations in permeability or damage to the liver cell walls (Rosida, 2016). Elevated SGOT is utilized as a biochemical marker to identify liver cell necrosis since it may remain in the bloodstream for two to five days (Engelking, 2011). While SGOT and SGPT tests from blood results are the gold standard for identifying liver illness, further diagnostics such as x-rays, ultrasound, and bilirubin level results are also required. According to Kanimozhi et al., (2016), low AST and ALT enzyme activity are directly linked to hepatic vessel dilatation and hepatocyte disruption or necrosis. Elevated ALP enzyme activity is regarded as a sensitive indication of biliary disorders, virally caused hepatitis, and chronic liver diseases (Brunnert and Altman, 1991). An elevated serum

bilirubin concentration denotes a biliary obstruction or stasis caused by liver inflammation or injury (Kanimozhi et al., 2016; Zimmerman et al., 2010; Brunnert and Altman, 1991).

It has also been shown that the severity of PLD instances in humans is positively connected with liver enzyme levels and negatively correlated with serum albumin levels (Everson et al., 1988 ). The extent of liver parenchymal damage caused by cysts ranges from 5 to 60% (Somvanshi et al., 1987). The increase in serum ALP, hyperbilirubinemia, and hypoalbuminemia, along with the normal leukogram, were all considered indicators of non-infectious liver injury and/or failure in the present case. Bile duct injury, stasis, and/or obstruction were linked to slight increases in ALP enzyme activity and bilirubin concentration (Kanimozhi et al., 2016; Zimmerman et al., 2010). The development of bile duct damage or subclinical pancreatitis was suggested by the hyperbilirubinemia and elevated ALP enzyme activity found in this patient (Sidebotham, 2007; Borini and Guimaraes, 1999).

BUN and Creatinine levels findings (Baker and Lumsden, 2000) were related to a decrease in the oncotic pressure of blood due to hypoalbuminemia and disruption of liver protein synthesis. In the presented PLD case, the severity of liver damage was evaluated as mild according to the alteration of liver enzyme activity and the degree of hypoalbuminemia (Somvanshi et al., 1987; Everson et al., 1988).

In both human and veterinary medicine, abdominal ultrasonography is commonly used for disease screening, hepatocellular disease diagnosis, and prognosis assessment. According to Plengsuriyakarn et al. (2012), it is a valid technique for assessing and following the development of tumoral and cystic cases like cholangiosarcoma, PLD, and liver parenchymal alterations. In the present case the liver parenchyma's heterogeneous structure, anechogenic, polycystic structures of various sizes were identified. The identification of PLD and the diagnosis or differential diagnosis of individuals with abdominal tension were both found to benefit from ultrasonographic exams.

In this case, we used amino acid, vitamin, mineral preparation, zinc preparation and omega 3 fatty acid preparation. Amino acids are organic substances containing amine

and carboxylic acid functional groups (Wu, 2009), which are the basic unit for protein synthesis in cellular metabolism. Liver is an important organ for protein synthesis, degradation and detoxification as well as amino acid metabolism (Dejong et al., 2007). Zinc is essential for the production of certain zinc enzymes, which are vital for maintaining liver function. Zinc concentrations are often lower in patients with chronic liver disorders (CLDs), which may go further reduced as liver fibrosis progresses. Whether sustained zinc supplementation enhances liver function and lowers the chance of developing hepatocellular carcinoma (HCC) remains unknown (Hosui et al., 2018). The metabolism of liver fat may be directly impacted by omega-3 fatty acids (Leslie et al., 2015). According to studies, omega-3 fatty acids may increase the liver's ability to break down fat, which would prevent the accumulation of liver fat (Scorletti and Byrne, 2013). Additionally, omega-3 fatty acids may have anti-inflammatory properties, as liver inflammation plays a major role in the onset and course of liver disorders (Lepretti et al., 2018). Although the precise processes underlying the possible benefits of Omega-3 fatty acids in the prevention of liver disorders are not entirely understood, they may be enhanced by their anti-inflammatory and lipid-metabolizing properties. Treating liver diseases in cats involves to the root cause, typically focusing on supportive care. It is advisable to assess and sustain the cat's hydration while offering nutritional assistance, particularly in cases where the cat has lost its appetite. In this instance, the cat's condition was stabilized with a brief administration of electrolytes and nutritional support as part of the supportive care, and ensuring that the cat receives a complete and balanced feline diet can lead to adequate stabilization.

## **LIMITATION**

The limitations of this case report were a lack of experimental laparotomy and cyst fluid aspiration for cytological test.

## **CONCLUSION**

This case report highlights the rare but significant condition of polycystic liver disease (PLD) in cats. PLD which is usually asymptomatic was diagnosed in a cat with complaints of anorexia and abdominal distension, based on clinical, ultrasonographic and biochemical findings. This case is believed to offer valuable insights into the clinical symptoms and diagnosis of PLD in veterinary practice. Timely diagnosis and appropriate management are crucial in improving the quality of life for affected cats, underscoring the importance of continued research and awareness of this condition within the veterinary community.



## REFERENCES

- Baker, R., Lumsden, J. H. (2000). Cytopathology techniques and interpretation. In Baker R, Lumsden J. eds., *Color Atlas of the Dog and Cat*. St. Louis: Mosby, 941-943.
- Borini, P. and Guimaraes, R. C. (1999). Indicators of inflammation and cellular damage in chronic asymptomatic or oligosymptomatic alcoholics: correlation with alteration of bilirubin and hepatic and pancreatic enzymes. *Revista do Hospital das Clinicas*, 54(2), 53–60.
- Bosje, J. T., van den Ingh, T. S., and van der Linde-Sipman, J. S. (1998). Polycystic kidney and liver disease in cats. *The veterinary quarterly*, 20(4), 136–139.
- Bowman, D. D., Lynn, R. C., Eberhard, M. L., Alcarat, A., Georgi, J.R. (2003). *Parasitologia Veterinaria de Georgia*. New York, Manole.
- Brunnert, S. R. and Altman, N. H. (1991). Laboratory assessment of chronic hepatitis in Syrian hamsters. *Laboratory animal science*, 41(6), 559–562.
- Calbreath, D. F. (1992). *Clinical Chemistry*. W.B. Saunder Company, USA.
- Center S. A. (2009). Diseases of the gallbladder and biliary tree. *The Veterinary clinics of North America. Small animal practice*, 39(3), 543–598.
- Crawford, J. M., Kumar, V., Abbas, A. K., Fausto, N.(2005). *Liver and biliary tract: Robbins and Cotran Pathological Basis of Disease (7th Edition)*. Elsevier Saunders, Philadelphia, 877-937.
- Dejong, C. H., van de Poll, M. C., Soeters, P. B., Jalan, R. and Olde Damink, S. W. (2007). Aromatic amino acid metabolism during liver failure. *The Journal of nutrition*, 137(6), 1579–1598.
- Engelking, L. R. (2011). In L. R. Engelking, *Textbook of Veterinary Physiological Chemistry*.
- Everson, G. T., Scherzinger, A., Berger-Leff, N., Reichen, J., Lezotte, D., Manco-Johnson, M., and Gabow, P. (1988). Polycystic liver disease: quantitation of parenchymal and cyst volumes from computed tomography images and clinical correlates of hepatic cysts. *Hepatology (Baltimore, Md.)*, 8(6), 1627–1634.

- Fathoni, F. (2008). *Studi Kadar SGPT, SGOT Dan Total Protein Pada Serum Darah Anjing Kampung (Canis familiaris) Usia 3 dan 6 Bulan*. Skripsi. Institute Pertanian Bogor.
- Foley, R. H. (1994) *Platinosomum concinnum* infection in cats. *Compendium on Continuing Education for the Practising Veterinarian, Princeton*, 16(10), 1271-1277.
- Glawischnig, W. and Bago, Z. (2010). Polycystic liver disease in senile chamois (*Rupicaprae rupicaprae*). *Journal of wildlife diseases*, 46(2), 669–672.
- Goodman, F. R. (1976). Negative inotropic effects of gentamicin in guinea pig left atria. *Federation proceedings*, 35, 613.
- Handler, A. H. (1965). Spontaneous lesions of the hamster. *The Pathology of Laboratory Animals*, 97, 210-240
- Hirose, N., Uchida, K., Kanemoto, H., Ohno, K., Chambers, J. K. and Nakayama, H. (2014). A retrospective histopathological survey on canine and feline liver diseases at the University of Tokyo between 2006 and 2012. *The Journal of veterinary medical science*, 76(7), 1015–1020.
- Hosui, A., Kimura, E., Abe, S., Tanimoto, T., Onishi, K., Kusumoto, Y., Sueyoshi, Y., Matsumoto, K., Hirao, M., Yamada, T., & Hiramatsu, N. (2018). Long-Term Zinc Supplementation Improves Liver Function and Decreases the Risk of Developing Hepatocellular Carcinoma. *Nutrients*, 10(12), 1955.
- Johnson, S. E., Ettinger, S. J., Feldman, E. C. (2000). *Textbook of Veterinary Internal Medicine* (5th edition), WB Saunders: Philadelphia, 1298–1325.
- Kanimozhi, V., Palanivel, K., Akbarsha, M. A. and Kadalmani, B. (2016). Tributyltin-mediated hepatic, renal and testicular tissue damage in male Syrian hamster (*Mesocricetus auratus*): a study on impact of oxidative stress. *SpringerPlus*, 5(1), 1523.
- Lager, D. J., Qian, Q., Bengal, R. J., Ishibashi, M. and Torres, V. E. (2001). The pck rat: a new model that resembles human autosomal dominant polycystic kidney and liver disease. *Kidney international*, 59(1), 126–136.
- Lepretti, M., Martucciello, S., Burgos Aceves, M. A., Putti, R. and Lionetti, L. (2018). Omega-3 Fatty Acids and Insulin Resistance: Focus on the Regulation of Mitochondria and Endoplasmic Reticulum Stress. *Nutrients*, 10(3), 350.
- Leslie, M. A., Cohen, D. J., Liddle, D. M., Robinson, L. E. and Ma, D. W. (2015). A review of the effect of omega-3 polyunsaturated fatty acids on blood

triacylglycerol levels in normolipidemic and borderline hyperlipidemic individuals. *Lipids in health and disease*, 14, 53.

- Plengsuriyakarn, T., Eursitthichai, V., Labunruang, N., Na-Bangchang, K., Tesana, S., Aumarm, W., Pongpradit, A. and Viyanant, V. (2012). Ultrasonography as a tool for monitoring the development and progression of cholangiocarcinoma in *Opisthorchis viverrini*/ dimethylnitrosamine-induced hamsters. *Asian Pacific journal of cancer prevention : APJCP*, 13(1), 87–90.
- Rosida, A. (2016). Pemeriksaan Laboratorium Penyakit Hati. *Berkala Kedokteran*, 12(1), 123-131.
- Scorletti, E. and Byrne, C. D. (2013). Omega-3 fatty acids, hepatic lipid metabolism, and nonalcoholic fatty liver disease. *Annual review of nutrition*, 33, 231–248.
- Sidebotham, D. (2007). Nutrition and Disorders of Gastrointestinal and Hepatic Function. *Cardiothoracic Critical Care*, 34, 495-509.
- Somvanshi, R., Iyer, P. K., Biswas, J. C. and Koul, G. L. (1987). Polycystic liver disease in golden hamsters. *Journal of comparative pathology*, 97(5), 615–618.
- Stebbins K. E. (1989). Polycystic disease of the kidney and liver in an adult Persian cat. *Journal of comparative pathology*, 100(3), 327–330.
- van Aerts, R. M. M., van de Laarschot, L. F. M., Banales, J. M. and Drenth, J. P. H. (2018). Clinical management of polycystic liver disease. *Journal of hepatology*, 68(4), 827–837.
- Van den Ingh, T. S. and Rothuizen, J. (1985). Congenital cystic disease of the liver in seven dogs. *Journal of comparative pathology*, 95(3), 405–414.
- Wu, G. (2009). Amino acids: metabolism, functions, and nutrition. *Amino acids*. 37(1), 1–17.
- Zimmerman, K. L., Moore, D., Smith, S. A. (2010). Hematology of laboratory rabbits (*Oryctolagus cuniculus*). *Hematological Assessment*, 862–869.

## **BIOGRAPHY**

My name is Shimu Moni, and I'm daughter of Laila Sarkar and Md. Esha Sarkar. I was born in Chattogram Division. I completed my Secondary School Certificate (SSC) from Chattogram Metropolitan School & College in 2014 and Higher Secondary Certificate (HSC) from Chattogram Govt. Women College in 2016. I enrolled at Chattogram Veterinary and Animal Sciences University (CVASU), in Chattogram, Bangladesh, for the 2016–2017 academic year in order to pursue a Doctor of Veterinary Medicine (DVM) degree. In the near future, I would like to be a skilled Veterinarian.