

**Diagnosis and Therapeutic Management of Newcastle Disease
Outbreak in a Broiler Farm: A Comprehensive Study of Gross
and Microscopic Lesions**



**A clinical report submitted in partial satisfaction of the requirement for the
Degree of Doctor of Veterinary Medicine (DVM)**

Submitted by

Sujoy Das

Roll No: 18/16

Reg No: 02074

Intern ID: 15

Session: 2017-18

Faculty of Veterinary Medicine

Chattogram Veterinary and Animal Sciences University

Khulshi, Chattogram – 4225, Bangladesh

November, 2023

**Diagnosis and Therapeutic Management of Newcastle Disease
Outbreak in a Broiler Farm: A Comprehensive Study of Gross
and Microscopic Lesions**



Submitted by

Sujoy Das

Roll No: 18/16

Reg No: 02074

Intern ID: 15

Session: 2017-18

Approved as to style and content by

Professor Dr. Kh. Nurul Islam

Department of Anatomy and Histology

Faculty of Veterinary Medicine

Chattogram Veterinary and Animal Sciences University

Khulshi, Chattogram- 4225, Bangladesh.

November,2023

Table of contents

Contents	Page No
List of figures	1
List of abbreviations	1
Abstract	2
CHAPTER-I: Introduction	3
CHAPTER-II: Case presentation	5
CHAPTER-III: Results	10
CHAPTER-IV: Discussion	11
CHAPTER-V: Limitation	12
CHAPTER-VI: Conclusion	13
References	14
Acknowledgement	16
Biography	17

List of figures

Figure	Legend	Page No
Figure 1	Dark congested hemorrhagic lungs	06
Figure 2	Hemorrhagic patches on the mucosa of proventriculus	06
Figure 3	Hemorrhagic ulcers on intestine	06
Figure 4	Hemorrhagic spots on cecal tonsils	06
Figure 5	Lesions in histopathological slide of lung (4X)	07
Figure 6	Lesions in histopathological slides of lung (10X)	07
Figure 7	Intestinal lesions in histopathological slides (4X)	08
Figure 8	Intestinal lesions in histopathological slides (10X)	08
Figure 9	Histopathological slides showing lesions of cecal tonsils (4X in left and 10X in right)	08
Figure 10	Healthy flock after treatment	10

List of abbreviations

Abbreviation	Elaboration
ND	Newcastle disease
NDV	Newcastle disease virus
vv	very virulent
APMV-1	Avian Paramyxovirus Serotype-1
%	percentage
gm	gram
L	Liter
ml	milliliter
@	at a rate of

Abstract

An outbreak of Newcastle disease was found on 17th August, 2023 at a broiler farm in Chattogram Metropolitan Area with a history of dyspnea, gasping, coughing, drowsiness, decreased feed intake, and sudden mortality of 45 birds out of 1000 chickens in previous three days. The flock's average body weight was between 900 to 1000gm and they were 20 days old. The clinical signs were dyspnea, drowsiness, reduced feed intake, gasping, coughing, sticky ocular and nasal discharge, violent diarrhea (bright green in color), CNS involvement such as tremor as well as neck and head twisting. At postmortem examination, there found dark congested hemorrhagic lungs, hemorrhagic patches on the entire mucosa of proventriculus, hemorrhagic ulcers on intestines, hemorrhagic spots on cecal tonsils. For comprehensive study, the permanent slides were prepared. In the permanent slide of some samples such as lungs, intestine and cecal tonsils there showed some microscopic lesions that were severe congestion, hemorrhages, collapsed and ruptured alveoli, and a considerable number of inflammatory cells in the alveoli and interalveolar septa in lungs, small hemorrhages in the lamina propria, shrinkage and fusion of the villi, desquamation of the lining epithelium, and infiltration of inflammatory cells were found in intestine, transmural inflammatory cell invasion and slight hemorrhages in the cecal tonsils. The treatment was given such as Sulfonamides as antibiotic, Anti-stress element and immune stimulator, antiviral element, mucolytic agent and Vitamin A, D3, E preparation. Some advice regarding biosecurity measures were also given. The outcome of the treatment was satisfactory. The birds' condition progressively became better, and the deaths of the birds had ceased happening. There was no longer any mortality.

Keywords: Newcastle disease, violent diarrhea, congestion, hemorrhage, mortality, therapeutic management.

CHAPTER-I

Introduction

Bangladesh's poultry industry plays an essential role to the country's rural socioeconomic system since it promotes economic growth while also providing a huge number of job opportunities. Poultry farming has historically been one of the most important sources of an income for rural women in Bangladesh, particularly for landless and small-scale farmers (Paul et al., 1990). Commercial poultry farming has become one of Bangladesh's most promising industries in recent years. Many farmers discard their old, conventional practices in favor of a new, commercial approach to raising chicken (Uddin et al., 2010).

Broiler raising is popular among poultry farmers due to its short life span and relatively inexpensive capital investment (Raha, 2007). Broiler farming has also played an important role in delivering high-quality proteins and micronutrients, which has a significant influence on the health and nutrition of impoverished people in rural regions (Barroeta, 2007).

Poultry industries are extremely sensitive to different viral infections, which reduce profits. Newcastle disease, avian influenza virus illness, lymphoid leucosis, chicken infectious anemia, and other viral infections are the most frequent in poultry. The most prevalent poultry disease in Bangladesh is Newcastle disease, commonly referred to as Ranikhet disease.

Newcastle disease (ND) is caused by avian paramyxovirus serotype-1 (APMV-1) viruses, which have been recognized as being members of the Rubula virus genus, Paramyxovirinae subfamily, and Paramyxoviridae family (Mayo, 2002). There are three different pathotypes of Newcastle disease viruses (NDVs), such as low virulent (lentogenic), moderately virulent (mesogenic), and virulent (velogenic). According to (Samad, 2005), velogenic NDV strains rather than mesogenic or lentogenic ones are the primary causes of ND in chicken in Bangladesh.

The mortality rate from very virulent (vvNDV) in young and adult chickens ranges from 80-100% (Eisa et al., 1984). Infected birds' feces and other excretions, contact with contaminated feed, water, equipment, and clothes, selling or giving away sick birds, and newly introduced birds are all ways that NDV is spread (Tu et al., 1998).

NDV has an impact on the respiratory, neurological, and digestive systems. Symptoms vary greatly depending on the viral strain, bird species, concurrently diseases, and prior immunity.

Hemorrhagic lesions are predominant in the stomach in viscerotropic velogenic NDV, while neurotropic velogenic NDV exhibits respiratory and neurological signs and has a high death rate (Swayne et al., 1998).

The disease's incubation period ranges from 2 to 15 days. Sneezing, gasping for air, nasal discharge, coughing, greenish, watery diarrhea, depression, muscular tremors, drooping wings, twisting of the head and neck, circling, complete paralysis, and swelling of the tissues around the eyes and in the neck are all symptoms of an infected bird. NDV is so dangerous that many birds die without presenting any symptoms.

Infected birds frequently have mucus in the trachea, petechiae on the serous membranes, hemorrhage on the proventriculus, and necrotic hemorrhagic patches on the mucosal surface of the intestines (button ulceration) (MSD Veterinary Manual)

The current study's goal was to conduct a comprehensive evaluation of gross and microscopic lesions as well as therapeutic management of Newcastle disease.

CHAPTER-II

Case Presentation

2.1. Case History

An outbreak of Newcastle disease was found on 17th August, 2023 at a broiler farm in Chattogram Metropolitan Area. The owners' complaint had been recorded. There were 1000 broiler chickens in the flock, and they were 20 days old. The flock's average body weight was between 900 to 1000gm. In the previous three days, 45 birds from the flock died suddenly. Dyspnea, gasping, coughing, drowsiness, reduced feed intake, sticky ocular and nasal discharge, and violent diarrhea (bright green in color) were the clinical signs that were noticed in the flock. Additionally, some birds reported tremor as well as neck and head twisting. That flock had a history of being regularly vaccinated.

2.2. Clinical Diagnosis

For diagnosis, observed clinical signs and performed postmortem on sick chickens. The gross lesions of affected organs were then examined.

2.2.1. Clinical Signs

The flock showed the following clinical signs:

- Dyspnea, drowsiness and reduced feed intake.
- Gasping and coughing.
- Sticky ocular and nasal discharge.
- Violent diarrhea (bright green in color).
- CNS involvement such as tremor as well as neck and head twisting.

By seeing that clinical signs, the tentative diagnosis was Newcastle disease.

2.2.2. Postmortem examination

Postmortem examination of diseased chickens was conducted to confirm the diagnosis. Then the gross lesions were noticed.

The lungs of infected chickens were congested, hemorrhaged, black, and edematous. Consolidation with fibrin residues was also seen (Figure 1). On the whole mucosa of the proventricular gland, several hemorrhagic patches coalesced to create a brush paint look (Figure 2).

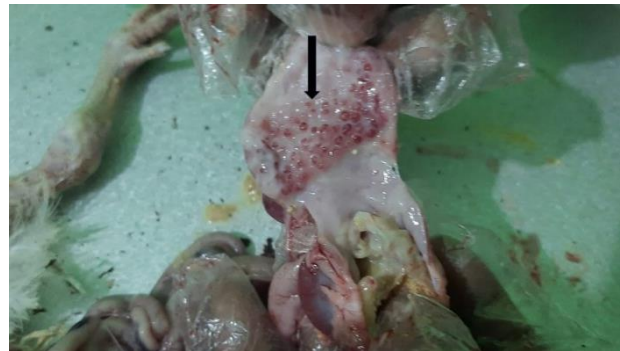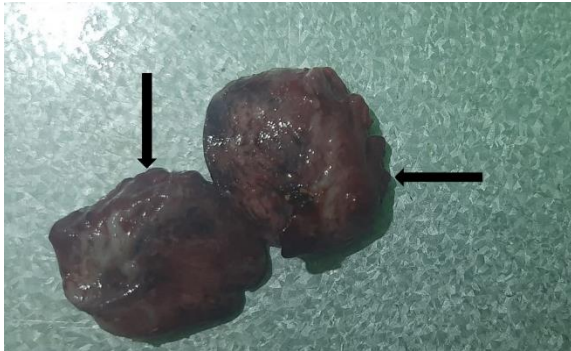


Figure 1: Dark congested hemorrhagic lungs. **Figure 2:** Hemorrhagic patches on the mucosa of proventriculus.

Broilers with NDV infection had extensive hemorrhagic ulcers on their intestine (Figure 3). Hemorrhagic spots were also visible in the cecal tonsils of infected chickens (Figure 4).

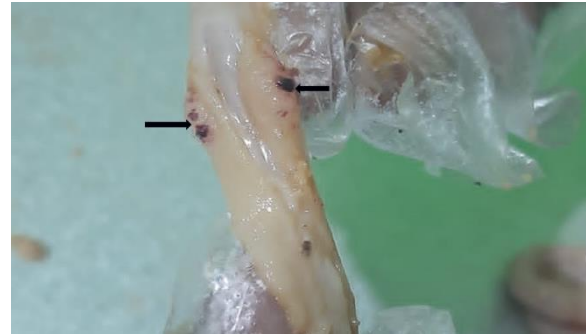
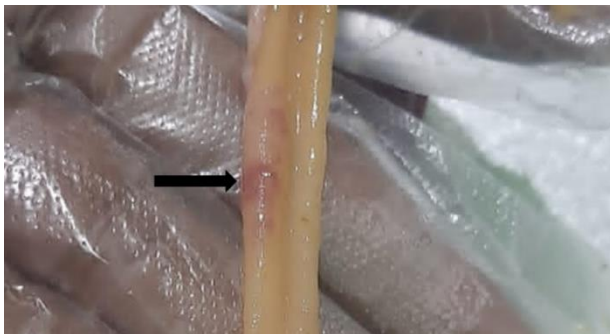

Figure 3: Hemorrhagic ulcers on intestine. **Figure 4:** Hemorrhagic spots on cecal tonsils.

After postmortem examination, by seeing the gross lesions, the Newcastle disease was diagnosed.

2.2.3. Microscopic Lesions

For comprehensive study on microscopic or histopathological lesions of ND, some sample such as lungs, intestine, cecal tonsils were collected. Then the permanent slides of the samples were prepared and observed the lesions.

There were vascular alterations in the lungs that were ultimately associated with alveolar rupture, as well as an infiltration of mononuclear cells that became prominent along the collapsed and ruptured alveoli.

Arrow marks in (Figure 5 & 6) indicated severe congestion, hemorrhages, collapsed and ruptured alveoli, and a considerable number of inflammatory cells in the alveoli and interalveolar septa.

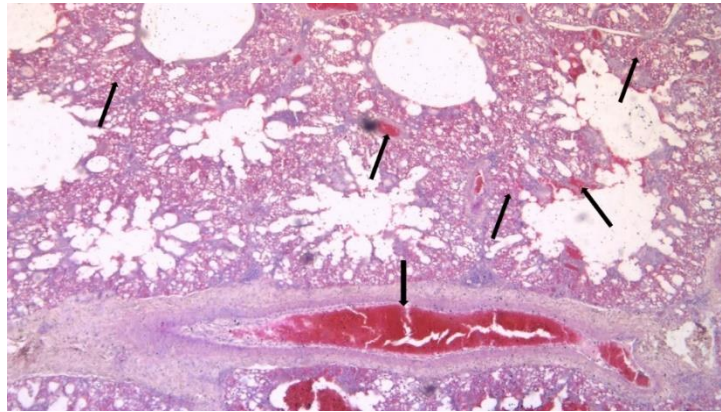


Figure 5: Lesions in histopathological slide of lung (4X)

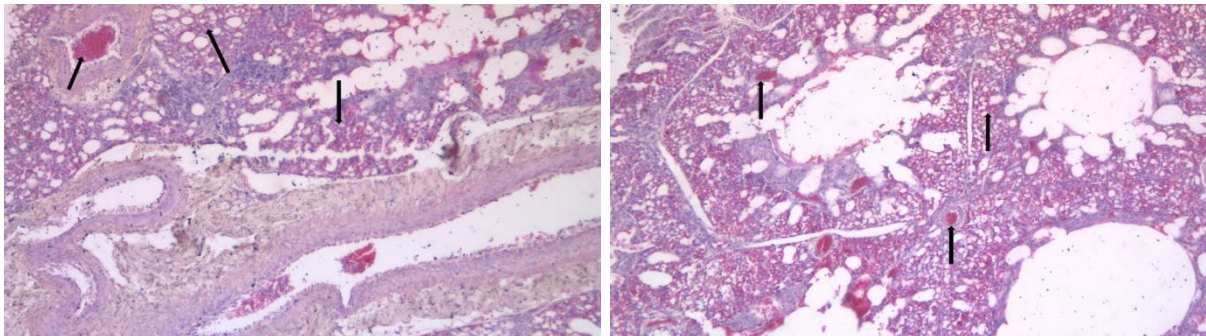


Figure 6: Lesions in histopathological slides of lung (10X)

There were small hemorrhages in the lamina propria of the intestine, shrinkage and fusion of the villi, desquamation of the lining epithelium, and infiltration of cells that were inflammatory.

The plicae's hemorrhages, necrosis, loss of lining epithelium, fusion, and shortening as well as the infiltration of many inflammatory cells illustrated in (Figure 7 & 8).

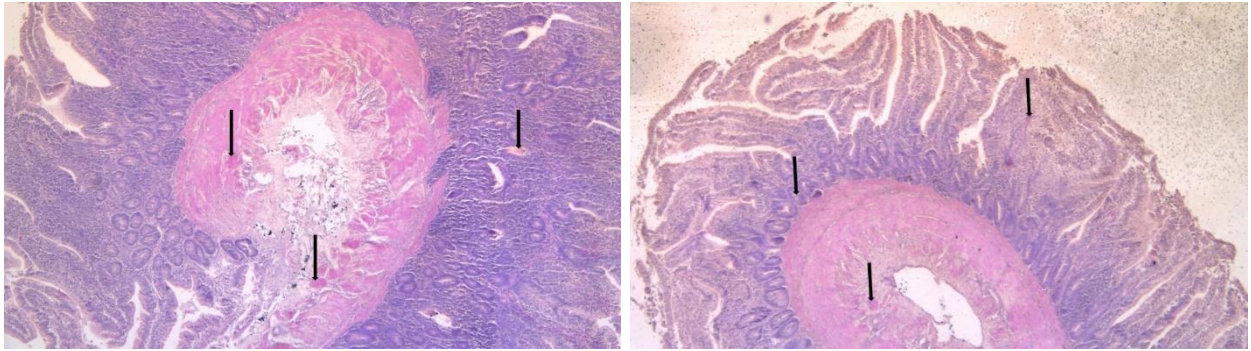


Figure 7: Intestinal lesions in histopathological slides (4X)

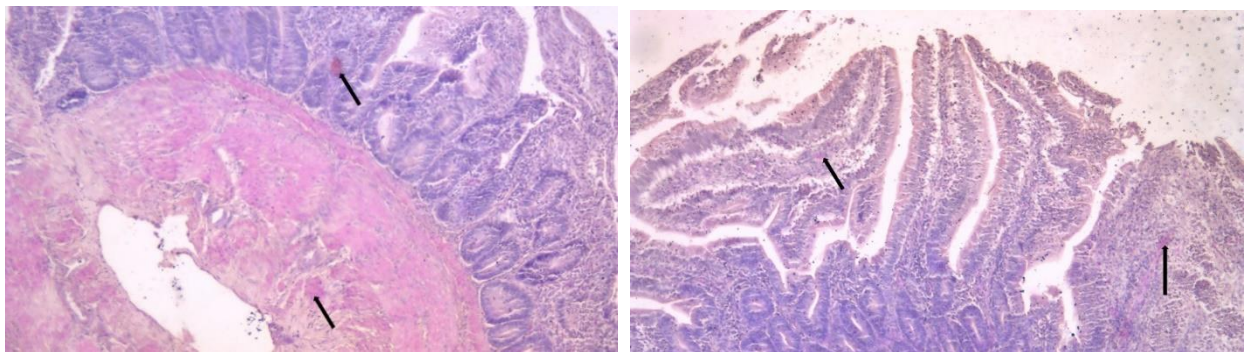


Figure 8: Intestinal lesions in histopathological slides (10X)

Furthermore, there were transmural inflammatory cell invasion and slight hemorrhages in the cecal tonsils that illustrated in (Figure 9).

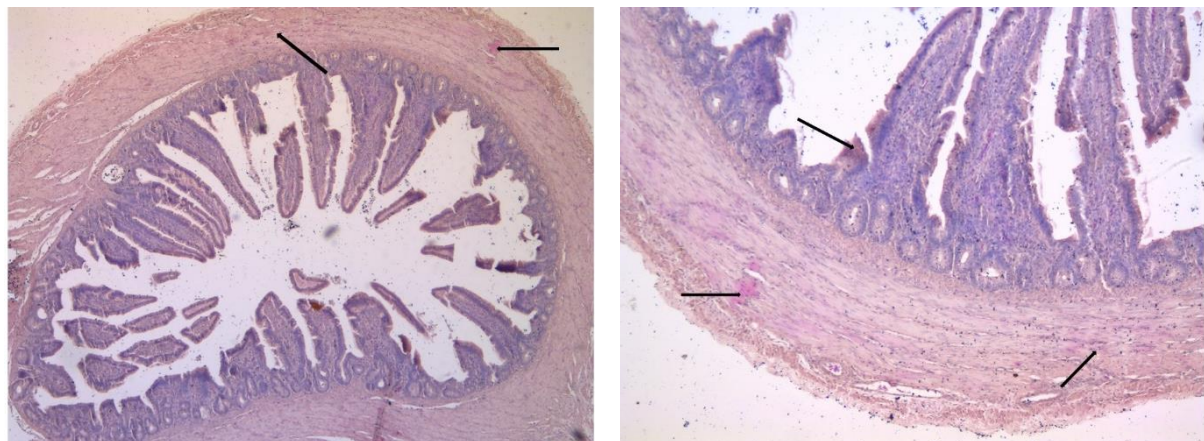


Figure 9: Histopathological slides showing lesions of cecal tonsils (4X in left and 10X in right)

2.3. Therapeutic Management

The flocks were treated with therapeutic management in the following ways:

Sulfonamides as antibiotic (Pulv. Supermed TS-1 @ 1gm/2L drinking water), Anti-stress element and immune stimulator (Pulv. Lisovit @ 1gm/2L drinking water), Combination of essential oil and 1-monolaurin as antiviral element (Liq. Fra c 12 @ 1ml/2L drinking water), Bromhexine Hydrochloric as mucolytic agent (Pulv. Mucospel vet @ 1gm/3L drinking water) and Vitamin A, D3, E preparation (Liq. Renasol AD3E @ 1ml/2-4L drinking water).

Some advise was offered to the farmer, such as providing clean drinking water, ensuring restricted biosecurity measures, such as having a foot bath in front of the farm, limiting people's access, and so on, in order to prevent disease exposure in the flock.

CHAPTER-III

Results

After five days, the farm was visited on 22nd August, 2023 to determine the current situation of the disease.

The birds' condition progressively became better, and the deaths of the birds had ceased happening. The outcome of the treatment was satisfactory. The owner said that there was no longer any mortality.

In order to maintain the health of his farm, the farmer also followed the instructions that were given. It might be a cause of the treatment's rapid response.



Figure 10: Healthy flock after treatment

CHAPTER-IV

Discussion

According to postmortem examination and clinical signs, the disease was diagnosed in this study. Clinical signs of ND, such as dyspnea, drowsiness and reduced feed intake, as well as coughing and gasping, sticky ocular and nasal discharge, violent diarrhea (bright green in color), CNS involvement, including tremor and neck and head twisting, leading to the suspicion that such occurrences were related to ND. These results matched (Okoye et al., 2000)'s findings more closely. It emerged that the birds showed greenish diarrhea, another significant sign of ND (Alexander, 2000).

Gross pathological lesions included extensive hemorrhages across the proventricular glands' mucosa and cecal tonsils (Figures 2 & 4). Similar lesions have been seen by (Mishra et al., 2000) and (Okoye et al., 2000). The intestinal wall included hemorrhagic lesions (Figure 3) that were correlated with necrosis, which supports the findings of (Jungherr et al., 2004) and (Kianizadeh et al., 2002).

For comprehensive study, the permanent slides were prepared. In the permanent slide of some samples such as lungs, intestine and cecal tonsils there showed some microscopic lesions that were severe congestion, hemorrhages, collapsed and ruptured alveoli, and a considerable number of inflammatory cells in the alveoli and interalveolar septa in lungs (Figure 5 & 6). In intestine small hemorrhages in the lamina propria, shrinkage and fusion of the villi, desquamation of the lining epithelium, and infiltration of inflammatory cells were found (Figure 7 & 8). There were transmural inflammatory cell invasion and slight hemorrhages in the cecal tonsils (Figure 9). Those are related to findings of (Congriev et al., 2020).

After diagnosis, the treatment was given such as Sulfonamides as antibiotic, Anti-stress element and immune stimulator, antiviral element, mucolytic agent and Vitamin A, D3, E preparation. Some advise was offered to the farmer, such as providing clean drinking water, ensuring restricted biosecurity measures, such as having a foot bath in front of the farm, limiting people's access, and so on, in order to prevent disease exposure in the flock.

The outcome of the treatment was satisfactory. The birds' condition progressively became better, and the deaths of the birds had ceased happening (Figure 10). There was no longer any mortality. The farmer also followed the advised biosecurity measures that might be a cause of the treatment's rapid response.

CHAPTER-V

Limitation

The study was carried out on a single farm with a population of 1000 chickens. The post-mortem examination was used to make the diagnosis. No serological test was conducted.

As a result, treatment and follow-up were carried out in order to evaluate treatment responsiveness.

CHAPTER-VI

Conclusion

The poultry industry is severely affected by Newcastle disease, which affects both commercial and backyard farming. The severity of the disease can be minimized through the proper vaccination schedule and therapeutic management. The prevalence of disease and associated loss can be reduced partially through strong biosecurity measures. Disease incidence on the farm is more likely due to poor hygiene maintain. This study was carried out in order to better understand the diagnosis and management of Newcastle disease in flocks of chickens. So as to prevent the disease from spreading again to the farm, the case had been followed up on to evaluate its treatment response. Therefore, the study would be helpful for future research.

References

- Alexander, D. J. (2000). Newcastle disease and other avian paramyxoviruses. *Revue Scientifique et Technique-Office International des Epizooties*, 19(2), 443-462.
- Barroeta, A. C. (2007). Nutritive value of poultry meat: relationship between vitamin E and PUFA. *World's poultry science journal*, 63(2), 277-284.
- Congriev, T., & Rafiqul. (2020). Sequential Pathology of a Genotype XIII Newcastle Disease Virus from Bangladesh in Chickens on Experimental Infection. *Pathogens*, 539.
- Eisa, M., & Omer, E. A. (1984). A natural outbreak of Newcastle disease in pigeons in the Sudan. *Veterinary Record (UK)*.
- Jungherr, E. L., & Hanson, R. P. (2004). Pathogenecity of NDV for the chicken. *Newcastle Disease virus. An evolving Pathogens. University, of Wisconsin, Medison*, 257-272.
- Kianizadeh, M., AiniI., G., & R., G. (2002). A comparative study on histopathologic effects of Iranian Newcastle disease virus isolates. *Archieves of Razi Institute*, 54, 17-29.
- Mayo, M. (2002). A summary of taxonomic changes recently approved by ICTV. In *Archives of virology*, 147(8) (pp. 1655-1656).
- Mebrate , T. A., & Dawit Akeberegn, D. G. (2019). Epidemiology, Diagnosis & Prevention of Newcastle Disease in Poultry. *American Journal of Biomedical Science & Research*, 50-59.
- Mishra, S., Kataria, J. M., S. R., Verma, C., K., & Mishra, J. P. (2000). Pathogenesis of Newcastle disease virus isolates in pigeon. *Indian Journal of Animal Sciences*, 70(11), 1125-1126.
- MSD Veterinary Manual. (n.d.). In *Newcastle Disease in Poultry* .
- Okoye, J. O., Agu, A. O., Chineme, C. N., & Echeonwu, G. O. (2000). Pathological characterization in chickens of a velogenic Newcastle disease virus isolated from guinea fowl. *Revue d'élevage et de médecine vétérinaire des pays tropicaux*, 53(4), 325-330.

- Paul, D. C., Haque, M. F., Abedin, M. Z., & Akter, M. S. (1990). Participation of women in poultry husbandry in rural Bangladesh. *In 10th AFRSE symposium held at machining university, USA*, 14-17.
- Samad, M. (2005). Poultry Science & Medicine. *In Poultry Science & Medicine* (pp. 504-528). Mymensing, Bangladesh: LEP publication.
- SK, R. (2007). Broiler Industry in Bangladesh. *International Poultry Show and Seminar: World's Poultry Science Association*. Bangladesh.
- Swayne, D., Glisson, J., Jackwood, M., Pearson, J., & Reed, W. (1998). *In P. A. Kennett Square, A laboratory manual for the isolation and identification of avian pathogens*. (p. 159).
- Tu, T. D., Van Phuc, K., Dinh, N. T., Quoc, D. N., & Spradbrow, P. B. (1998). Vietnamese trials with a thermostable Newcastle disease vaccine (strain I2) in experimental and village chickens. *In Preventive veterinary medicine*, 34(2) (pp. 205-214).
- Uddin, M. B., Ahmed, S. S., Hassan, M. M., Khan, S. A., & Mamun, M. A. (2010). Prevalence of poultry diseases at Narsingdi, Bangladesh. *International Journal of Biological Research*, 1(6), 09-13.

Acknowledgement

The author is eternally grateful and thankful to the Almighty “GOD”, the supreme ruler of the universe, without his blessing he would not have been able to successfully finish the research work and this clinical report on diagnosis and therapeutic management of Newcastle disease outbreak in a broiler farm: A comprehensive study of gross and microscopic lesions.

The author would like to express his gratitude to his respectful internship supervisor, Professor Dr. Kh. Nurul Islam of the Department of Anatomy and Histology in the Faculty of Veterinary Medicine at Chattogram Veterinary and Animal Sciences University, for his intellectual guidance, valuable advice, and ongoing encouragement throughout the study's duration to finish this clinical report.

The author would also want to express his heartfelt thanks to Professor Dr. A.S.M Lutful Ahasan, honorable vice chancellor of Chattogram Veterinary and Animal Sciences University.

The author expresses gratitude to Professor Dr. Mohammad Lutfur Rahman, Dean of the Faculty of Veterinary Medicine, and Professor Dr. A.K.M. Saifuddin, Director of External Affairs, for offering an exceptional internship program and research experience.

Last but not least, the author would like to express his deep appreciation and immense gratitude to his respected parents for their heartfelt blessings, affectionate feelings, encouragement, and other sacrifices made in order for the author to pursue higher education and successfully complete this study work. The author would also want to express her gratitude to his friends, well-wishers, and staff members who assisted at the time of the study and for their kind cooperation in getting this done.

The Author

November,2023

Biography

I am Sujoy Das, the son of Samarendra Das and Arunika Sengupta. I passed my Secondary School Certificate examination from Nasirabad Government High School, Chattogram in 2014 (G.P.A-5.00) and Higher Secondary School Certificate examination from Government Hazi Muhammad Mohsin College, Chattogram in 2016 (G.P.A-5.00). Now I am an intern veterinarian under the Faculty of Veterinary Medicine at Chattogram Veterinary and Animal Sciences University, Bangladesh. I am passionate about veterinary medical research and want to use my skills and creativity to help the nation overcome the present obstacles in this sector.