

**Medial Patellar Desmotomy for the Correction of Upward  
Patellar Fixation in Cattle at Upazila Veterinary Hospital,  
Anowara, Chittagong**



**A clinical report is submitted for Partial fulfillment of the Degree of  
Doctor of Veterinary Medicine (DVM)**

**A Clinical report submitted by:**

**ROLL NO: 13/44**

**REG. NO: 00973**

**INTERNSHIP ID: I-42**

**SESSION: 2012-2013**

**CHITTAGONG VETERINARY AND ANIMAL SCIENCES UNIVERSITY  
KHULSHI, CHITTAGONG-4225**

**Medial Patellar Desmotomy for the Correction of Upward  
Patellar Fixation in Cattle at Upazila Veterinary Hospital,  
Anowara, Chittagong**



**Submitted in partial of the fulfillment of the degree of  
Doctor of Veterinary Medicine (DVM)**

---

**EMA DAS**

Roll No. 2013/44

Reg. No. 973

Internship ID -42

Session: 2012-2013

---

**DR. MOHAMMAD MAHMUDUL  
HASSAN**

Professor and Head

Department of Physiology,  
Biochemistry and Pharmacology,  
Chittagong Veterinary and  
Animal Sciences University  
Chittagong.

# INDEX

<b>SL. No</b>	<b>Chapter</b>	<b>Contents</b>	<b>Page No.</b>
01		Abstract	4
02	I	Introduction	5-7
03	II	Materials and methods	8-13
04	III	Results	14-16
05	IV	Discussion	17-18
05	V	Conclusion	19
06	VI	References	20-21
07	VII	Acknowledgement	22
08	VIII	Biography	23

## Abstract

The Upward Patellar Fixation (UPF) is one of the most common non-inflammatory functional disorders of femoro-patellar articulation in cattle, buffalo, camel and horses. Though the infirmity does not endanger the life of the animal, it hampers locomotion. The animals of both sexes (but more in female) and 3 to 8 years of age are more commonly affected by UPF. The aim of the study was to describe the UPF and surgical procedure, success and post-operative care. A total of 8 cattle, of both sexes, from 3-7 years of age, of different breeds, activities and reproductive categories presenting a clinical diagnosis of patellar fixation were observed. The study was conducted from 1 February to 29 March, 2018 at Anowara Upazila Veterinary Hospital (UVH), with a history of lameness of right hind leg with dragging the tip of hoof and difficulties in walking. The detailed anamnesis and close inspection of the site of the problem confirmed the case as UPF and the cases were undergone for an open surgical intervention of medial patellar ligament desmotomy. The surgical correction was undertaken after securing and aseptic precautions. The medial ligament was cut with a curved knife at the depression site. After the medio-patellar desmotomy the animal stood up and started walking without showing any lameness in each cases. The post-operative therapy was given with the local and systemic antibiotics (SP vet®, 2.5gm), Antihistaminic preparation - pheniramine maleate (Asta vet®, 10 ml) and the animals should not be used for hard work for about 8-10 days.

---

**Keywords:** *Cattle, Upward Patellar Fixation, Medial Patellar Desmotomy*

# Chapter-I

## Introduction

Temporary or permanent fixation of the patella on the upper part of the femoral trochlea is called the upward patellar fixation (UPF). It has been reported almost in all domestic animals with a high incidence rate in cattle, It is one of the main non-inflammatory, serous, functional disorder of the tibia-femoral-patellar articulation (knee joint) in cattle characterized by temporary or permanent dislocation of the patella from its regular position during locomotion (Amresh Kumar, 2003, Krishnamurthy and Tyagi, 1978). The condition may occur temporarily which may spontaneously recover or permanent requiring surgical correction. The condition is economically important as it reduces the market value of the affected animal (Marudwar et al., 1980, Sutradhar, 2003).

The condition is widely distributed all over the world but extremely prevalent throughout India (Vaughan, 1960). The working bullock that is most often affected but the condition is also seen in cows (Vaughan, 1960. Gadgil, 1963. Dass et al., 1983. Sutradhar, 2002). The malady may be unilateral or bilateral, complete or incomplete (Vaughan, 1960., Ali et al., 1984).

In short, the patella glides up over the trochlea of the femur and as a result the medial ligament is tightly overstretched behind the medial trochlear ridge and this may prevent downward return of the patella (Dass et al. 1989, Venugopalon, 2000, Sutradhar, 2003). Again Bone et al. in 1963 said that in this condition the patella rides dorsally when the stifle is extended and the medial patellar ligament becomes “Hooked” over the medial ridge of the trochlea of the femur. Ali et al. (1984) also supported this opinion. The symptoms are exaggerated in advanced stages of the pregnancy due to relaxation of ligaments (Tyagi et al., 2001).

The occurrence of upward patellar fixation was lowest in summer season (Dass et al. 1983) and highest in winter (Sutradhar 2002).

In upward patellar fixation, the posture of the animal is normal at rest but every attempt to move the animal backwards be resisted. The affected limb is brought forward with a jerky flexion on every step. This appear after a few steps but reappear after a prolonged rest. In some animals, the symptoms are so severe, due to complete extension of the limbs that they

are unable even to move. Palpation of the trochlea revealed the absence of the patella in its original position and great tenses of the medial patellar ligament (Ali et al., 1984)

Medial patellar ligaments in stifle joint are surgical importance for the medial patellar desmotomy during upward patellar fixation (Tyagi and Singh, 2001). In bovines, most common, best and only successful treatment to correct upward fixation of the patella is the medial patellar desmotomy (Tyagi and Singh, 2001; Ali, 1984; Ramakrishna, 1972). For the medial patellar desmotomy, usually stab (close/ blind) method is preferable because there are either little or no hemorrhage with a small hole from exterior, not involve suturing, rapid healing with less postoperative complication, no need to give complete rest for a longer period, minimum cost of treatment and finally less time consuming (Sutradhar, B.C, 2003; Sharma, 1984; Marudwaret al., 1980). During the course of medial patellar desmotomy, a slight nicking of the middle patellar did not produce any noticeable lameness, but an accidental transaction of this ligament would render the animal permanently lame (Sahu ,1971).Some (4%) cases take about 1-2 weektime for complete recovery after close method of medial patellar desmotomy (Sutradhar, 2003). In Some cases of blind method, two or more attempts to severe the medial patellar ligament require during incomplete severe of this ligament (Ramakrishna, 1972). In blind method, it is very important to identify the medial patellar ligament which off course not an easy task to by palpation without having the knowledge of topographic anatomy of this ligament though it becomes thick, hard and less elastic during upward fixation of patellar ligaments (Tyagi et al., 1973).

The following factors are also considered associated with the above causes-

1. Very young drought purpose animal.
2. Conformation defect, hereditary influence and nutritional deficiency of mineral (Bone et al., 1963; Ali et al.,1984).
3. Sudden fall in the hole (Samad, 2001).
4. Drawing the plough in hard land or for long period.
5. Pulling water from very deep for a long period.
6. Gradual debility and weakness of muscles acting on stifle.
7. Occupational trauma, age of the animal or climatic conditions act only as secondary factors to aggravate the signs following development of the condition.

8. Workload may not be a direct cause, as the condition had been observed in non-working animals (Sharma,1984).

In Bangladesh, there has been little work done on the upward patellar fixation (Hossain, 1980, Ali et al., 1984., Rahman et al., 1984., Sutradhar, 2003). There has, however, been no report in the crossbred dairy cows of this disorder in this country. Therefore, the present study was undertaken with the following objectives.

**Objectives:**

1. To develop the clinical diagnosis and prevalence of dorsal patellar fixation in cattle
2. To observe the effect of treatment of upward patellar fixation
3. To observe the effect of age on the occurrence of upward patellar fixation
4. To observe the success of this surgery without any complications
5. To establish the post-operative manage

## **Chapter-II**

### **MATERIALS AND METHODS**

#### **2.1 Clinical case study and duration of study:**

The study was conducted over two months of time starting from 01 February to 29 March 2018 at Upazilla Veterinary Hospital (UVH), Anowara, Chittagong.

#### **2.2 Animal used for study:**

Draught and dairy cattle of different breeds which were affected with upward fixation of patella were selected for this study.

#### **2.3 History and observation:**

During this UVH rotation period 8 cases of upward patellar fixation were treated.

- It was observed that the posture of the animal was normal at rest but every attempt to move the animal backwards was resisted.
- The affected limb was brought forward with a jerky flexion on every step
- In acute cases, the hind limb was locked in extension. The stifle and hock cannot be flexed but the fetlock can. Limb was dragged in full extension during walk when one limb was involved animal moves by swing rigid affected limb outward and forward.
- Backward movements were restricted and cows were showing jerky flexion during progression or they drag their affected limb with flexed pastern. The symptoms in few cases disappear after few steps and again develop afterward

#### **2.4 Clinical examinations:**

2.4.1 Distal inspection: Distal inspection were done carefully to observe the presenting signs and recorded accordingly.

2.4.2 Direct palpation: Direct palpations were made by finger tips at the affected area. The medial patellar ligament was tensed, hard and less elastic and the absence of patella in its original position.



**2.5 Diagnosis:** Diagnosis was made on the basis of the anamnesis and clinical examination. By placing the thumb and the medium finger respectively at the tibial tuberosity and at the upper spot of the femoral medial trochlear crest, the medium point between these two anatomic references was established using the index finger. This procedure facilitated the identification of the medial patellar ligament.

**2.6 Preoperative care:** The preoperative care consisted of 12 hours fast. The animals were cast in lateral recumbence; the limbs were extended and held by ropes. The tibia-femoral-patellar articulation area was appropriately prepared, and antisepsis was done by a disinfectant solution containing iodophor, diluted on water as recommended. Local anaesthesia was applied in all animals by infiltrating approximately 20 ml of lidocaine hydrochloride into the gap located between tibia crest and the medial and intermediate patellar ligaments.

### **2.7 Treatment:**

All the cases were treated by surgical procedure of Medial Patellar Desmotomy (MPD) as a standard procedure to cure this disease known as Bassi's method in western countries (Moussu and Dollar, 1905). In India, Patra (1954) was the first surgeon to practice this technique. Both open and close or stab methods are in practise by standing or recumbency condition. Lateral recumbency is preferred in lactating and vicious animals.

### **Control and Anaesthesia**

The animal is controlled in lateral recumbency with the affected limb towards the ground and the upper unaffected hind leg is drawn forward and tied with fore legs. Affected hind leg, which downward is dragged backward and is tied with a piece of bamboo in order to expose the stifle joint and to tense the patellar ligaments. Analgesia is achieved by injecting local anaesthetic at the site of operation.

### **Site of Operation**

In the medical aspect of stifle joint where medial patellar ligament inserts into the inner aspect of the anterior tuberosity of tibia.

### **Option for correction**

In bovines the subcutaneous division of the medial patellar ligament is the common surgical treatment to correct upward fixation of patella. In western countries, the technique is known as **Bassi's method**. In Bangladesh both open and stab (closed) methods are in practice.

The index finger is moved upward on the anterior border of the tibia till the clinical tibial tuberosity is reached where three patellar ligaments are attached. The middle ligament is traced as a broadest and thickest among the three patellar ligaments, The finger is slipped towards at the level of medial condyle of the tibia into the groove between the middle and medial ligaments. The finger is then moved over the medial ligaments, which is felt as prominent cord.

**For open method**, a small incision is made in the skin directly over the medial ligament, starting immediately in front of the medial tibial tuberosity, towards the cranial tibial tuberosity. The index finger is passed in to the wound and the skin is separated from the fascia all around the site. The fascia is dissected to expose white glistening medial patellar ligaments. The ligament is exteriorized by passing a curved scissors/curved artery forceps/tenaculum flatwise under the ligaments from backwards. The ligament is then sectioned near its insertion using a knife. The wound is explored with index finger and undivided fibres of the ligaments are severed completely by scissors. The cutaneous wound is sutured with one or two interrupted sutures using nylon.


Protrusion of the adipose tissue through the gap created by the cut end of the ligament, cessation of crunching sound and immediate relief of the characteristic jerky flexions during progression are indications of a successful medial patellar desmotomy.

**In closed method**, a stab incision is made into the skin with a scalpel handle and blade immediately in front of the medial tibial tuberosity. Through this incision, the abscess knife, scalpel is passed flatwise, with its tip fixed in the 'V' shaped groove between the middle and medial patellar ligaments and the sharp edge of the instrument is directed towards the ligament. The ligament is then transacted by withdrawing the knife towards the operator. A small quantity of tincture iodine is instilled into the wound, which is left un-sutured.

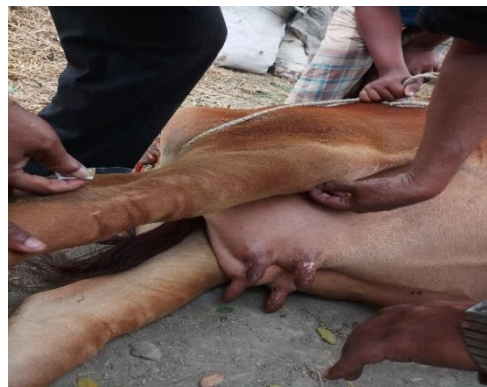In the bovine, injection of lugol's iodine solution or tincture iodine (5 to 10 ml) into the femoro patellar joint is stated to be affected in many cases. A swelling of the joint develops after the injection, which gradually subsides within one or two weeks. The animal should be

given rest for two to three weeks. Then the animal was allowed for walk. Distant observation was made for characteristic jerky flexion during progression is the indication of a successful medial patellar desmotomy (Tyagi, 2001). If there was any sign of lameness during walking after surgical approach, the undivided ligament can be severed within a short time.

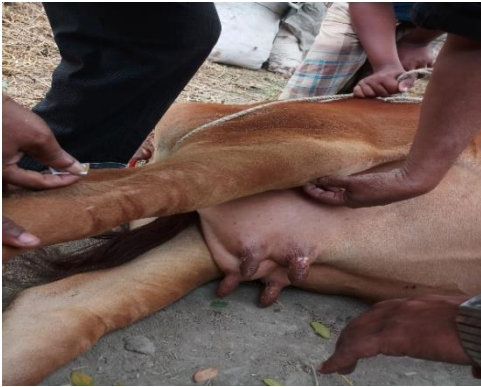**The postoperative care:** The postoperative therapy was given with the local and systemic antibiotic, antihistaminic drug and regular dressing. The antibiotic, penicillin-streptomycin combined preparation (SP-vet, Acme) was given. 2.5 gm SP-vet powder was diluted with 10ml distilled water and injected intramuscularly and SP-vet powder also given at the wound. Antihistaminic preparation, Pheniramine maleate, Asta-vet (Acme) 10ml was given intramuscularly. The removal of the sutures was recommended 10th to 12th days postoperatively.



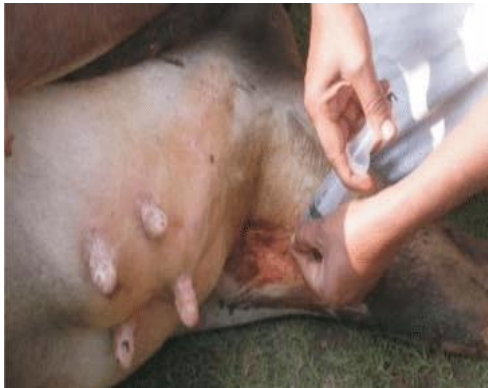Dragging of right hind limb



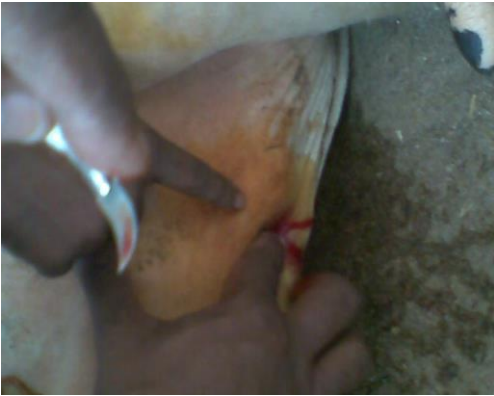Casting of animal



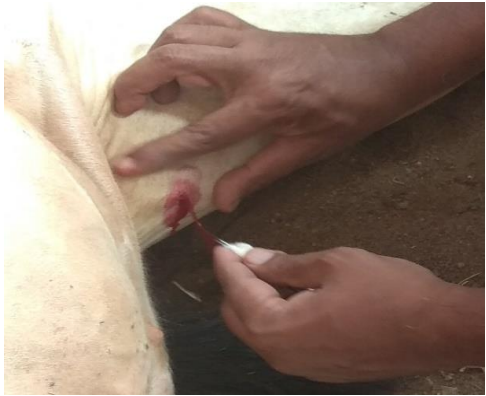Interpret the location



Applying anaesthetic agent locally




Find out the medial patellar ligament



Cutting the ligament



Postoperative care



Animal postoperatively walking

**Table-1. Drugs used in the study:**

<b>SL. No</b>	<b>Type of drug</b>	<b>Generic name</b>	<b>Trade name</b>	<b>Dose</b>	<b>Route</b>
1	Antibiotic	Penicillin Streptomycin	Inj. SP-vet (Acme)	10ml	IM
2	Antihistaminic	Pheniramine meleate	Inj. Asta-vet (Acme)	10ml	IM
3	Anaesthetics	Lidocaine HCl	Inj. Jasocaine (Jayson)	10ml	Local
4	Disinfectants	Povisep	Iodophor	Required amount	Local
5	Disinfectants	Potash	Potassium per manganate	Required amount	Local

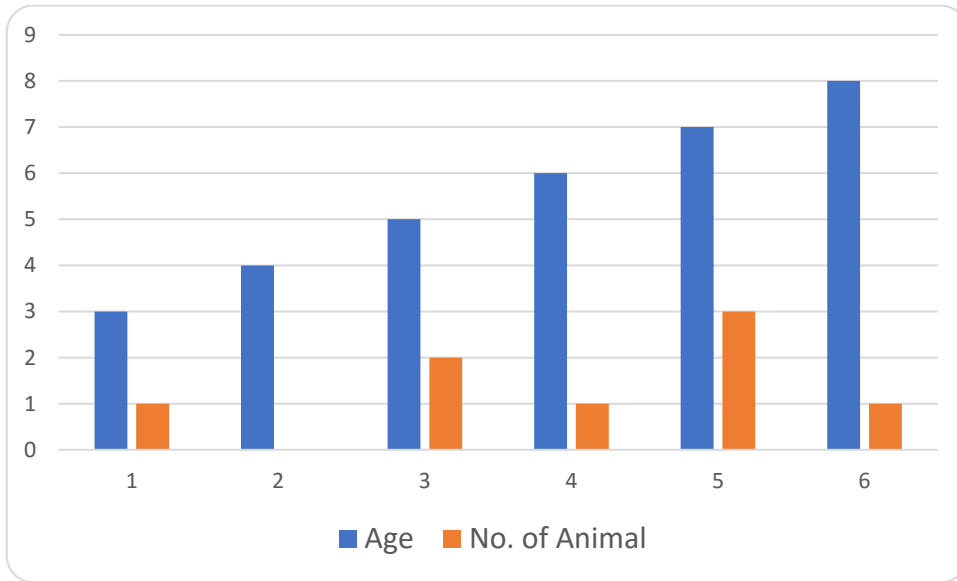
## Chapter-III

### RESULTS

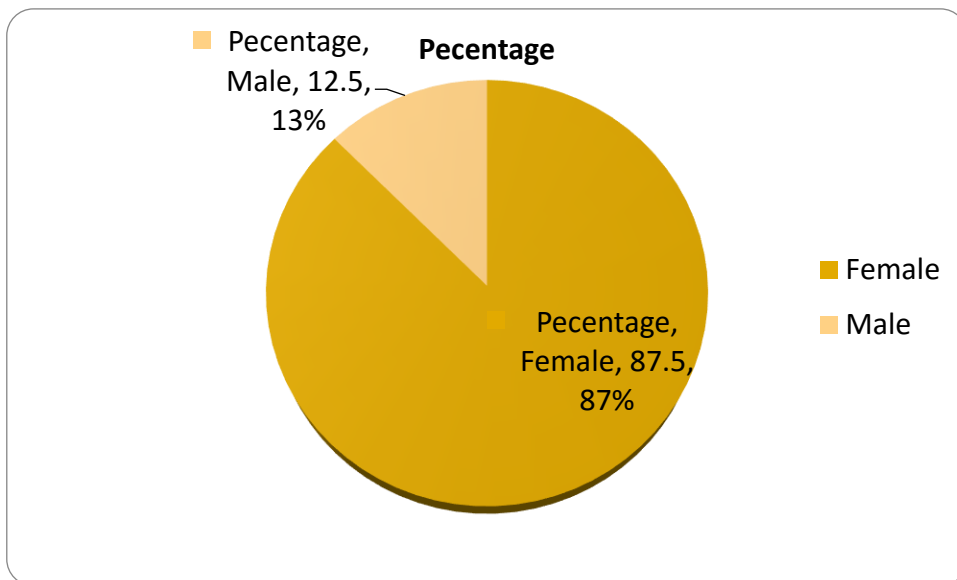
- ❖ MPD conducted by the closed method in the lateral recumbency was successful in eliminating the signs of lameness.
- ❖ This showed that the lateral recumbency method of restraining animals can be selected for better results.
- ❖ For the MPD, stab (close/blind) method is preferable because-
  - There are either little or no hemorrhage with a small hole from exterior
  - Not involve suturing, rapid healing with less post-operative complications
  - No need to give complete rest for a longer period
  - Minimum cost of treatment and finally less time consuming
  - No complications such as accidental severing of adjacent ligaments was observed (Mejbah-uddin et. al.,2009)

**Table 2: Effects of different variables on the occurrences of upward patellar fixation:**

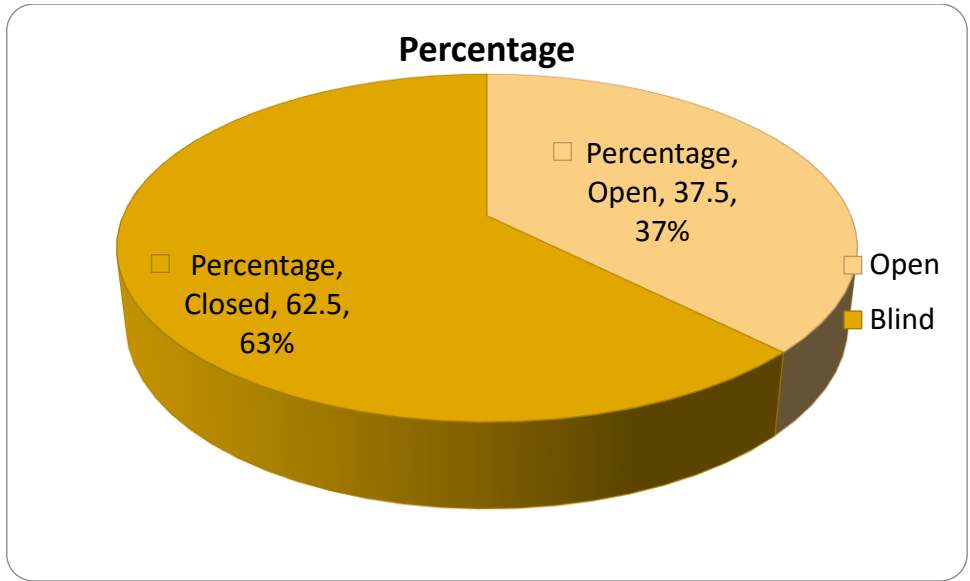
SL No	Species	Age (Year)	Sex	Breed	Type	Method of operation	Affected leg		
							Right	Left	Both
1	Cattle	5	Female	Local	Draught	Closed	√		×
2	Cattle	7	Female	Local	Draught	Closed	√		×
3	Cattle	5	Female	Cross	Dairy	Closed			√
4	Cattle	3	Female	Cross	Dual	Open	√		×
5	Cattle	6	Female	Local	Draught	Open	√		×
6	Cattle	5	Male	Local	Draught	Closed		√	×
7	Cattle	7	Female	Cross	Dual	Open		√	×
8	Cattle	5	Female	Local	Draught	Closed	√		×



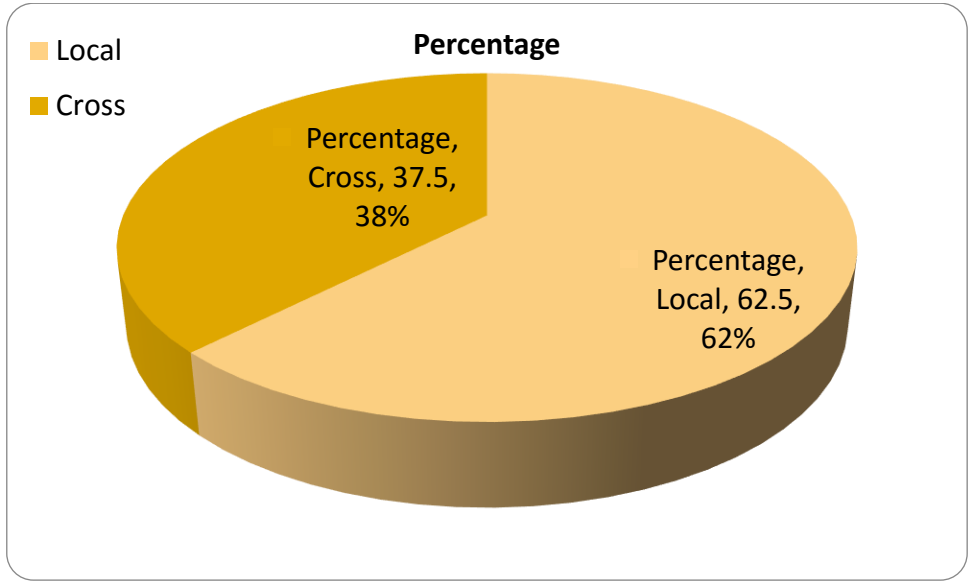
**Fig 1: Occurrence of diseases in different age.**



**Fig 2: Effect of sex on occurrence of diseases.**



**Fig 3: Methods of desmotomy.**



**Fig 4: Effect of Breed on occurrence of diseases.**

Out of 8 treated animals, all 8 were recovered completely after the operation. 3 cases were performed under open method of desmotomy in lateral recumbent position and another 5 were performed under blind method of desmotomy in lateral recumbent position. The wound was closed by simple interrupted suture. The operated animals were kept under postoperative care and postoperative rest. The result of open method showed that the technique was simple and quite satisfactory but a little bit time consuming.



## Chapter IV

### DISCUSSIONS

Upward patellar fixation (recurrent/permanent) is one commonly seen functional disorders of femoro- patellar articulation in large animal, although it is not a life-threatening event but affects greatly on the animal welfare without treatment there is rare spontaneous recovery occurs in some individuals, especially cattle in grass. (Weaver, 1986). From the etiology it is obvious that animals engaged in hard work are generally affected from this condition. But under this study the author found most of the affected animals were female and were draft animals, age ranges from 5-8 years. These findings differ from the study of Dass et al.1983, in which he showed that females were less prone to than male. But Gadgil, 1963, supports these study findings, where he recorded the ratio of male to female was 1:2 and Sutradhar in 2002 also recorded that female and male percentages were 59 and 41 respectively. But under this study most of the cases were female. It may be due to-

1. Farmer's interest on dairy cows and farms.
2. Now a days, ploughing, transportation are done by mechanical means, this is why draft male draft animals are generally decreasing but farmer use their dairy cows for ploughing.
3. AI decreases the interest on bull rearing.

Patra in 1954 held that work might not be a direct cause, as the disease is also seen in cows. Krishnamurthy et al. 1978 directly said that sex had no relationship with this disease condition. Furthermore, from the available literature, no author found this condition in crossbred animal especially in case of male, may be due to they were not used for draft purpose since they are hump less and disposed in early stage.

The dairy cows got this condition because under this study it was found that, some cows were in poor diet and some were found in good body condition. Vaughan in 1960 felt that either poor diet or some type of strain on the metabolism in animals predisposed to this condition. Lack of exercise due to confinement, the animals in the stalls causes the relation of the ligaments, which may lead to upward patellar fixation.

In the study, there is found that the crossbred animals are affected. It is not supported by Dass et al., 1983. In his study area "Chota Nagpur, India", he found no incidence of upward patellar fixation in crossbred animals. He thought that, this might be due to the fact that

crossbred animals were generally stall fed with nutritious diet. But in this study area the animals suffered in nutrient deficiency.

Another study result by Krishnamurthy et al. 1975, where author felt that dorsal fixation of the patella over the trochlea due to spasm of the quadriceps muscles only. This is partly in agreement with the views of Rathor, 1968, who stated that dorsal fixation of patella occurs due to spasm of high muscles rather the articular defects. This result was applied on both dairy and draft animals.

Upward patellar fixation is a serious non-inflammatory condition of the animals. So this condition should be corrected. For correction of this condition operative procedure is the best, because, the technique of Tincture iodine was easy, but the animals required rest for a long period and 50% of the case the condition recurred after 2 to 3 months of 1<sup>st</sup> injection (Ramakrishna, 1972). The medial patellar desmotomy was the successful treatment for this condition. Sutradhar in 2003 also suggested for medial patellar desmotomy for correction of condition ( Ali in 1984 ). In the present study 5 cases out of 8 cases were subjected to blind method of desmotomy and rests three were done by blind method of desmotomy. Experience is required to do a medial patellar desmotomy by closed method- because it produce a minimum skin wound, but care must be taken while passing the blade to prevent breaking. It is easy to identify three medial patellar ligaments because it becomes thick, hard and less elastic (Tyagi et al. 1973) which help easy identification of the ligament. Crushing sound and or immediate relief of the characteristic jerky flexions during progression is the indication of a successful medial patellar desmotomy (Tyagi et al., 2001).

## **Chapter V**

### **CONCLUSIONS**

The study was performed with 8 affected cases of upward patellar fixation in cattle and both open and closed methods of desmotomy were observed. From the observation it was evident that the closed method of desmotomy along with removal of the piece of ligament was the best treatment for upward patellar fixation. It was also found that the condition frequently occurred in cattle of over four years. These results demonstrate that the surgical technique of medial patellar desmotomy, with the animal extended in lateral recumbency was effective and performed easily. As for the possible triggering factors, breed predisposition was not observed. Females were more susceptible, especially those which had just calved. Finally, nutritional deficiency seems to be the most important factor affecting its pathogenesis.

## **Chapter VI**

### **REFERENCES**

- Dass, L.L., Sahay, P.N., Ehsan, Md. And Khan, A.A. (1983). A report on the incidence of upward fixation of patella (Stringhalt) in bovines of Chota Nagpur Hilly Terrian. Indian Veterinary Journal. 60: 628- 630.
- Sutradhar, B.C. (2003). Medial patellar desmotomy in the buffalo on upward patellar fixation. The Bangladesh Veterinarian. 20(1): 25-28.
- Tyagi, R.P.S., Krishnamurthy, D. and Kharole, M.U. (1973). Studies on histopathology of ligaments in bovine animals affected by upward fixation of the patella. The Veterinary Record. 93: 362-364.
- Mejbah-uddin M, Salim Reza M, Nurul Islam K, Faruk Miazi O, Ahmed S.U. (2009). Surgical anatomical measurements of patellar ligaments for blind method of medial patellar desmotomy of cattle during upward patellar fixation in Bangladesh. International Journal Morphol. 27:311–315
- Ali, M.A. and Hashim, M.A. (1984). Upward fixation of patella in cattle. Bangladesh Veterinary Journal. 18: 69- 70.
- Pallai, M. Ramakrishna (1944). A Note on Chronic Luxation of Patella among bovines with special reference to its aetiology. Indian Veterinary Journal 21:48-54.
- Moussu, G. and Dollar, J.A.W. (1905). Diseases of Cattle, Sheep, Goats and Swine. Bradburry Agnew and Co. Ltd., Printers, London and Tom bridge
- Amresh Kumar, (2003). Veterinary Surgical Techniques. Pp. 399- 401.
- Bone, J.F., Catcoll,E.J.,Gabel, A.A., Johnson, L.E. and Riby, W.F. (1963). Equine Medicine and Surgery.2<sup>nd</sup> (ed). Dorsal patellar fixation. American Veterinary Publications. Inc. California. Pp. 576- 590.
- Frank, E.R. (1939). Veterinary Surgery. 7<sup>th</sup> (ed). Burgess Publishing Company. USA., Pp. 321-322.
- Gadgil, B.A. (1963). M.V.Sc. Thesis. Vikram University. Ujjain, India.
- Getty, R. (1975). Sisson and Grossman's The Anatomy of The Domestic Animals. 5<sup>th</sup> (ed). W.B. Saunders Company. USA. Pp. 790.
- Hossain, M.A. and Haque, M.A. (1989). Medial patellar desmotomy in bovine upward patellar fixation. The Bangladesh Veterinarian. 6: 14- 16.

- Krishnamurthy, D. and Tyagi, R.P.S. (1978). Upward fixation of patella in bovines- a report based on 450 clinical cases. *Indian Veterinary Journal*. 55: 567- 571.
- Krishnamurthy, D. and Tyagi, R.P.S. (1974). Recurrence of subluxation of patella icattle after medial patellar desmotomy. *Indian Veterinary Journal*. 51: 379- 382.
- Kumar, A. (1996). *Veterinary Surgical Techniques*. 3<sup>rd</sup> (ed). Vikas Publishing House Pvt. Ltd. 576 Masjid road, Jangpura, New Delhi. Pp. 399-401.
- Marudwar, S.S. and Kulkarni, P.E. (1980). Simpler and safer technique for locating and cutting the medial patellar ligament. *Indian Veterinary Journal*. 57: 419- 421.
- Patra, B.N. (1954). Upwad patellar fixation a clinical report. *Indian Veterinary Journal*. 30: 507- 508.
- Rahman, M., Rahman , A., Routledge, R.F. and Islam, A. (1984). Bovine upward fixation of patella in Bangladesh. *Livestock Adviser*. 9: (9- 11).
- Ramakrishna, O. (1972). Comparative studies on the treatment of chronic subluxation of the patella in buffaloes. *Indian Veterinary Journal*. 49(11): 1150- 1153.
- Samad, M.A. (2001). *Pashupalan O Chikitshavidya. Anaesthesiology and Surgery*. 2<sup>nd</sup> (ed). LEP publication, 11/4 Toynabi circular road, Matijhil C/A Dhaka-1000. Pp. 900-903.
- Sharma, K.B., Joshi, Y.G. and Tanar, P.K. (1984). A report on the incidence of upward fixation of patella in bovines of Udaipur area in Rajasthan. *Indian Veterinary Journal*. 61: 689-691.
- Vaughan, L.C. (1960). *Orthopedic Surgery in farm animals*. *The Veterinary record*. 72(21): 399-403.
- Kugopalan, A.(2000). *Essentials of Veterinary Surgery*. 3<sup>rd</sup> (ed). Oxpond and IBH. Publishing Co. Pvt. Ltd. New Delhi, Calcutta. Pp. 508

## Chapter-VII

### ACKNOWLEDGEMENT

All praises are due to the God, the Creator and Supreme Authority of the universe, who enable the author to complete this assignment. I am grateful to my teacher and supervisor **Professor Mohammad Mahmudul Hassan**, Head, Department of Physiology, Biochemistry, and Pharmacology, Chittagong Veterinary and Animal Sciences University, for his valuable suggestions and guidance.

I am also grateful to **Professor Dr. Gautam Buddha Das**, Vice Chancellor, and **Professor Md. Abdul Halim**, Dean, Faculty of Veterinary Medicine, **Professor Dr. A. K. M. Saifuddin**, External Affairs, Chittagong Veterinary and Animal Sciences University for their continuous inspiration to accomplish the study.

I wish to express my gratitude to my placement provider **Dr. Delowar Hossain**, Upazila Livestock officer, Anowara, Chittagong, to help me by giving the opportunity to work and collect important information.

Finally, by no means least, I am really very much grateful to all of my teachers, friends, my parents, and all who have inspired me in various ways for successful ending of the Study.

**The Author**

## **BIOGRAPHY**

I am Ema Das, daughter of Uttam Kumar Das and Ashru Kona Mohajan. I passed Secondary School Certificate Examination in 2010 followed by Higher Secondary Certificate Examination in 2012. Now I am an intern doctor under the Faculty of Veterinary Medicine in Chittagong Veterinary and Animal Sciences University. As an upcoming veterinarian I would like to dedicate my rest of life for the welfare of animals. I am keen to be a field veterinarian as well as a pet practitioner.