

Understanding the predisposing factors and outcome of jaundice in a domestic cat : A case study



A clinical report submitted in partial satisfaction of the requirement for the Degree of Doctor of Veterinary Medicine (DVM)

By :

Nasrin Akter Tonny

Roll No : 17/44

Reg No : 01874

Intern ID : 36

Session : 2016-17

Faculty of Veterinary Medicine

Chattogram Veterinary and Animal Sciences University

Khulshi, Chattogram – 4225, Bangladesh

Understanding the predisposing factors and outcome of jaundice in a domestic cat : A case study



Approved by :

Dr. Mohammad Mejbah Uddin

Professor

Department of Anatomy and Histology

Faculty of Veterinary Medicine

Chattogram Veterinary and Animal Sciences University

Khulshi, Chattogram – 4225, Bangladesh

Table of Contents

<u>Contents</u>	<u>Page No</u>
Statement of author	IV
List of Figure(s)	V
List of Acronyms Symbols Used	VI
Abstract	VII
Chapter 1: Introduction	01
Chapter 2: Case Presentation	03
2.1. Case History and Clinical Examination	03
2.2. Laboratory evaluation of the patient	04
2.2.1. Serum Biochemistry Profile	04
2.2.2. Diagnostic Imaging Evaluation	05
2.3. Treatment	06
Chapter 3: Discussion	07
Limitation of the Study	09
Conclusion	09
References	10
Acknowledgement	11
Biography of the author	12

Statement of Author

I, Nasrin Akter Tonny, hereby attest that I have satisfactorily completed all of the tasks listed in this report. The information was obtained from all of the books, regional, international, and other sources. Each and every citation has been correctly acknowledged. Therefore, I am fully accountable for gathering, processing, maintaining, and disseminating all of the data gathered for this report.

.....

The Author

List of Figures

<u>Figure</u>	<u>Title</u>	<u>Page No</u>
Figure 1.	Depressed and weak patient	03
Figure 2.	Pale yellow mucous membrane in the conjunctiva	03
Figure 3.	Blood came out with urine	04
Figure 4.	Thickening and ruptured liver parenchyma were observed in the ultrasound examination	05
Figure 5.	The urinary bladder lining was found to be thickened and irregular in the ultrasonography examination.....	05
Figure 6.	Hepatomegaly and Splenomegaly were observed in x-ray findings	06
Figure 7.	Fluid treatment with the Hartmann's solution was administered intravenously to treat the patient	06

List of Acronyms Symbols Used

Abbreviation	Elaboration
No	Number
ml	Milliliter
$\mu\text{mol/L}$	Micromole per liter
mg	Milligram
Kg	Kilogram
$^{\circ}\text{F}$	Degree Fahrenheit
$\mu\text{/L}$	Micromole
mg/dl	Milligram per deciliter
ALT	Alanine Aminotransferase
AST	Aspartate Aminotransferase
ALP	Alkaline Phosphatase
SGPT	Serum Glutamic-Pyruvic Transaminase
SGOT	Serum Glutamic-Oxaloacetic Transaminase
CBC	Complete Blood Count
PCV	Packed Cell Volume
TTPHRC	Teaching and Training Pet Hospital and Research Center

Abstract

Jaundice, also known as icterus, is characterized by a yellow discoloration of the sclera, unpigmented skin, and visible mucous membranes that results from a high bilirubin level in the blood and tissues. It is a clinical manifestation, not a disease, of an underlying problem. The present study was therefore aimed at learning how to manage a jaundice patient, the preferred method of diagnosis, and the necessary treatment. The study would cover the etiology, clinical symptoms, and utilization of ancillary aids in the diagnosis of pathologies that cause jaundice in cats. A 10-month-old cat with intermittent pyrexia, anorexia, lethargy, and bloody urine was brought to the TTPHRC (Teaching and Training Pet Hospital and Research Center) in Dhaka. It also had a history of not getting deworming medicines for the previous 6 months. Elevations in two liver enzymes, SGPT (Serum Glutamic-Pyruvic Transaminase) and SGOT (Serum Glutamic-Oxaloacetic Transaminase), linked to hepatocellular damage or membrane leakage, were observed in the biochemistry profile, as was hyperbilirubinemia. An ultrasound examination and an x-ray revealed hepatomegaly, splenomegaly, and cystitis in the case of diagnostic imaging evaluation. Following the diagnosis of jaundice, 60 ml of Hartmann's solution was administered intravenously to achieve rehydration. Again, the antibiotic amoxicillin trihydrate, an anti-hemorrhagic drug, and an anti-inflammatory drug had been used, and supportive care was also given. The entire course of treatment lasted seven days. However, the patient had died within 4 days of treatment.

Keywords : Hyperbilirubinemia, Jaundice, Icterus, TTPHRC, Hartmann's solution.

Chapter 1 : Introduction

The term "jaundice" refers to a yellow discoloration of the visible mucous membranes, sclera, and unpigmented skin brought on by an elevated level of bilirubin in the blood and tissues (Sherding, 2000). Yellow jaundice or icterus are additional names for the same condition. Icterus is a clinical symptom that indicates the presence of an underlying disease; it is not a disease in itself (Davydova & Kurochkin, 2021). Icterus will disappear if the primary illness is identified and appropriately treated.

Less than 6 $\mu\text{mol/L}$ should be the normal limit for serum bilirubin levels (Davydova & Kurochkin, 2021). When blood bilirubin concentration exceeds 2 mg/dl (35 $\mu\text{mol/L}$), or more than five to ten times above normal, jaundice typically manifests itself (Sherding, 2000). The level of bilirubinemia (presence of bilirubin in blood) determines the degree of jaundice. A rise in the amount of unconjugated (indirect) bilirubin in the blood is indicated by the conjunctiva's steady pale yellow color, while an increase in conjugate (direct) bilirubin is indicated by the conjunctiva's bright yellow color, which ranges from orange-yellow to brown-yellow. The inner surfaces of the auricular shells and thighs are the areas of the body with the thinnest, least pigmented skin where jaundice is most noticeable (Davydova & Kurochkin, 2021). In the dog, bilirubinuria (presence of bilirubin in the urine) frequently occurs before clinically apparent jaundice, whereas in the cat, the onset of bilirubinuria is typically accompanied by clinical icterus (Londoño et al., 2019). Jaundice is mainly visible in the gingivae (gums), sclerae (white area of the eyes), and pinnae (ear flaps) because much of a cat's skin is covered by fur.

Jaundice is typically categorized into three fundamental groups: pre-hepatic, hepatic, and post-hepatic jaundice (Londoño et al., 2019).

Pre-hepatic Jaundice :

Pre-hepatic jaundice results from three fundamental processes: excessive production, diminished hepatic absorption, and diminished conjugation. Pre-hepatic jaundice in cats is most frequently caused by hemolysis, which happens when there is an excess of heme produced due to the red blood cell disintegration that exceeds the liver's capacity to conjugate it and send it through the regular excretory channel. The

hemolytic disease or hemoparasite may be a primary or secondary factor in the destruction of red blood cells.

Hepatic Jaundice :

Hepatic jaundice is a sign of direct liver disease or hepatic damage and dysfunction that can be brought on by infection, neoplasia, toxicity, degeneration, inflammation, or a metabolic disorder.

Post-hepatic Jaundice :

Any lesion that can impair the passage of bile from the liver results in post-hepatic icterus. These conditions include parasite origins, primary or secondary neoplasia, inspissated bile production, inflammatory swelling or fibrosis, and others. Hepatic and post-hepatic jaundice are both potential effects of acute pancreatitis.

Chapter 2 : Case Presentation

2.1. Case History and Clinical Examination

A ten-month-old male domestic cat weighing 3 kg was brought to the TTPHRC (Teaching and Training Pet Hospital and Research Center), Purbachal at Dhaka, in a distressed state with a history of intermittent pyrexia, anorexia, weakness, and bloody urine. Over the preceding 48 hours, it had become steadily more depressed (Figure 1), and had stopped eating. Both a recent medicine administration and a history suggesting a hazardous bite were absent. There was a history of the patient not receiving deworming medication for the last 6 months.

Clinical examination of the animal exhibited body temperature 99.7 °F , severe dehydration, pale yellow mucous membrane in conjunctiva (Figure 2), and also blood in urine (Figure 3). The heart rate was 110/minute and the pulse was weak. Heart sounds were mild abnormal.

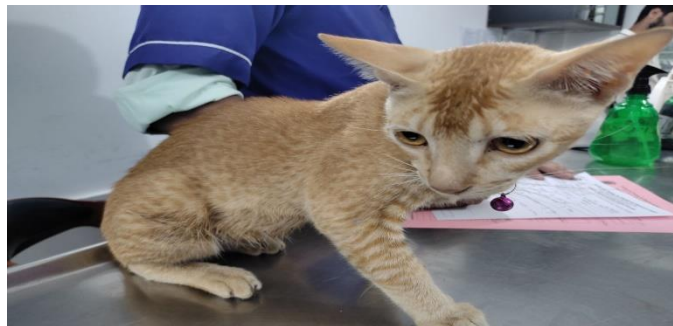

Figure 1. Depressed and weak patient

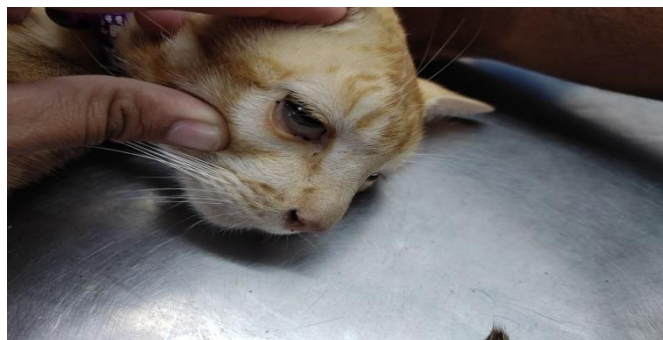


Figure 2. Pale yellow mucous membrane in the conjunctiva

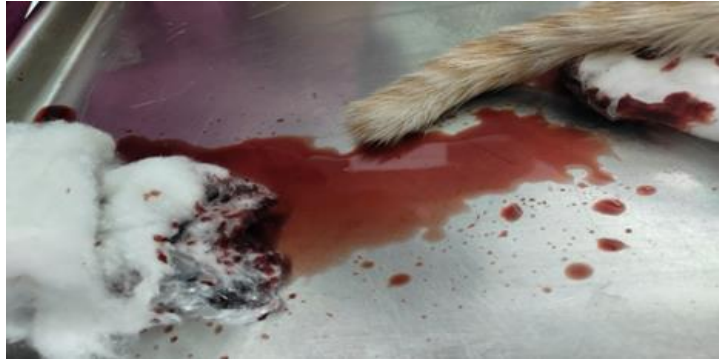

Figure 3. Blood came out with urine

Blood and urine samples were taken for biochemical testing, and the animal was transported for an ultrasound and radiographic examination to check on the status of the liver.

2.2. Laboratory evaluation of the patient

The pathophysiology of jaundice is typically confirmed by laboratory tests. They may occasionally also present with a particular etiology (Chopra & Griffin, 1985). A complete blood count, urinalysis, routine serum biochemistry assessments, serum bile acid liver function tests, diagnostic imaging, and hemostasis evaluations should all be included in the laboratory evaluation (Sherding, 2000). At TTPHRC, the serum biochemistry test and diagnostic imaging were performed on the patient.

2.2.1. Serum Biochemistry Profile

Elevations in Alanine Aminotransferase (ALT) and Aspartate Aminotransferase (AST), two liver enzymes linked to hepatocellular damage or membrane leakage, were found in the biochemistry profile. The level of Alanine Aminotransferase (ALT) or Serum Glutamic-Pyruvic Transaminase (SGPT) had risen to 150 μL , where the normal value is 10 to 100 μL . Besides, the level of Aspartate Aminotransferase (AST) or Serum Glutamic-Oxaloacetic Transaminase (SGOT) had risen to 185 μL , where the normal value is 10 to 100 μL . The concentration of Alkaline Phosphatase (ALP) enzyme had increased to 110 μL , which was more than twice the upper limit of the normal range (10-50 μL). The normal serum bilirubin concentration range is usually 0.1 to 0.4 mg/dl; however, the level of bilirubin had increased to 3 mg/dl.

Furthermore, while the above values might aid in the diagnosis of jaundice in that patient, the category of jaundice was not confirmed.

2.2.2. Diagnostic Imaging Evaluation

In order to properly assess an icteric patient, diagnostic imaging is a crucial part of the process. Simple abdominal radiography and abdominal ultrasonography are the standard techniques (Chalmers & Matull, 2014).

On ultrasound examination; there was a thick and ruptured capsule of liver (Figure 4), and there was also a thickened, irregular urinary bladder lining (Figure 5), which was suspected to be cystitis.

In addition to ultrasound evaluation, radiographs were also used. The liver and spleen were found to be larger than usual on radiography, which indicates that the abdomen radiograph assesses hepatomegaly and splenomegaly as well (Figure 6).

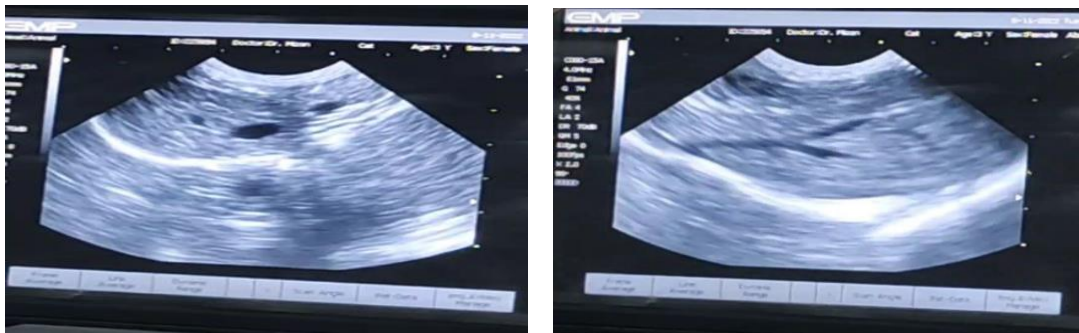


Figure 4. Thickening and ruptured liver parenchyma were observed in the ultrasound examination.

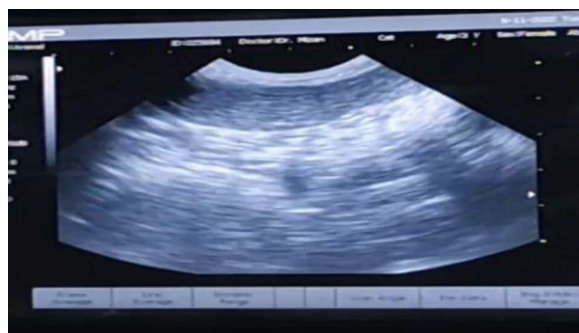

Figure 5. The urinary bladder lining was found to be thickened and irregular in the ultrasonography examination.

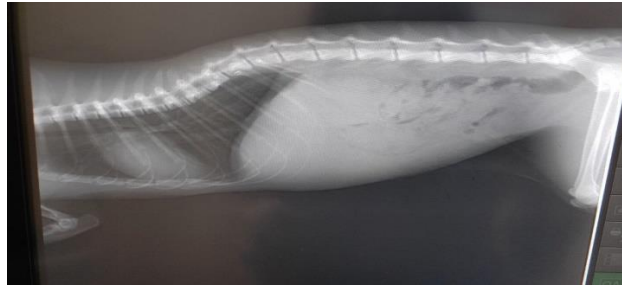


Figure 6. Hepatomegaly and Splenomegaly were observed in x-ray findings

2.3. Treatment

After confirmation of jaundice, treatment was initiated with 60 ml of Hartmann's solution intravenously twice a day as fluid therapy to ensure rehydration of the animal (Figure 7). Once the cat was hydrated, the antibiotic Amoxicillin trihydrate (Moxin IM 500mg, Opsonin Pharma) was administered 0.5ml intramuscularly twice a day, and the anti-inflammatory medication Dexamethasone (Roxadex 5mg/ml, Nuvista Pharma) was given 0.2ml intramuscularly once a day to reduce the liver and bladder inflammation. Moreover, the anti-hemorrhagic drug Tranexamic acid (Tracid Vet 100mg/ml, ACME) was given 0.6 ml subcutaneously once a day. As supportive care, the vitamin B complex (V-Plex in a 2 ml ampule, ACME) was administered 0.3 ml intramuscularly once a day, and to improve the patient's immune system, a herbal liver tonic called Silymarin (Silybin capsule of 70 mg, Square) was given as half a capsule once a day. All the treatment was administered for 7 days.

However, in spite of proper treatment and supportive care, the patient died within 4 days of treatment.

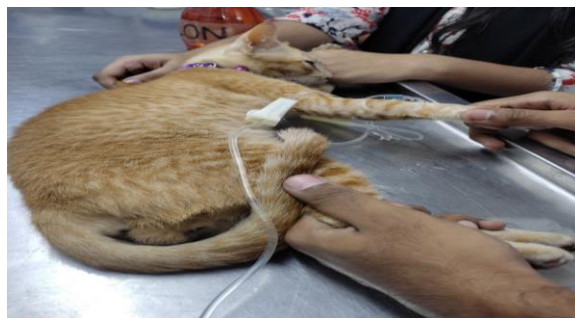

Figure 7. Fluid treatment with the Hartmann's solution was administered intravenously to treat the patient.

Chapter 3 : Discussion

Early clinical symptoms in this animal were rather distinctive, but they did not point to a certain diagnosis. The cat should, however, be evaluated for signs of liver illness because of the existing jaundice. When examining a cat who has jaundice, simple tests like hematocrit and serum protein concentration are necessary to make the correct diagnosis (Davydova & Kurochkin, 2021).

The packed cell volume (PCV) of the blood sample, total hemoglobin, and total red blood cell numbers are all evaluated by the CBC to determine whether anemia is present and how severe it is. An elevated white blood cell count on the CBC (complete blood count) may signify the presence of infection or inflammation in the liver and/or gallbladder. If anemia is present, it is often relatively mild, as opposed to the more severe anemia linked to hemolysis or red blood cell destruction. The results of these tests will show whether the cat or dog is anemic. Whether or not hemolysis is the source of the anemia will also be determined with the help of the CBC components (Davydova & Kurochkin, 2021). However, in our study, there was no facility to assess the CBC (complete blood count) because the hospital lacked hematological services. Though we were unable to confirm if hemolysis was the cause of anemia, we assumed the presence of hemolytic anemia based on clinical symptoms such as pale mucous membranes and bloody urine.

A study of (Lathe & Ruthven, 1958) stated that for more than 50 years, scientists have known that two types of bilirubin occur in the serum of clinical cases of jaundice. Unconjugated and conjugated bilirubin have previously been mentioned. Total serum bilirubin equals the sum of direct bilirubin (conjugated) and indirect bilirubin (unconjugated). A high percentage of conjugated bilirubin (post-hepatic) indicates the presence of a post-hepatic lesion, such as bile duct obstruction or rupture. A large percentage of unconjugated bilirubin (pre-hepatic) on the other hand, indicates intravascular haemolysis. Both types of bilirubin are retained when paranchymal cells are damaged (Murdoch, 1976). In the study, we could not differentiate the types, however, the substantial elevation of serum total bilirubin confirmed the clinical impression of jaundice, and persistently elevated SGPT levels showed the presence of hepatic damage (Kelly et al., 1975). The main liver enzymes

(alanine aminotransferase and aspartate aminotransferase) are released into the bloodstream as a result of liver cell degeneration. Both enzymes are considerably elevated in any condition characterized by extensive hepatic necrosis, whereas lower increases occur in chronic liver disease (Murdoch, 1976). In the current study, both SGPT and SGOT levels were elevated in comparison to their normal levels, indicating that the liver was in an acute disease condition. Alkaline phosphatase is an enzyme that is generated in bone, liver, kidney, uterus, and gut. Although this enzyme can be raised in a plethora of feline disorders, higher levels are more likely to be associated with liver disease (Zawie & Garvey, 1984), which happened in the present study.

According to (Davydova & Kurochkin, 2021), a urinalysis will confirm the presence of hyperbilirubinemia by detecting elevated bilirubin levels in the urine sample. Furthermore, the urinalysis may reveal the location of red blood cell destruction as well as whether any kidney injury has occurred as a result of the red blood cell destruction. However, due to a lack of hospital facilities, urinalysis could not be presented in our study.

According to the study of (Sherding, 2000), Diagnostic imaging of the liver, particularly ultrasonography, is quite beneficial in jaundiced cats. Survey abdomen radiographs can assess liver size and reveal calcified choleliths, which may be the source of extra-hepatic biliary blockage. A study of (Chalmers & Matull, 2014) also stated that abdominal sonography is an important screening test for jaundiced patients. The presence of biliary ductal dilatation, gallstones, a hepatic mass lesion, or an enlarged or abnormally shaped pancreas necessitates additional study or therapy. Ultrasonography can also reveal abnormalities in adjoining organs and tissues such as the spleen, kidneys, gastrointestinal tract, and lymph nodes (Sherding, 2000). In the study, hepatomegaly, splenomegaly, and cystitis were observed using both x-ray and ultrasound examination, which helped to confirm the diagnosis.

Limitations of the Study

A liver biopsy is the best technique to determine the cause of jaundice, however, the owner refused to allow a post-mortem study of the patient's deceased body. Again, there was a shortage of laboratory diagnostic properties at the hospital, forbidding hematology and urinalysis from being done. All of these factors contributed to our inability to confirm the jaundice category and the etiology of this disease condition.

Conclusions

In a jaundice case, treatment must be administered based on the diagnosis. Therefore, early detection and prompt treatment are required to improve the patient's health. Apart from that, it will not help to ameliorate the situation, like in this case where the patient received late treatment that resulted in death. If an accurate diagnosis is not feasible, the patient's condition must be alleviated with symptomatic or basic treatment.

References

- Chalmers, J., & Matull, R. (2014). Jaundice. *Acute Medicine: A Symptom-Based Approach*, 259–267. <https://doi.org/10.1007/9781139600354.038>
- Chopra, S., & Griffin, P. H. (1985). Laboratory tests and diagnostic procedures in evaluation of liver disease. *The American Journal of Medicine*, 79(2), 221–230. [https://doi.org/10.1016/0002-9343\(85\)90013-0](https://doi.org/10.1016/0002-9343(85)90013-0)
- Davydova, A., & Kurochkin, M. (2021). *Article 2021* (Issue October).
- Kelly, D. F., Baggott, D. G., & Gaskell, C. J. (1975). Jaundice in the cat associated with inflammation of the biliary tract and pancreas. *Journal of Small Animal Practice*, 16(1–12), 163–172. <https://doi.org/10.1111/j.1748-5827.1975.tb05730.x>
- Lathe, G. H., & Ruthven, C. R. (1958). Factors affecting the rate of coupling of bilirubin and conjugated bilirubin in the van de Bergh reaction. *Journal of Clinical Pathology*, 11(2), 155–161. <https://doi.org/10.1136/jcp.11.2.155>
- Londoño, L., Schaer, M., & Saim, D. (2019). *Pathophysiology Evaluation of the Icteric Patient*. 55–59.
- Murdoch, D. B. (1976). Jaundice in the dog. *Journal of Small Animal Practice*, 17(2), 119–129. <https://doi.org/10.1111/j.1748-5827.1976.tb06581.x>
- Sherding, R. G. (2000). Feline Jaundice. *Journal of Feline Medicine and Surgery*, 2(3), 165–169. <https://doi.org/10.1053/jfms.2000.0088>
- Zawie, D. A., & Garvey, M. S. (1984). Feline hepatic disease. *The Veterinary Clinics of North America. Small Animal Practice*, 14(6), 1201–1230. [https://doi.org/10.1016/S0195-5616\(84\)50154-5](https://doi.org/10.1016/S0195-5616(84)50154-5)

Acknowledgement

The author desires to express her sincere gratitude to the ALMIGHTY for His unfathomable favoritism, without which she would not have been able to effectively complete the work.

The author would like to express her gratitude with a deep sense of reverence and tremendous graciousness to her internship supervisor, Dr. Mohammad Mejbah Uddin, Professor, Department of Anatomy and Histology, Faculty of Veterinary Medicine, Chattogram Veterinary and Animal Sciences University for her intellectual oversight, invaluable direction, and ongoing support during the time that molded the current work as its display.

The author would also like to sincerely thank and appreciate to Professor Dr. Gautam Buddha Das, honorable vice chancellor of Chattogram Veterinary and Animal Sciences University.

The author is honoring Professor Dr. Mohammad Alamgir Hossain, Dean of Faculty of Veterinary Medicine and Professor Dr. AKM Saifuddin, Director of External Affairs for offering this special internship program and research exposure.

At last, the author would also extend her appreciation to her family, friends, well-wishers specially Dr. Abdul Mannan, Deputy Chief Veterinary Officer, Teaching and Training Pet Hospital and Research Center, who provided full cooperation at the time of handling the patient to complete the work for this report.

Biography of the Author

I am, Nasrin Akter Tonny, DAUGHTER of Abdul Khaleque and Salina Akter. I have completed my Secondary School Certificate examination from CDA Agrabad Girl's School, Chattogram in 2014 followed by Higher Secondary Certificate examination from Hazi Mohammad Mohsin College, Chattogram in 2016. Now, I am an intern veterinarian under the Faculty of Veterinary Medicine in Chattogram Veterinary and Animal Sciences University, Bangladesh.

In the future, I expect to be a pet practitioner, and I have immense interest in working in the field of pet medicine.