

**Detection of Feline Panleukopenia by Antigen Test Kit at  
Teaching and Training Pet Hospital and Research  
Center in Purbachal, Dhaka**



**A clinical report submitted in partial satisfaction of the requirement for the  
Degree of Doctor of Veterinary Medicine (DVM)**

**By:**

**Shodipta Sharma Urmi**

**Roll No: 17/29**

**Reg No: 01855**

**Intern ID: 22**

**Session: 2016-17**

**Faculty of Veterinary Medicine  
Chattogram Veterinary and Animal Sciences University  
Khulshi, Chattogram – 4225, Bangladesh**

**Detection of Feline Panleukopenia by Antigen Test Kit at  
Teaching and Training Pet Hospital and Research  
Center in Purbachal, Dhaka**



**Approved By:**

---

**(Dr. AMAM Zonaed Siddiki**

**Professor**

**Department of Pathology and Parasitology)**

**Faculty of Veterinary Medicine**

**Chattogram Veterinary and Animal Sciences University**

**Khulshi, Chattogram – 4225, Bangladesh**

## Table of Contents

<b>Contents</b>	<b>Page No.</b>
<b>Abstract.....</b>	<b>iv</b>
<b>Introduction.....</b>	<b>01-03</b>
<b>Case Presentation.....</b>	<b>04-06</b>
<b>Result and Discussion.....</b>	<b>07-09</b>
<b>Conclusion.....</b>	<b>10</b>
<b>Limitation.....</b>	<b>11</b>
<b>References.....</b>	<b>12-15</b>
<b>Acknowledgement.....</b>	<b>16</b>
<b>Biography.....</b>	<b>17</b>

## List of Figures

<b>Figure</b>	<b>Title</b>	<b>Page No.</b>
Figure 1	FPV affected cat	05
Figure 2	Dehydration	05
Figure 3	Rapid Ag test kit	05
Figure 4	Ccollection of fecal swab	05
Figure 5	Before adding sample (Band is only in “C” zone)	06
Figure 6	1 minute after adding sample (Band is in both “C” & “T” zone)	06

## **Abstract**

Feline Panleukopenia, a highly fatal viral disease of domestic and wild felids, is caused by Feline Panleukopenia virus (FPV) that affects multiple system of the body. It is a single-stranded DNA virus that causes severe illness and death in young animals, specially puppies and kittens. The most prevalent mode of transmission for FPV is direct contact between susceptible animals and infected cats or their discharges. The FPV also remains infectious in the environment for months to years. The present study was performed to detect FPV through a commercial rapid Ag test kit. This procedure was carried out in Teaching and Training Pet Hospital and Research Center (TTPHRC), Purbachal, Dhaka on a six month aged non vaccinated cat from Bashundhara residential area which was showing symptoms of diarrhea, vomiting, fever and anorexia. The sensitivity of the rapid Ag test kit used was over 99% (according to manufacturer). Using of such kind of test kits are less time consuming and within a short time the results can be observed. The cat was treated with fluids, antibiotics, antiemetic, anti-secretory and amino acids along with multivitamins. FPL prevalence in pet cats is 7.5% in Bangladesh. The prevalence of FPL in Dhaka city is 7.50%. Very few published data are found in Bangladesh that use rapid Ag test kit for the diagnosis of FPL. A cross-sectional study over all the pet hospital is must need.

---

**Key Words:** Feline Panleukopenia, Antibiotics, Fluid therapy, Immunohistochemistry, Rapid Ag test kit

## **Introduction**

Feline panleukopenia (FPL), a highly contagious disease of domestic and exotic species of cats, is known to be induced with feline panleukopenia virus (FPV) in felines, especially in unvaccinated ones (Truyen et al., 2009). FPV is related to other viruses in the family Parvoviridae, specifically the genus Parvovirus (Ohshima & Mochizuki, 2009). This virus is commonly associated with infections in cats, tigers, and lions (Duarte et al., 2009). FPVs are single-stranded DNA viruses that cause severe illness and death in young animals, especially puppies and kittens (Truyen, 2006). The incubation period for FPV is only 5–9 days, but the disease spreads rapidly and has a high mortality rate among those who contact it. Within the first year of their lives, infection and exposure are both possible for all vulnerable cats. However, kittens who do not receive any vaccinations but gain immunity from their mothers through colostrum typically remain protected for the first three months of their lives (Mosallanejad et al., 2009). Basically, dehydration and massive secondary infections are common causes of death for exposed cats (Mirzakhani et al., 2016).

Actually, intestinal crypt epithelium and precursor blood cells in the bone marrow are considered as primary target cells for FPV in cats, older than 4 to 6 weeks (Greene & Addie, 2006). Viruses that enter the body via the oropharynx will travel to the lymphoid tissue and begin replication there. Following replication, the virion will spread throughout the body via the circulatory system. In mature animals, the most common sites of infection are the lymphoid tissues, bone marrow, and mucosal crypts of the digestive tract. Also susceptible to damage is the central nervous system, which includes the brain, the cerebellum, the retina, and the optic nerves. (Mosallanejad et al., 2009) Viruses will infect cells with the necessary receptors. Apoptosis will occur in partially infected cells (Greene, 2012).

In a contaminated environment, FPV is highly resistant to physical and chemical conditions and can remain infectious for weeks or months (Uttenthal et al., 1999). The most prevalent mode of transmission for FPV is direct contact between susceptible animals and infected cats or their discharges (Mosallanejad et al., 2009). During the active stages of the disease, it is shed from all body fluids, but most frequently retrieved from the colon and feces (Greene & Addie, 2006). The FPV also remains infectious in

the environment for months to years. FPV can be found in places such as cages, food bowls, and litter boxes, as well as in humans, with high mortality rates among kittens (3-5 month ages) and cats that are susceptible (those with other illnesses, not vaccinated, or living in high-risk environments) (Richards et al., 2006). After 18-24 hours of replication in oropharyngeal lymphoid tissues, FPV then spreads via viremia to the rest of the body over the next 2-7 days. To spread more easily, FPV targets quickly dividing cells like those lining in the intestinal crypts (Litster & Benjanirut, 2014). Viruses in feces, vomit fluid, urine, and saliva have the potential to contaminate the environment (Mahendra et al., 2020)

Disease can be peracute, resulting in sudden death from septic shock without any warning signs, particularly in kittens younger than two months. The most common presentation is an acute disease course over several days marked by high fever (104-106°F or 40-41°C), lethargy, anorexia, vomiting, diarrhea, and severe dehydration (Abd-Eldaim et al., 2009). Abdominal palpation may be painful and reveal enlarged mesenteric lymph nodes or thickened intestinal loops. Infected queens may abort (early pregnancy) or deliver kittens with central nervous system and ocular defects (late pregnancy), including cerebellar hypoplasia, hydrocephalus, retinal dysplasia, and optic nerve hypoplasia (Mirzakhani et al., 2016). Symptoms of parvovirus infection in queens could be subclinical to severe (Barrs, 2019). Villous atrophy, erosion of the surface epithelium, ectasia of capillaries in the remaining intact surface epithelium, crypt dilatation and necrosis, and lymphocyte infiltration in the lamina propria are histopathological characteristics of FPL. The macroscopic characteristics of FPL include significant dehydration and wasting, gastrointestinal tract dilatation, edema, and congestion, fibrinous exudate coating mucosal surfaces, and enlargement of mesenteric lymph nodes (Sheikh Omar et al., 1984).

Rapid detection of FPV infection is essential for isolating sick cats and preventing the spread of illness to susceptible animals. However, several laboratory approaches have been developed to identify FPV in infected cats, including polymerase chain reaction (Mirzakhani et al., 2016), hemagglutination (HA) (Goto et al., 1981), ELISA (Fiscus et al., 1985), immunofluorescence antibody test (Hofmann-Lehmann et al., 1996), virus isolation from blood or feces in cultures of CRFK or Mya 1 cells (Miyazawa et al.,

1999), and monoclonal antibodies (Fiscus et al., 1985), as clinical diagnosis is not definitive. Although these tests are more sensitive, specific, and reproducible, only specialized can do them (Mosallanejad et al., 2009). The immunochromatography (IC) assay (Addie et al., 1998), on the other hand, is the quickest field diagnostic method utilized in clinical practice since the test procedure is straightforward and can be conducted by both veterinarians and pet owners (Priambudi et al., 2022). Evaluation of the diagnostic kits (IC assay) (Addie et al., 1998) revealed an overall relative sensitivity of 95.8% and a specificity of 99.7% (Esfandiari & Klingeborn, 2000). In addition, 85.5% of 83 samples tested in Germany using both the one-step test and an immunological electron microscopy (IEM) agreed that the sensitivity and specificity were, respectively, 83.9 and 88.9% (Esfandiari & Klingeborn, 2000).

For preventative treatment of FPL-induced broad spectrum morbidities, intravenous fluid delivery is the first choice combined with antimicrobial therapy. Beside these anthelmintic, antiemetic, and gastro-protectants therapy can give a synergistic effect (Barrs, 2019). In the meanwhile, even after receiving treatment, there are reports of a high mortality rate including circulatory shock, septicemia, and disseminated intravascular coagulation (DIC) (Barrs, 2019) among infected felines and animals. Due to the ineffectiveness and lack of specificity of therapy options, diagnosis of FPV is essential for preventing infection in sensitive individuals. For accurate diagnosis, immunohistochemical staining for the viral antigen and/or ELISA assays as well as PCR methods are utilized (Abd-Eldaim et al., 2009).

FPL prevalence in pet cats is 7.5% in Bangladesh (Chisty et al., 2020). The prevalence of FPL in Dhaka city is 7.50% (Sultana et al., 2016). Although there is little data provided worldwide on the prevalence of FPV (Addie et al., 1998), there has been little published research on the prevalence of feline panleukopenia in Bangladesh (Islam et al., 2010). Among all of these, very few published data are found in Bangladesh that use rapid Ag test kit for the diagnosis of FPL. But nowadays the uses of rapid Ag test kit are increasing in the pet hospitals of Bangladesh.

## **Case Presentation**

On November 10, 2022, a six-month mixed brown and white hair colored; non-vaccinated male cat was brought from Bashundhara Residential Area. It was registered to the medicine unit of Teaching and Training Pet Hospital and Research Center (TTPHRC); an outreach campus of Chattogram Veterinary and Animal Sciences University (CVASU), in Purbachal, Dhaka. On duty veterinarians and the intern students observed its conditions with clinical signs of fever, vomiting, diarrhea and anorexia.

### ***Examination***

Rectal temperature of the cat was 103.7 °F and body weight (b.wt) was 3.4 kg. The cat looked weak, dehydrated and depressed with poor skin turgor. Then, a follow-up examination was performed of stool sample with a commercial rapid FPV Ag test kit (TESTSEALABS<sup>®</sup>; manufactured by Hangzhou Testsea, China; ISO certified with >99% accuracy). This is a rapid diagnostic test kit for FPV. It is packaged with a FPV Ag test cassette, a sample collecting swab, an assay diluent container and a dropper. To perform this test, a rectal swab was taken from the cat and inserted the swab into the assay diluents tube and mixed for 10 seconds. After waiting for 1 minute, 4 drops from the mixed sample were added into the sample hole “S” by using the dropper provided with the test kit, drop by drop. Before adding sample into the cassette the cassette contains colored band only in “C” line; that’s the control line. Within 1 minute the positive result (Presence of both “C” line and zone “T” line) appeared which indicated Feline panleukopenia positive.

### ***Therapy***

The cat was given Fluid therapy (Hartmann’s Solution 500 ml, ACME Laboratories Ltd; 20ml/kg b.wt), Ceftriaxone (Trizon IM 500 mg, ACME Laboratories Ltd; 25mg/kg b.wt), Ondansetron (Periset 8mg/4ml, ACME Laboratories Ltd; 0.2 mg/kg b.wt), Pantoprazole (Protocid 40mg/vial, ACME Laboratories Ltd; 0.8mg/kg b.wt), Metronidazole (Metro I/V 500 mg/100ml, Opso Saline Ltd; 10mg/kg b.wt), amino-acids (Aminovit Plus Vet 20 ml vial, Popular Pharmaceuticals Ltd.; 0.1 mg/kg b.wt).



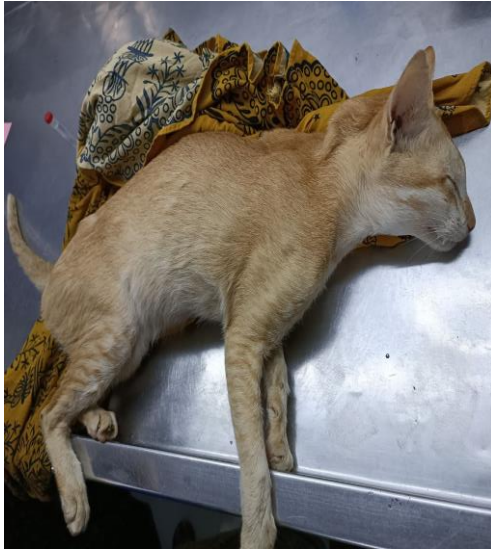

Fig 1: FPV affected cat

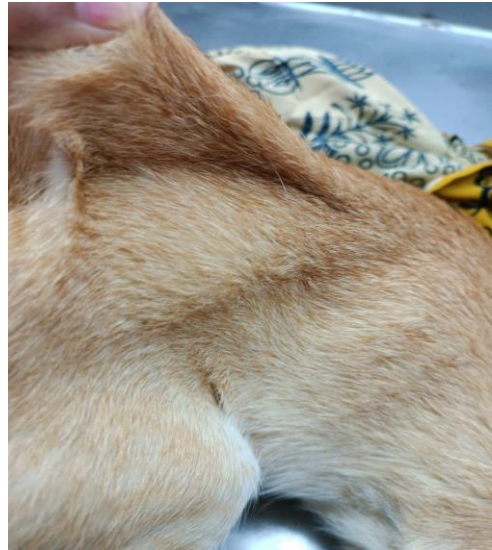

Fig 2: Dehydration

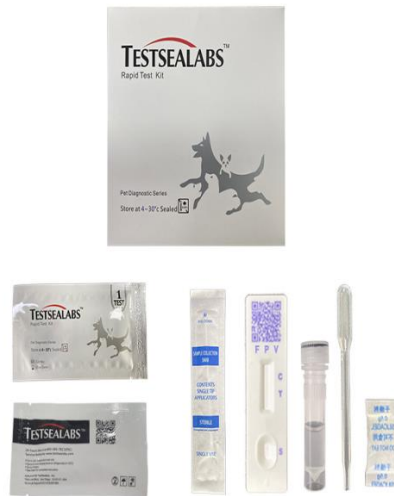

Fig 3: Rapid Ag test kit




Fig 4: Collection of fecal swab



Fig 5: Before adding sample  
(Band is only in “C” zone)

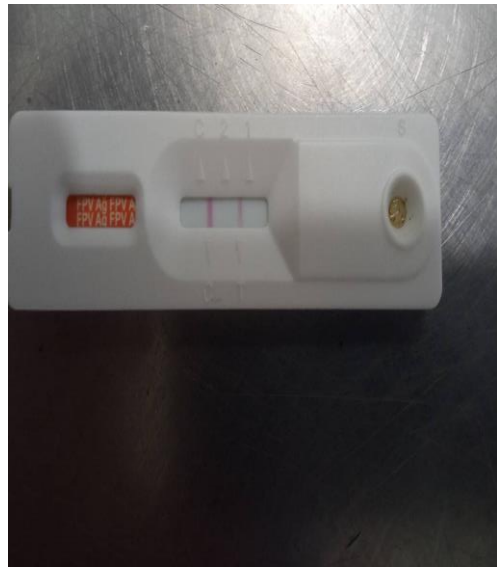


Fig 6: 1 minute after adding sample  
(Band is in both “C” & “T” zone)

## **Result and Discussion**

Among different diagnostic method of FPL, specificity of PCR was excellent (100%), whereas sensitivity was poor. In comparison with PCR, sensitivity for IC strip test was 47.6 % and specificity was 100%. Sensitivity for HA test was 38.1% and specificity was 100% (Raheena et al., 2017). RTPCR is highly specific tool and appeared its sensitivity in detecting true infected animal. It can be used for FPV detection even in low log of viraemia which cannot be detected by ELISA but it in comparison to ELISA is both costly and time consuming (Awad et al., 2018). Fig. 6 depicts the test results of feces sample FPV antigen kit test. This IC test can qualitatively detect the presence of FPV antigen in feces samples. The sensitivity and specificity of the diagnostic kit are 95.8% and 99.9%, respectively (Mosallanejad et al., 2009). Rapid detection of FPV antigen requires an IC test utilizing the lateral flow assay (LFA) technique. Typically, in LFA, the sandwich format is used to measure large substrates that contain multiple epitopes. The sample will pass through the conjugate pad, dissolving it. In this process, the antibody conjugate reacts with the antigen to form an antibody-antigen complex, which then travels along with the flow until it reaches the test line. The antibody-antigen complex will bind to the capturing antibody and color the test line. When the complex antibody-antigen is present in excess and is not bound to the antibodies in the test line, it will proceed to the control line. The antibody-antigen complex will bind to polyclonal antibodies in the control line region, causing a line to form on the control line (Sajid et al., 2015).

The treatment of individual animals infected with parvovirus is supportive and symptom-based. It is essential to treat dehydration with fluids (Dibartola & Bateman, 2006). In severe circumstances, blood transfusions may be required. Antibiotics are recommended for preventing secondary bacterial infections of the intestinal tract (Mosallanejad et al., 2009). Antiemetic for the treatment of severe vomiting and corticosteroids for the treatment of endotoxic shock may be required and can be administered symptomatically. In severe cases, it may be necessary to restrict oral intake of food and water.

The most important part for treating a FPL patient is fluid therapy (Mosallanejad et al., 2009). As in this condition hypovolemia and loss of electrolytes occur, the patient

become so much weak. The registered cat was prescribed with Hartmann's solution (Na<sup>+</sup>: 131 mEq, K<sup>+</sup>: 5mEq, Ca<sup>2+</sup>: 4mEq, Cl<sup>-</sup>: 111mEq, HCO<sub>3</sub><sup>-</sup>, lactate: 29mEq/liter of the solution) (Barrs, 2019) in intravenous (IV) route at a dose of 20ml/kg b.wt for 7 days. This would boost up the electrolyte level. 5% DNS and Ringers Lactate solution was used as fluid therapy in some other studies (Mosallanejad et al., 2009).

Ceftriaxone is a third-generation antibiotic belonging to the cephalosporin class. It belongs to the  $\beta$ -lactam class of antibiotics. Ceftriaxone inhibits bacterial cell wall synthesis in a selective and irreversible manner by binding to trans-peptidases, which are penicillin-binding proteins (PBPs). These catalyze the cross-linking of the peptidoglycan polymers composing the bacterial cell wall. The peptidoglycan cross-linking activity of PBPs is a construction and repair mechanism that normally helps to maintain the integrity of the bacterial cell wall. Therefore, inhibiting PBPs results in damage and destruction of the cell wall, and ultimately cell lysis occurs (Blumer, 1991). Ceftriaxone at a dose of 25mg/kg b.wt in intra-muscular (IM) route once daily for 7 days (Truyen et al., 2009) was administered for the reported cat. Using of Marbofloxacin; a third-generation fluoroquinolone antibiotic (Patel et al. 2018) was beneficial for responding to treatment to FPL in Malang (Priambudi et al., 2022). Metronidazole belongs to the class of nitroimidazoles. It inhibits the synthesis of nucleic acid by producing nitroso radicals, which disrupt the DNA of microbial cells (Sigeti et al., 1983). At a dose of 10mg/kg b.wt the registered cat was treated with Metronidazole in intravenous route twice daily for 7 days (Truyen et al., 2009).

Ondansetron is categorized as a member of the group of drugs known as serotonin 5-HT<sub>3</sub> receptor antagonists. It accomplishes this by inhibiting the function of serotonin, a naturally occurring chemical that is associated with feelings of sickness and vomiting (Tyers & Freeman, 1992). For controlling vomiting Ondansetron in a dose of 0.2 mg/kg b.wt was administered in IM route twice daily for 7 days (Barrs, 2019).

Pantoprazole inhibits the production of gastric acid by binding covalently to the H<sup>+</sup>/K<sup>+</sup> ATP pump in the gastric parietal cell of the stomach (Poole, 2001). This reduces the amount of acid that is secreted normally. Because of the covalent interaction, acid secretion is inhibited for at least 24 hours and likely for much longer. Pantoprazole has

a synergistic effect with other drugs used here. For this, maintaining a dose of 0.8mg/kg b.wt it was administered in IV route twice daily for 7 days (Mosallanejad et al., 2009).

The vitamin B complex plays an important part in the body by acting as a cofactor in a number of different enzymatic activities, which in turn stimulates an increase in the rate at which the body burns calories (Triana, 2006). The vitamin along with some electrolytes and minerals were given in the affected cat at 0.1mg/kg b.wt in IV route for 7 days. In other study the use of multivitamin was ensured (Rice, 2017). This drug is used as a supplement to improve the protein loss of the animal (Barrs, 2019).

The majority (75%) of parvovirus infections generally respond to the symptomatic treatment (Lamm & Rezabek, 2008). Vaccination is a preventative measure against feline panleukopenia in addition to maintaining a clean environment and avoiding direct contact between sick and healthy cats. Vaccination programs can be initiated when kittens are between 6 and 8 weeks old (Jakel et al., 2012). Vaccinated cats had a lower prevalence of FPV than non-vaccinated (Chisty et al., 2020).

## **Limitation**

The follow up treatment of the FPV infected cat, couldn't have been conducted as the patient owner didn't provide any contact number. So the recovery time was unknown. The commercial rapid Ag test kits sometimes may give false positive or false negative results.

## **Conclusion**

A FPV affected cat showing typical sign symptoms (Fever, diarrhoea, vomiting, anorexia) was registered into TTPHRC. It was examined with a rapid Ag test kit, that acts in IC assay method. The overall test procedure was completed within just 5 minutes. As the number of pets are increasing day by day in Bangladesh, the pet hospitals should introduce more rapid diagnostic test procedures. As a result, time will be saved for the diagnosis. So rapid AG test kit for FPV can be a choice for the veterinarians to diagnose FPL easily in the cats.

## References

- Abd-Eldaim M., Beall M.J., Kennedy M.A. 2009. Detection of feline panleukopenia virus using a commercial ELISA for canine parvovirus, *Vet. Ther.*, 10: 1-6.
- Addie D., Toth S., Thompson H., Greenwood N., Jarrett J. 1998. Detection of feline parvovirus in dying pedigree kittens, *Vet. Rec.*, 142: 353-356.
- Awad R.A., Khalil W.K., Attallah A.G. 2018. Feline panleukopenia viral infection in cats: Application of some molecular methods used for its diagnosis, *J. Genet. Eng. Biotechnol.*, 16: 491-497.
- Barrs V.R. 2019. Feline panleukopenia: a re-emergent disease, *Vet. Clin. North Am. Small Anim.*, 49: 651-670.
- Blumer J. 1991. Pharmacokinetics of ceftriaxone, *Hosp. Pract.*, 26: 7-13.
- Chisty N.N., Belgrad J.P., Al Sattar A., Akter S., Hoque M.A. 2020. Clinico-epidemiological investigation of feline panleukopenia and parvoviral enteritis in the two largest pet hospitals in Bangladesh, *J. Adv. Vet. Anim. Res.*, 7: 726.
- Dibartola S.P., Bateman S. 2006. Introduction to fluid therapy, *Flu. Ther. Small Anim. Prac.*, 2: 265-280.
- Duarte M.D., Barros S.C., Henriques M., Fernandes T.L., Bernardino R., Monteiro M., Fevereiro M. 2009. Fatal infection with feline panleukopenia virus in two captive wild carnivores (*Panthera tigris* and *Panthera leo*), *J. Zoo Wildl. Med.*, 40: 354-359.
- Esfandiari J., Klingeborn B. 2000. A comparative study of a new rapid and one-step test for the detection of parvovirus in faeces from dogs, cats and mink, *J. Vet. Med.*, 47: 145-153.
- Fiscus S., Mildbrand M., Gordon J., Teramoto Y., Winston S. 1985. Rapid enzyme-linked immunosorbent assay for detecting antibodies to canine parvovirus, *Am. J. Vet. Res.*, 46: 859-863.
- Goto H., Horimoto M., Shimizu K., Hiraga T., Matsuoka T., Nakano T., Morohoshi Y., Maejima K., Urano T. 1981. Prevalence of Feline Viral Antibodies in Random-source Laboratory Cats, *Exp. Anim.*, 30: 283-290.
- Greene C.E. 2012. Feline enteric viral infections, *Infectious diseases of the dog and cat*, 80-91.



- Greene C.E., Addie D.D. 2006. Feline parvovirus infections, *Infect. Dis. Dog. Cat.*, 78: 88.
- Hofmann-Lehmann R., Fehr D., Grob M., Elgizoli M., Packer C., Martenson J.S., O'Brien S.J., Lutz H. 1996. Prevalence of antibodies to feline parvovirus, calicivirus, herpesvirus, coronavirus, and immunodeficiency virus and of feline leukemia virus antigen and the interrelationship of these viral infections in free-ranging lions in east Africa, *Clin. Diagn. Lab. Immunol.*, 3: 554-562.
- Islam M.A., Rahman M.S., Rony S.A., Uddin M.J., Rahman A. 2010. Antigenic detection of feline panleukopenia virus in local breed cats at Tangail district in Bangladesh, *Int. J. Biores.*, 2: 25-28.
- Jakel V., Cussler K., Hanschmann K.M., Truyen U., König M., Kamphuis E., Duchow K. 2012. Vaccination against feline panleukopenia: implications from a field study in kittens, *BMC Vet. Res.*, 8: 1-8.
- Lamm C.G., Rezabek G.B. 2008. Parvovirus infection in domestic companion animals, *Vet. Clin. North Am. Small Anim. Pract.*, 38: 837-850.
- Litster A., Benjanirut C. 2014. Case series of feline panleukopenia virus in an animal shelter, *J. Feline Med. Surg.*, 16: 346-353.
- Mahendra Y.N., Yuliani M.G.A., Widodo A., Diyantoro D., Sofyan M.S. 2020. A case study of feline panleukopenia in cats at the educational animal hospital of Universitas Airlangga, *J. App.Vet. Sci. Technol.*, 1: 6-10.
- Mirzakhani N., Tehrani A.-A., Yousefi A., Morvaridi A., Kian M. 2016. A case of feline panleukopenia in *Felis silvestris* in Iran; confirmed by PCR, *Comp. Clin. Pathol.*, 25: 1317-1320.
- Miyazawa T., Ikeda Y., Nakamura K., Naito R., Mochizuki M., Tohya Y., Vu D., Mikami T., Takahashi E. 1999. Isolation of feline parvovirus from peripheral blood mononuclear cells of cats in northern Vietnam, *Microbiol. Immunol.*, 43: 609-612.
- Mosallanejad B., Avizeh R., Ghorbanpoor Najafabadi M. 2009. Antigenic detection of Feline Panleukopenia virus (FPV) in diarrhoeic companion cats in Ahvaz area, Iran. *J. Vet. Res.*, 10: 289-293.

- Ohshima T., Mochizuki M. 2009. Evidence for recombination between feline panleukopenia virus and canine parvovirus type 2, *J. Vet. Med. Sci.*, 71: 403-408.
- Poole P. 2001. Pantoprazole, *Am. J. Health-Syst. Pharm.*, 58: 999-1008.
- Priambudi M., Haskito A.E.P., Inayah K., Adrenalin S.L. 2022. Detection of feline panleukopenia with antigen test kit, *ARSHI Vet. Lett.*, 6: 3-4.
- Raheena K.P., Priya P., Mani B.K., Mini M., Pillai U.N. 2017. Comparison of different diagnostic test to detect feline panleukopenia virus among cats in Kerala, India, *Indian J. Anim. Res.*, 51: 347-349.
- Rice J. 2017. Successful Treatment of Feline Panleukopenia: A Guideline For Rescuers and Veterinarians, Part I, *J. vet. sci. med. diagn.*, 6: 1-5
- Richards J.R., Elston T.H., Ford R.B., Gaskell R.M., Hartmann K., Hurley K.F., Lappin M.R., Levy J.K., Rodan I., Scherk M. 2006. The 2006 American association of feline practitioners feline vaccine advisory panel report, *J. Am. Vet. Med. Assoc.*, 229: 1405-1441.
- Sajid M., Kawde A.-N., Daud M. 2015. Designs, formats and applications of lateral flow assay: A literature review, *J. Saudi Chem. Soc.*, 19: 689-705.
- Sheikh Omar A., Awang I., Latiffibrahim A., Cheng B. 1984. case of feline panleukopenia in Malaysia confirmed by electron microscopy, *Pertanika*,
- Sigeti J.S., Guiney Jr D.G., Davis C.E. 1983. Mechanism of action of metronidazole on *Bacteroides fragilis*, *J. Infect. Dis.*, 148: 1083-1089.
- Sultana R.N., Uddin A.S., Asmaul H., Yesmin R.N., Sabina Y., ATM B., Sadikul I.M., Monira N., Jahengir A.K. 2016. Prevalence of diseases in pet animals at Dhaka city of Bangladesh, *Ann. Vet. Anim. Sci.*, 3: 1-5.
- Triana V. 2006. Macam-macam vitamin dan fungsinya Dalam tubuh manusia, *An. J. Pub. Health.*, 1: 40-47.
- Truyen U. 2006. Evolution of canine parvovirus—a need for new vaccines?, *Vet. Microbiol.*, 117: 9-13.
- Truyen U., Addie D., Belák S., Boucraut-Baralon C., Egberink H., Frymus T., Gruffydd-Jones T., Hartmann K., Hosie M.J., Lloret A. 2009. Feline panleukopenia. ABCD guidelines on prevention and management, *J. Feline Med. Surg.*, 11: 538-546.

Tyers M., Freeman A. 1992. Mechanism of the anti-emetic activity of 5-HT<sub>3</sub> receptor antagonists, *J. Oncol.*, 49: 263-268.

Uttenthal A., Lund E., Hansen M. 1999. Mink enteritis parvovirus: Stability of virus kept under outdoor conditions, *APMIS*, 107: 353-358.

## **Acknowledgement**

All the praises are due to the Almighty God, whose blessings have been enabled the author to accomplish this work.

The author expresses her wholehearted sense of gratification, a sincere appreciation to her respected teacher and supervisor Dr. AMAM Zonaed Siddiki, Professor, Department of Pathology and Parasitology, Faculty of Veterinary Medicine, Chattogram Veterinary and Animal Sciences University, whose ingenuous and scholastic advice, judicious recommendations, constructive criticism, continuous encouragement and untiring assistance have guided the author from the beginning of inception of intern studies until to the completion of this report.

The author would like to express her sincere gratitude and gratefulness to Dr. Abdul Mannan, Deputy Chief Veterinary Officer and Director, In-Charge, Teaching and Training Pet Hospital and Research Center (TTPHRC), DR. Mizanur Rahman, Assistant Professor, TTPHRC, DR. Mohammad Bayazid Bostami, Assistant Professor, TTPHRC, DR. Aparna Datta, Assistant Professor TTPHRC, and the staffs of TTPHRC, Chattogram Veterinary and Animal Sciences University.

## **Biograpgy**

I am Shodipta Sharma Urmi, daughter of Dilip Kumar Sharma and Kalpona Rani Sharma. I am from Pekua, Cox'sbazar. I passed Secondary School Certificate examination (S.S.C.) in 2014 (G.P.A.-5.00) from Pekua Govt. Model G.M.C Institution and Higher Secondary Certificate examination (H.S.C.) in 2016 (G.P.A-4.83) from Chattogram Cantonment Public College. I am a student of 22<sup>nd</sup> batch and now an intern student under the Faculty of Veterinary Medicine in Chattogram Veterinary and Animal Sciences University. In the future I would like to work in the field of Genetics.