

A Case Report on Navel Ill and It's Management in Calf



A Clinical Report

Submitted by

MD. Shamim Reza

Roll no: 17/13

Reg no: 01832

Intern id: 10

Session: 2016-17

A clinical report is submitted for the partial fulfillment of the Degree of Doctor of Veterinary Medicine (DVM)

Chattogram Veterinary and Animal Sciences University
Khulshi, Chattogram-4225.

A Case Report on Navel Ill and It's Management in Calf



A Clinical Report

Submitted by

MD. Shamim Reza

Roll no: 17/13

Reg no: 01832

Intern id: 10

Session: 2016-17

Approved as to style & content by

Signature of student

Signature of supervisor

Prof. Dr. Bibek Chandra Sutradhar

Department of Medicine & Surgery

Chattagram Veterinary & Animal Sciences University

TABLE OF CONTENTS

| Contents | Page no. |
|-------------------------------------|-----------------|
| List of Figures | 4 |
| Abstract | 5 |
| Introduction | 6 |
| Case history and observation | 8 |
| Preoperative procedure | 8 |
| Surgical procedure | 9 |
| Postoperative care | 10 |
| Result and discussion | 11 |
| Conclusion | 13 |
| References | 14 |
| Acknowledgment | 17 |

List of Figures

| Title | Page no |
|---|----------------|
| a. Swelled navel region | 8 |
| b. Temperature Checking | 8 |
| c. Pus accumulation on the navel area | 8 |
| d. Dressing | 8 |
| e. Fluid therapy | 8 |
| f. Local anesthesia | 8 |
| g. Incision on umbilical region | 9 |
| h. Mass tissue identification | 9 |
| i. Separation | 9 |
| j. Pressing | 9 |
| k. Pulling out | 9 |
| l. Suturing and additional drainage tube | 9 |
| m. Navel area after removing of mass tissue and suturing | 9 |

Abstract

A calf of Holstein Friesian breed was brought to SAQ Teaching Veterinary Hospital, CVASU, Chattogram, which was 13 days old with 28 kg b.wt. The complaint of the owner was swollen navel region with hardening and pus coming out from it. The calf was alert, and the appetite was normal at the time of presentation. On physical examination, the temperature was 104 °F (slight pyrexia), pulse and respiratory rates were within the normal range. There was a foul odor present in the navel opening. Based on the history and findings, the calf was diagnosed as navel ill which was corrected surgically. The incision on the umbilical region to successfully remove mass tissue, pus, and debris and added suturing with catheterization for pus and fluid removal and cleaned by povidone-iodine. During suturing, a catheter was set to avoid fluid and pus accumulation later. Marbofloxacin @ 2mg/kg b. wt. for 10 days, ketoprofen @ 3mg/kg b. wt. for 3 days, Pheniramine maleate @ 1mg/kg b. wt. for 7 days was used for post-operative care and all these were given on the intramuscular route. There was also used the povidone-iodine ointment on the operated area topically. The catheter was removed after 3 days and the site was healing gradually. It was completely healed after 14 days with proper care and management.

Keywords: Navel ill, Mass tissue, marbofloxacin, Ketoprofen, Viodin, drainage tube.

INTRODUCTION

An infection-related inflammation of the umbilicus and its surrounding structures is known as navel illness. It appears to be more prevalent in calves delivered in filthy conditions and is frequently seen in newborn farm animals (Radostits et al., 2007; Naik et al., 2011). The umbilical cord serves as a link between the mother and the fetus. The amniotic membrane, paired external umbilical veins, paired external umbilical arteries, and the urachus makes up the umbilicus and its accompanying anatomical components. Navel illness is a disorder that prevents the umbilical cord from supplying the fetus with the nutrients that normally develop while inside the womb. Omphalophlebitis, omphaloarteritis, and urachitis are terms used to describe the further infection from the external umbilicus to the intra-abdominal segments of the umbilical vein, umbilical arteries, and urachus respectively (Kasari, 1993). At birth, the amniotic membrane of the umbilical cord tear apart, and the umbilical vein and urachus gradually close (Anderson, 2004). When the umbilical arteries' smooth muscles contract, the arteries are forced to retract all the way to the top of the bladder (Radostits et al., 2007). After parturition, the umbilical cord typically dries out within a week, typically within 1 to 8 days (Hides and Hannah, 2005). Swellings of the umbilical stalk, with or without herniation, are common conditions in calves (Rings, 1995). It is usually a mixed infection of *Escherichia coli*, *Proteus*, *Staphylococcus*, *Corynebacterium*, *Pyogenes*, and *enterococcus* (Reef, 1987) The infection may present as any of the clinical entities of omphalitis, omphalophlebitis, omphaloarteritis, or infection of the urachus, or as a mix of these conditions. Most of the time, it manifests as a mixed bacterial infection, with probable localization of infection in the bones, meninges, eyes, endocardium, and end arteries of the feet, ears, and tail (Naik et al., 2011). The umbilicus is typically enlarged with pus, toxemia, and thriftiness (Radostits et al., 2007). Reduced growth, joint disease, and other consequences may result from this disorder if it is not treated (Mee, 2008b). The prevalence of navel ill in newborn calves is 5 to 15% (Mee, 2008). In newborn calves without maternal immunity during the fetal period, it has been discovered that navel infections may operate as sources of infection, leading to septicemia (Naik et al., 2011). Most factors that contribute to the development of this illness are inadequate and delayed intake of high-quality colostrum, the prolonged residence of a newborn calf in an unsanitary maternity pen, and immediate navel antisepsis upon delivery (Mee, 2008b; Waltner-Toews et al., 1986). Limited research has been done on navel ill in calf

and its management. Therefore, the main objective of this research is naval ill diagnosis of calf, aseptically surgical correction, and proper post operative care.

CASE HISTORY AND OBSERVATION

A 13-day-old female calf was admitted to SAQ Teaching veterinary hospital, CVASU, Chattogram, Bangladesh. The weight of the animal was 28 kg. The owner complained that the calf suffered from swelling in the naval area for 1 day. As a clinical sign, there was seen heat and pain with swelling in the naval area. There was an abscess with pus coming out from it. The body temperature was 104°F.

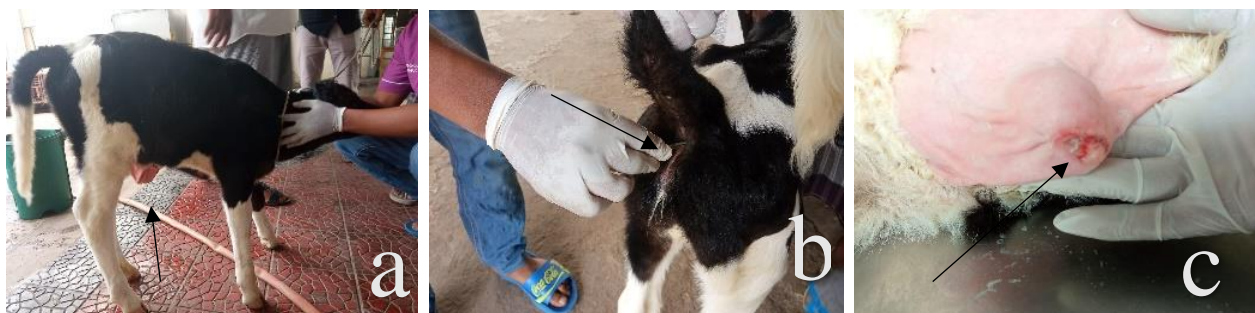

Fig: Case History and Diagnosis (a,b & c) where, a = swelled naval region, b = temperature checking and c = pus accumulation on the naval area.

PREOPERATIVE PROCEDURE

The patient was prepared aseptically and secured in a dorso-ventral position. Local anesthesia (ring block) was performed with 2% lidocaine @ 6mg/kg body weight (8.4 ml).

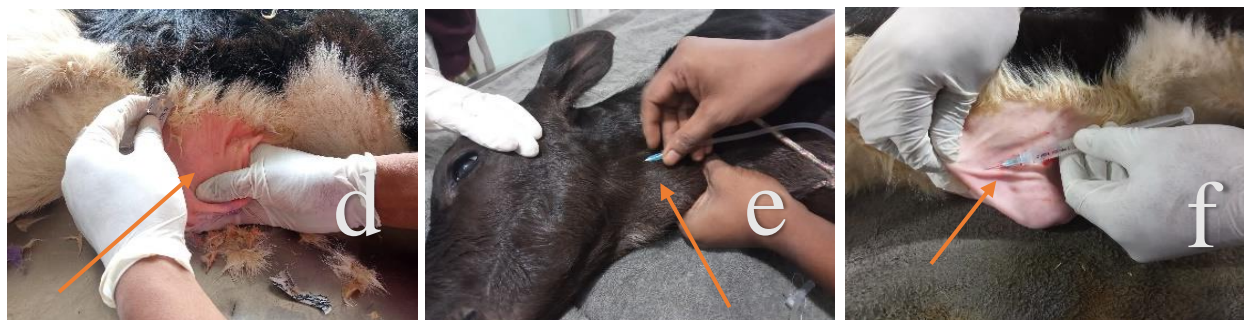

Fig: Preoperative procedure (d-f); where, d = dressing, e = fluid therapy, f = local anesthesia (ring block).

SURGICAL PROCEDURE

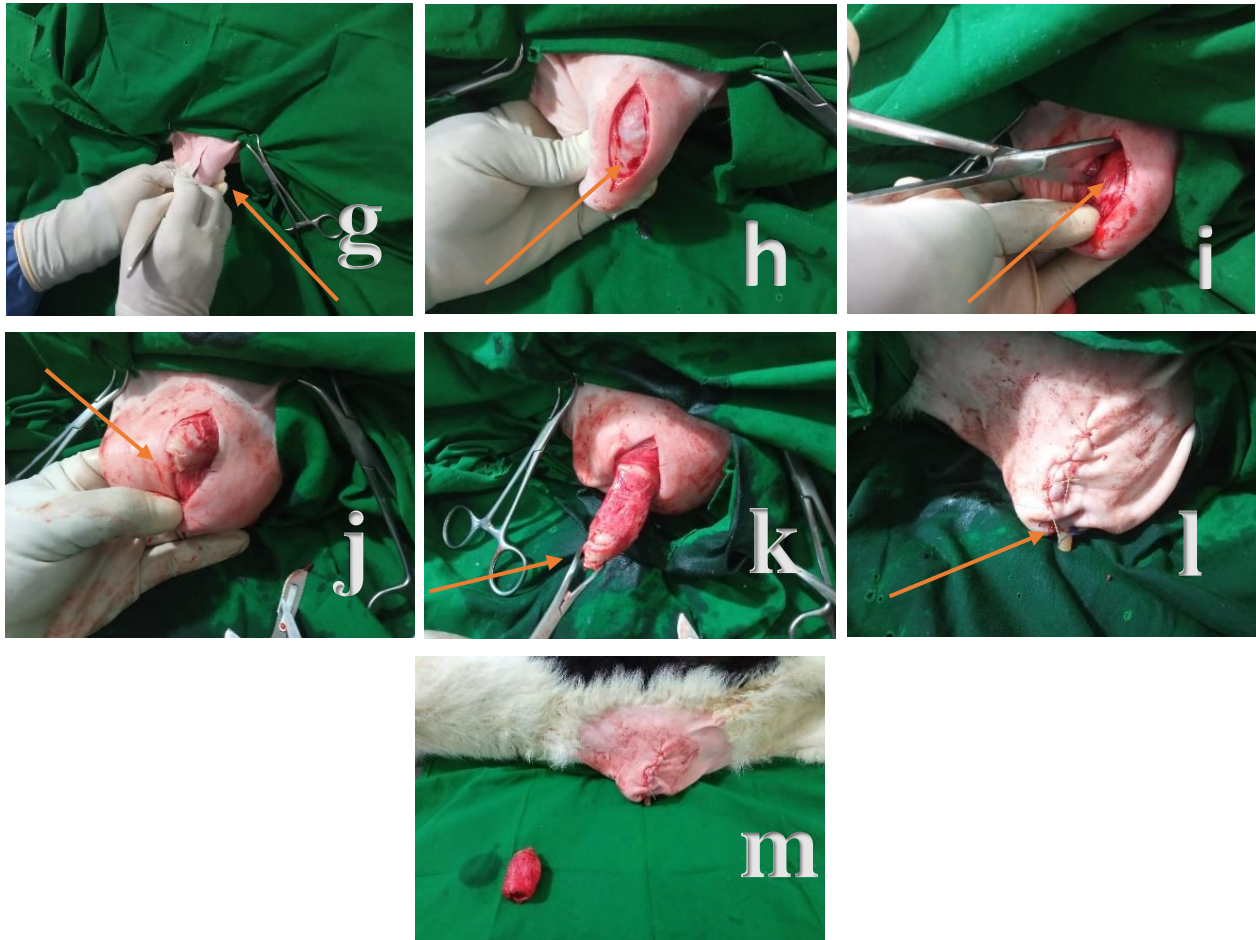


Fig: Surgical procedure (g-m); where, g = incision on umbilical region, h-k = mass tissue identification, separation, pressing and pulling out mass tissue, l = suturing and additional drainage tube for pus and fluid removal and m = naval area after removing of mass tissue and suturing.

POST-OPERATIVE CARE

As post-operative care, the calf was suggested with marbofloxacin (Marbovet; Eskayef pharmaceuticals Ltd.) @ 2mg/kg b. wt. intramuscularly for antimicrobial coverage every 24 hours for 10 days. Ketoprofen (Kopvet; Square pharmaceuticals Ltd.) @ 3mg/ kg b. wt. intramuscularly for inflammation & pain management every 24 hours for 3 days. Pheniramine maleate (Histavet; ACI Ltd.) @ 1 mg/kg b. wt. intramuscularly for hypersensitivity every 24 hours for 7 days. Povidone iodine (viodin 5% ointment; Square pharmaceuticals Ltd.) on the affected area every 8 hours for 14 days. Normal feeding was kept regular. The drainage tube was removed after 3 days and the suture was removed after 14 days of surgery.

RESULTS & DISCUSSION

Navel ill (Omphalitis) is a bacterial infection via the umbilicus (navel) which is much higher when calves (less than 1 week) are born in a dirty calving environment (Blowey & weaver, 2011). It is mostly found in cattle calves, buffalo calves, foals, lambs, kids and piglets and others (Chakrabarti, 2003). Though the observed calf was 13 days old, generally calves less than one week of age are the most affected by infections of the navel because the umbilical stump usually takes 7-10 days to dry up. (Abbas et. al. 2021). Poor navel hygiene, an umbilical cord that breaks off or is cut too close to the body wall, and unfavorable environmental circumstances, such as giving birth in an unclean calving area or having the umbilical stump sucked on by other calves, are all risk factors for developing navel infection in calves (Smith, 2003). According to Anderson and Rings (2008), actinomyces pyogenes is responsible for most umbilical infections & Escherichia coli is the second most often isolated bacterium and is thought to be the most likely to cause systemic infection and septic polyarthritis. Bacterial toxins cause the calf to go into shock, suffer from circulation issues, and die because of multiple organ failures (Jubb et. al., 1993). Navel cord care kept the calves safe from omphalitis, but in untreated calves whose navel dipping was not done properly, 50% of calves showed the symptoms of navel ill and 25% died due to septicemia (Bilal, 2008). The most affected structure was urachus most reliably diagnosed by ultrasonography, but intra-abdominal adhesions were found at surgery in 47% of animals with umbilical abnormalities (Bisset al. 1994). The symptoms of navel disease include swellings of the umbilical stalk, septicemia, and possibly hematogenous septic polyarthritis (Anderson and Rings, 2008). Animals that are affected typically exhibit pyrexia and a painful, enlarged navel that is oozing pus that smells bad (Blowey and Weaver, 2011). But in this case, no polyarthritis & most peculiarly, mass tissue was found. In surgical procedures, there was used diazepam as a sedative and lidocaine as an anesthetic but in Boscarato et al. (2021), sedation was done with Xylazine Chloridrate, and anesthetic induction with ketamine and midazolam and maintenance was performed by means of inhalation anesthesia with 1.5% isoflurane. After removing of mass tissue, the organ was closed by stumping suture by prolene 1-0, subcutaneous with subcuticular suture vicryl 2-0. Finally, the skin was closed with cross mattress by nylon 1. According to Naik et al. (2011), surgical abscess drainage and debridement of necrotic tissues combined with the antibiotic Streptopenicillin are treatments for navel diseases, but the treatment was done by Marbofloxacin as the present case.

Naik et al. (2011) also used Meloxicam as a pain killer, routine dressing of wounds with a Hydrogen peroxide solution, Gamma benzene hexachloride, proflavine hemisulphate and fly repellent for myiasis where this case was treated by Ketoprofen as a pain killer, Pheniramine maleate for hypersensitivity & 5% povidone-iodine ointment. Fly repellent wasn't used as myiasis was absent. The use of a drainage tube was also done in the present case for 3 days if pus accumulates after surgery. It is also important to apply some disinfectant like 2% iodine or chlorhexidine solution to the umbilical stump just after parturition (Smith, 2003). Early treatment with antibiotics and supportive care may allow the resolution of infection before the development of abscesses and distention of the urachus or the umbilical arteries and veins (Turner et al., 1982). Strict hygienic maintenance of a living environment and adequate colostrum ingestion is necessary to prevent this disease (Kashyap et. al., 2018).

The sample size was small in this study which might not show the proper result. Hospital facilities was not that much for better diagnosis of the case and hematology could be done but for short time period it couldn't be done and for lack of accommodation and nursing facilities patient had to be released after surgery. Postoperative care was advised to the farmer though for long distance couldn't visit patient regular and owner was not aware to take the patient hospital for checkup.

CONCLUSION

After removal of the mass from umbilicus by surgical method successfully, the area was observed and taken care of so that no flies could sit and no further infection occur. The owner was advised to maintain hygiene properly. The calf completely recovered after 2 weeks without further complications.

REFERENCES

- Abbas, S., Ahmeda, S. S., Khana, M. S., Ahmeda, N., & Sanab, H. M. (2021). Field study on the occurrence of Navel ill in cow calves. Journal homepage: [http://ejmvs the. ijesir.org/](http://ejmvs.the.ijesir.org/) Paper id: 010001EJMVS.
- Anderson, D. E. (2004). Surgical diseases of the neonate. *Medecin Veterinaire Du Quebec*, 34, 12-12.
- Anderson, D. E., & Rings, M. (2008). *Current veterinary therapy: food animal practice*. Elsevier Health Sciences.
- Bilal, Q. M., 2008. Dissemination of Technologies for Profitable Dairying at Farmer's Level. Location Tehsil Toba Tek Singh.
- Biss, M. E., Hathaway, S. C., and Johnstone, A. C., 1994. Evaluation of the risk of potential bacteremia in carcasses from very young slaughter calves with localized navel ill. *Br. Vet. J.* 150, (4):377-84.
- Blowey, R., & Weaver, A. D. (2011). *Color Atlas of diseases and disorders of cattle e-book*. Elsevier Health Sciences
- Boscarato, A. G., Martins, W. D. C., Pacheco, F. C., Belettini, S. T., Quessada, A. M., & Alberton, L. R. (2021). Surgical Approach in Calves with Omphalitis. *Acta Scientiae Veterinariae*, 49.
- Larson, E. (2012). Bladder, Urachus, and Umbilicus Problems in Neonatal Foals. Recuperado de <https://thehorse.com/117256/bladder-urachus-and-umbilicus-problems-in-neonatal-foals>.
- Faez, F., Muhammad, A. S., Konto, M., Abdulnasir, T., Abba, Y., Chung, L., ... & Abdul, A. S. (2015). A clinical case of navel and joint ill in a calf-medical management. *International Journal of Livestock Research*, 5(5), 103-108.

- Hides, S., and Hannah, M. (2005). Drying times of umbilical cords of dairy calves. *Australian veterinary journal* 83, 371-373.
- Jubb KVF, Kennedy PC and Palmer N (1993). *Pathology of Domestic Animals*. 4th ed. Academic Press, USA.
- Kasara, R. T., 1993. Omphalitis and its sequelae in ruminants. In Howard, J.L. (ed.), *Current Veterinary Therapy, Food Animal Practice*. 3rd ed. Philadelphia: W.B Saunders.
- Kashyap, G., Dar, J. A., War, Z. A., Gupta, D., Sahu, N., Singh, S., ... & Rai, S. K. (2018). Bacteriological and Pathological Study of a Case of Navel Ill and Its Complications.
- Lorenz, I., Mee, J. F., Earley, B., and More, S. J. (2011). Calf health from birth to weaning. I. General aspects of disease prevention. *Ir Vet J* 64, 10.1186.
- Mee, J. (2008a). Prevalence and risk factors for dystocia in dairy cattle: A review. *The Veterinary Journal* 176, 93-101.
- Mee, J. (2009). Bovine perinatology: Current understanding and future developments. *Animal Reproduction: New Research Developments*, 67-106.
- Mee, J. F. (2008b). Newborn dairy calf management. *Veterinary Clinics of North America: Food Animal Practice* 24, 1-17
- Naik, G., Ananda, K., Kavitha Rani, B., Kotresh, A., Shambulingappa, B., and Patel, S. (2011). Navel ill in newborn calves and its successful treatment. *Veterinary World* 4, 326-327.
- Radostits, O. M., Gay, C., Hinchcliff, K. W., and Constable, P. D. (2007). A textbook of the diseases of cattle, horses, sheep, pigs and goats. *Veterinary Medicine* 10, 2045-2050
- Reef, V., 1987. Abnormalities of neonatal umbilicus detected by ultrasound *Equine Practice*. 32, 157.
- Rings, D. M. (1995). Umbilical hernias, umbilical abscesses, and urachal fistulas. Surgical considerations. *The Veterinary Clinics of North America. Food Animal Practice*, 11(1), 137-148.

Smith Thomas, H.2003. Navel Ill, Angus Beef Bulletin, Calfology, Inc.109-110.

Turner TA, Fessler JF, Ewert KM. 1982. Patent urachus in foals. Equine Practice, 4, 24, 31.

Waltner-Toews, D., Martin, S., and Meek, A. (1986). Dairy calf management, morbidity and mortality in Ontario Holstein herds. III. Association of management with morbidity. Preventive Veterinary Medicine 4, 137-158.

Virtala, AM., Mechor, GD., Grohn, YY., Erb, HN. (1996b). Morbidity from nonrespiratory disease and mortality in dairy heifers during the first three months of life. J, Am, Vet. Res 208,2043 –2046.

Virtala, AMK., Mechor, GD., Gröhn, YT. 1996. The Effect of CalfhooD Diseases on Growth of Female Dairy Calves During the First 3 Months of Life in New York State Journal of Dairy Science,79, 16, 1040-1049.

ACKNOWLEDGMENT

I would like to show my deepest gratitude to almighty God for bestowing blessings throughout the internship. I want to give my utmost regard to my supervisor Prof. Dr. Bibek Chandra Sutradhar, Department of medicine and surgery, CVASU for his suggestion, support, guidance & encouragement throughout the period of completion and my working place SAQTVH, CVASU, Chattogram. The author would like to thank respected supervisors, teachers, and mentors for supporting at the whole time.

Lastly, I am grateful to my friends and family for their support, good wishes and encouragement and love.

The author