

# TABLE OF CONTENTS

<b>Contents</b>	<b>Page no.</b>
<b>List of figures</b>	2
<b>Abstract</b>	3
<b>Chapter 1: Introduction</b>	4
<b>Chapter 2: Materials and Method</b>	
2.1 Case description	
2.2 Anesthesia and control	
2.3 Operation procedure	5-8
2.4 Post-operative care	
<b>Chapter 3: Results and Discussion</b>	9
<b>Chapter 4: Conclusion</b>	10
<b>References</b>	11
<b>Acknowledgement</b>	12

## List of figures

<b>Figure no.</b>	<b>Title</b>	<b>Page no.</b>
1	Shaved operation site.	7
2	Skin incision below umbilicus.	7
3	Exposing uterine horn along with ovary.	7
4	Separating ovary from broad ligament.	7
5	Ligating uterine body.	8
6	Separating uterine body.	8
7	Suturing muscle and peritoneum.	8
8	Incision closed by subcuticular suture.	8

## Abstract

---

A local breed female cat of 7 months age having body weight of 2.5Kg was brought to Shahedul Alam Quadary Teaching Veterinary Hospital (SAQTVH) of Chattogram Veterinary and Animal Sciences University (CVASU). The owner wanted to spay the cat to prevent reproduction and make the cat docile. The operation was performed under general anesthesia. Both ovaries along with the entire uterus were removed through a small incision in the midline of abdomen just below the umbilicus. Post-operative care was maintained properly. No post-operative complications were found during the follow-up period. The operation procedure was simple, quick and very effective for spaying in cat.

---

**Keywords:** Female cat, general anesthesia, spaying.

## Chapter 1: Introduction

Spaying is a perfect tool to control over population of dog and cat. It is recommended that all non-breeding cats should be sterilized. Any pet that has access to the outdoors need to be spayed or neutered to prevent any unwanted pregnancy. Spaying means sterilization of female animal by removing ovaries and uterus. Sometimes only their ovaries are removed. It's an irreversible technique (David, 2010; Kirsan et al., 2013). This is usually done by a small incision on her left hand side and can also be done underneath along her midline (Machado et al., 2012).

Spaying is done for the prevention of reproduction and making the animal docile. It is also done to protect them from certain diseases (Janssens and Janssens, 1991). Several health benefits are associated with spaying such as it eliminates the risk of ovarian and uterine cancers, it also reduces the risk of breast cancer in female cat. Unspayed cats also carry the risk of developing pyometra- a fatal condition of the uterus that require surgery to treat.

Spaying is the most common among elective surgeries (Pollari and Bonnett, 1996). Spaying of cat is recommended before they reach sexual maturity and are able to have kittens themselves. This is normally around the age of four to six months old. The surgery for spaying is performed under general anesthesia. The operation is performed through a relatively small incision made most commonly in the midline of the abdomen, just below the umbilicus. Both ovaries are removed along with the entire uterus. The surgical incision will be closed with several layer of sutures. In many cases skin suture will be placed and these will be removed after seven to ten days.

The objective of this study was to perform and evaluate the surgical technique of spaying in cat.

## Chapter 2: Materials and Method

### 2.1 Case description:

A local breed female cat of 7 months age having body weight of 2.5Kg was brought to Shahedul Alam Quadary Teaching Veterinary Hospital (SAQTVH) of Chattogram Veterinary and Animal Sciences University (CVASU). The owner wanted to spay the cat to prevent reproduction and make the cat docile. General physical examination of the cat revealed that the cat was in normal physical condition to perform the surgical procedure.

### 2.2 Anesthesia and control:

The cat was sedated with xylazine (1mg/Kg body weight) to make her calm. The surgical site was properly clipped and shaved and prepared aseptically for operative procedure.

Fluid therapy was ensured by intravenous normal saline. Ketamine hydrochloride (10mg/Kg body weight) was administered intravenously for general anesthesia.

### 2.3 Operation procedure:

A 1cm midline incision was made behind the umbilicus. Skin, subcutaneous tissue, muscle and peritoneum were incised to open abdominal cavity. After opening the abdominal cavity surgeon's index finger was introduced toward the left flank against the abdominal wall to hold and pull the uterine horn through the incision. After pulling out the uterine horn along with the ovary the suspensory ligament of the ovary was separated by manual traction with finger. Ovarian blood vessels within the broad ligament were exposed. Double ligation with chromic catgut was used to ligate the ovarian pedicle. The attachment between the ovary and ligature was separated. The other ovary was also removed by the similar manner.

The body of the uterus withdrawn from the abdominal cavity was ligated with chromic catgut and removed. The uterine stump was checked cautiously to prevent hemorrhage.

Peritoneum and muscle were sutured by simple continuous suture pattern using catgut. Subcuticular suture was done using catgut. Skin suture was not given. Antiseptic cream was applied on the incision site.

**2.4 Post-operative care:**

Antiseptic cream (Oint. Viodin®) was applied daily on the incision site. Antibiotic ceftriaxone (20mg/Kg body weight) and antihistaminic pheniramine maleate (0.5mg/Kg body weight) was administered intramuscularly for 5 days. Analgesic meloxicam (0.2mg/Kg body weight) was administered subcutaneously for 3 days. The animal was suggested to keep under observation for 7 days in clean squeeze cage.

## Figures

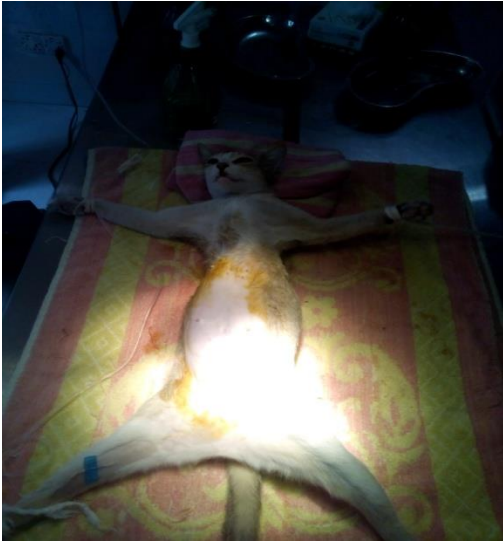

Figure 1: Shaved operation site.

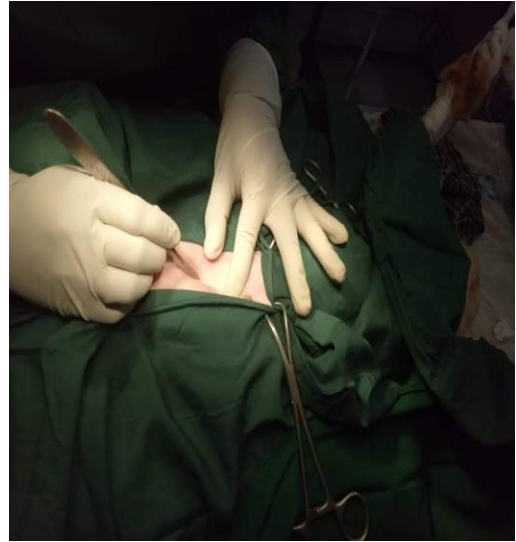


Figure 2: Skin incision below umbilicus

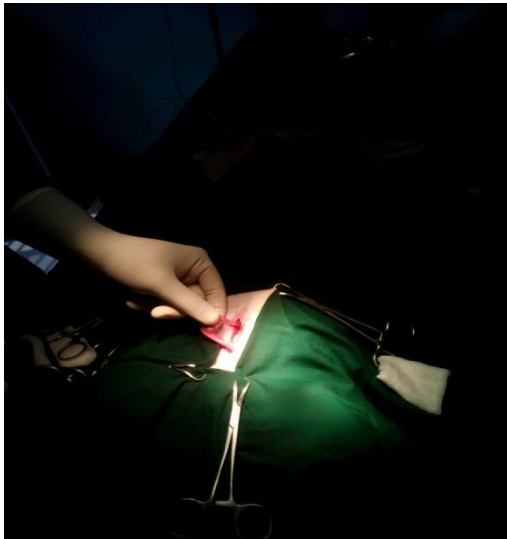


Figure 3: Exposing uterine horn along with ovary.

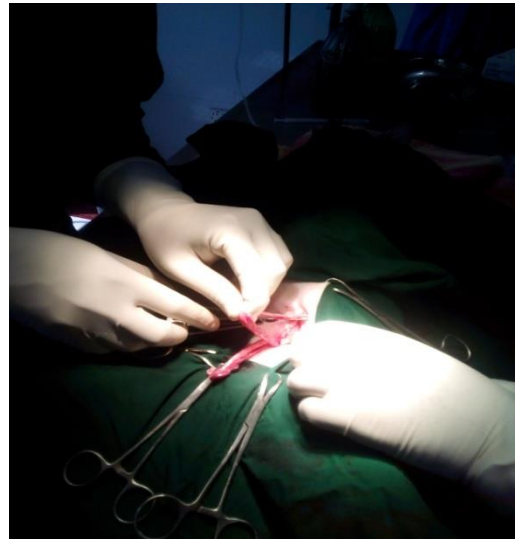


Figure 4: Separating ovary from broad ligament.

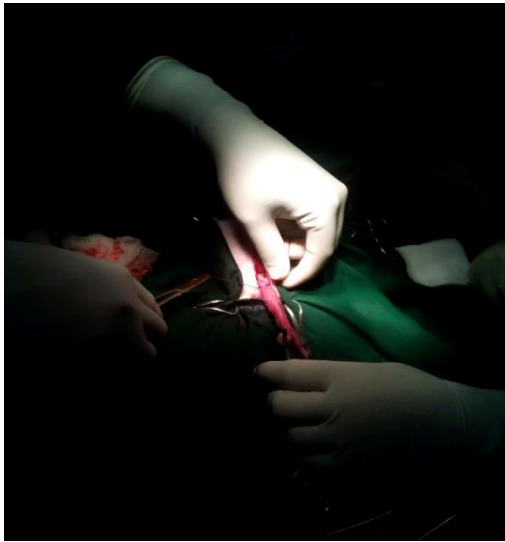


Figure 5: Ligating uterine body

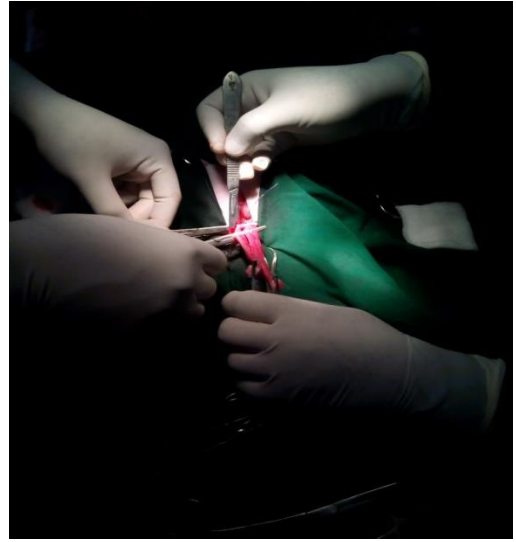


Figure 6: Separating uterine body.

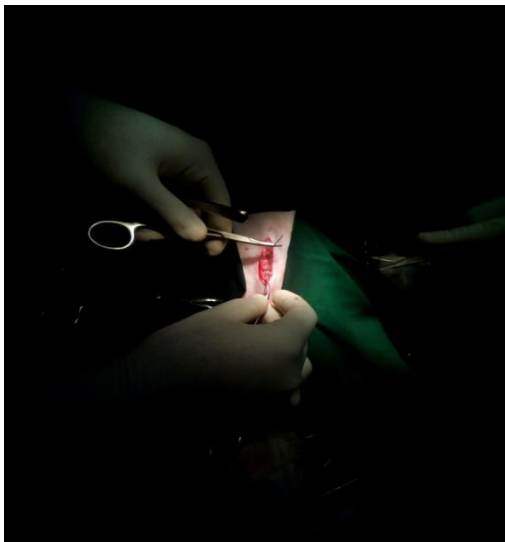

Figure 7: Suturing muscle and peritoneum

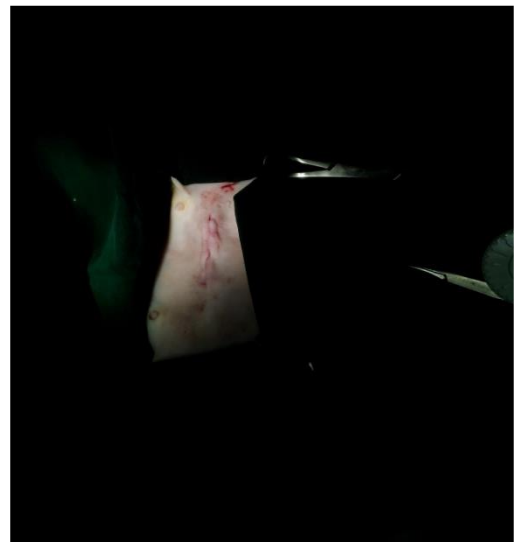

Figure 8: Incision closed by subcuticular suture.



## Chapter 3: Results and Discussion

Complete removal of uterus and both ovaries without any complication made the operation successful. No post-operative complication was found as post-operative care was maintained properly. The incision site healed perfectly.

The surgical procedure described in this study was performed to prevent unwanted reproduction and make the animal docile. Previous study also mentioned the effectiveness of spaying as a tool of preventing reproduction and making the animal docile (Janssens and Janssens, 1991). The other benefits of spaying are that it helps to protect the animal from uterine infection, uterine cancer and other cancers of the reproductive system.

Spaying is performed under general anesthesia. The abdomen is clipped, shaved and surgically scrubbed. Usually small incision is made along midline where there are fewer blood vessels in case of dog and cat (Jason, 2009). In this study the operation was performed following the similar manner. General surgical pack was used to locate the uterus and uterine horns. The blood vessels were tied off and the uterus and ovaries were completely removed. The inner body wall was sutured with absorbable suture material and then the outside skin layer was closed.

In some other studies postoperative complications of spaying were found in cat and dog (Pollari and Bonnett, 1996 and Pearson, 1973). However, in this study, no complications and no extra bleeding were found.

It was a successful operation which was similar with the operation discussed in other studies (Janssens and Janssens, 1991; Azizunnesa et al., 2017).

## **Chapter 4: Conclusion**

The surgical procedure of spaying a cat is an effective method to control cat population. It is a quick, practicable, field applicable, and reliable method for spaying in cat. In this study proper maintaining of general anesthesia and post-operative care made the operation successful without any complications. This surgical technique of spaying could be recommended for the field condition to reduce aggressiveness and to prevent reproduction in cat.

## References

- Azizunnesa, Hossain D, Chaudhary P, Parvez MA, Paul P, Yadav SK, Hasan T(2017). Spaying as a tool for birth control: A case report. *Res. J. Vet. Pract.* 5(2): 19-24.
- David D. (2010). Spaying (Ovariohysterectomy) in dogs. [www.peteducation.com](http://www.peteducation.com).
- Janssens LAA, Janssens GHRR (1991). Bilateral flank ovariectomy in the dog-surgical technique and sequelae in 72 animals. *J. Small Anim. Pract.* 32: 249-252. <https://doi.org/10.1111/j.1748-5827.1991.tb00557>.
- Jason S (2009). Ovariohysterectomy in dogs and cats. [www.acvs.Org/AnimalOwners/Diplomate Director](http://www.acvs.Org/AnimalOwners/DiplomateDirector).
- Kirsan I, Enginler SO, Toydemir TSF, Erzenin OM, Sonmez K., Sennazl G (2013). Gynaecological complications following improper ovariohysterectomy in a dog. *Int. J. Vet. Sci.* 2 (4):121-124.
- Machado SMA, Toniolloll K. G. H., Freitas C. C. D., Veloso B. C. Q. M. (2012). Pure-transvaginal natural orifice transluminal endoscopic surgery (NOTES) ovariohysterectomy in bitches: a preliminary feasibility study. *Ciência Rural.* 42(7): 1237-1242. <https://doi.org/10.1590/S0103-84782012005000050>
- Pollari FL, Bonnett BN (1996). Evaluation of postoperative complications following elective surgeries of dogs and cats at private practices using computer records. *Canadian Vet. J.* 37: 672-678.
- Pearson H(1973). The complications of ovariohysterectomy in the bitch. *J Small Anim Pract.* 14(5):257–266.

## Acknowledgements

All praises are due to the Almighty God, the creator and supreme authority of the universe, have been enabled the author to accomplish this work.

The author would like to express his deep sense of gratitude and thanks to his supervisor **Professor Dr. A.S.M Lutful Ahasan** , Department of Anatomy and Histology, Chattogram Veterinary and Animal Sciences University, whose encouragement and support helped for the completion of the report.

The author wishes to acknowledgement to **Professor Dr. Abdul Ahad**, Dean, Faculty of Veterinary Medicine, **Professor Dr. A. K. M. Saifuddin**, Director of External affairs, Chattogram Veterinary and Animal Sciences University.

The author also grateful to **Assistant Professor Dr. Tuli Dey**, Department of Medicine and Surgery, Faculty of Veterinary Medicine, Chattogram Veterinary and Animal Sciences University for giving me opportunity to work during internship working period.

The Author.